

Outcome of Scalpel and Electrocautery in Abdominoplasty and Seroma Formation- A Comparative Study

Hemant Goyal¹, Ruchika Agarwal², Ram Avtar³

¹Assistant Professor, Department of Surgery, F.H. Medical College and Hospital, Near Railway Over Bridge, Etmadpur, Agra, India, ²Assistant Professor, Department of Obstetrics and Gynaecology, F.H. Medical College and Hospital, Near Railway Over Bridge, Etmadpur, Agra, India, ³Associate Professor, Department of Surgery, F.H. Medical College and Hospital, Near Railway Over Bridge, Etmadpur, Agra, India.

Abstract

Background: The abdominoplasty is one of the most commonly performed aesthetic surgical procedures. The present study was conducted to compare scalpel and electrocautery in abdominoplasty and its complications. **Subjects and Methods:** The present study was conducted on 62 patients of both genders underwent abdominoplasty. Patients were divided into 2 groups of 31 each. Group I comprised of patients in which dissection with scalpel was done and group II patients underwent abdominoplasty with electrocautery forceps. In both groups, seroma formation was recorded. **Results:** Males were 30 and females were 32. Seroma was seen in 6 in group I and 4 in group II. Drain output was 120.2 milliliters in group I and 82.6 milliliters in group II. The difference was significant ($P < 0.05$). **Conclusion:** Authors found both techniques effective in abdominoplasty. Seroma was most common complication seen in both techniques.

Keywords: Abdominoplasty, Electrocautery, Seroma.

Corresponding Author: Dr. Ram Avtar, Associate Professor, Department of Surgery, F.H. Medical College and Hospital, Near Railway Over Bridge, Etmadpur, Agra, India.

Received: July 2019

Accepted: July 2019

Introduction

The abdominoplasty is one of the most commonly performed aesthetic surgical procedures across the world.^[1] It is estimated that more than 800,000 people undergo this operation each year, making it the sixth most common cosmetic procedure. The main objective of an abdominoplasty is to reshape the body contour by means of excising redundant skin and fat tissue to remodel the abdominal wall.^[2]

The contemporary techniques that have subsequently been described share 3 characteristics: limited dissection of the abdominal flap, plication of the rectus abdominis fascia, and resection of a segment of skin and underlying subdermal tissue down to the scarpa fascia. Despite the popularity of abdominoplasty, patients are at significant risk of developing a complication from the procedure, the most common of which is seroma formation which occurs in around 5- 30% of patients.^[3]

The possibility of a higher incidence of seroma in lipoabdominoplasties than in abdominoplasties without liposuction remains controversial. Najera et al.^[4] published a series of 200 patients, showing that the seroma rates in the abdominoplasty and lipoabdominoplasty groups were 16% and 31.2%, respectively. Seroma formation remains a significant problem in abdominoplasty surgery, the cause of which is likely to be multifactorial. Elevation of a large flap

of abdominal tissue leaving two raw tissue surfaces either side of a potential space, disruption of the lymphatic drainage, hematoma formation and instruments used for tissue dissection have all been proposed as potential causes for seroma formation. Worldwide, dissection methods vary greatly between surgeons and in the UK the handheld electrocautery or 'Bovey' is gaining popularity whereas more senior surgeons. The present study was conducted to compare scalpel and electrocautery in abdominoplasty and its complications.

Subjects and Methods

The present study was conducted in the department of general surgery. It comprised of 62 patients of both genders underwent abdominoplasty. All were informed regarding the study and written consent was obtained. Ethical approval was taken prior to the study.

General information such as name, age, gender etc. was recorded. Patients were divided into 2 groups of 31 each. Group I comprise of patients in which dissection with scalpel was done and group II patients underwent abdominoplasty with electrocautery forceps.

In both groups the surgical technique was identical apart from the method of abdominal flap dissection. All surgery was carried out under general anaesthesia with patients marked pre operatively in a standing position. The lower incision was placed in the lowest skin crease above the pubic

hairline and continued through onto the superficial fascia of the anterior rectus sheath.

In both groups, seroma formation was recorded. The seroma formation was defined as a fluid collection detected by palpation on clinical examination when patients attend for routine follow up clinic appointments. Results were tabulated and subjected to statistical analysis. P value less than 0.05 was considered significant.

Result

Table 1: Distribution of patients

	Group I	Group II
Methods	Scalpel	Electrocautery
Number	31	31

[Table 1] shows that group I comprise of patients in which dissection with scalpel was done and group II patients underwent abdominoplasty with electrocautery forceps. Both groups had 31 patients each.

Table 2: Gender wise distribution of patients

Gender	Males	Females
Number	30	32

[Table 2] shows that males were 30 and females were 32.

Table 3: Primary outcome of treatment

Primary outcome	Group I	Group II	P value
Seroma	6	4	0.01
Drain output (mls)	120.2	82.6	0.001

[Table 3] shows that seroma was seen in 6 in group I and 4 in group II. Drain output was 120.2 milliliters in group I and 82.6 milliliters in group II. The difference was significant (P< 0.05).

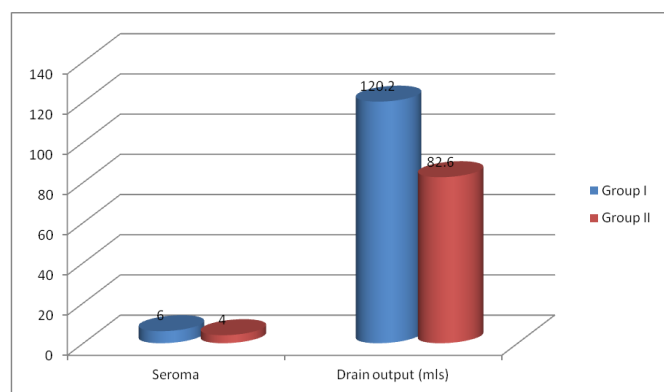


Figure 1: Primary outcome of treatment

Discussion

The appropriate patient for standard abdominoplasty has excessive, loose, sagging, abdominal skin, lax abdominal fascial wall and/or diastasis recti. Typically there is pronounced skin laxity; more than 6–8 cm of skin needs to be excised in the vertical dimension. Extensive undermining is necessary to provide exposure to a lax abdominal wall and

to allow redraping of the skin. The muscular aponeurotic system, subcutaneous fat thickness, and skin are analyzed. Each system is addressed with the standard abdominoplasty.^[5]

Swanson surveyed 497 members of the American Society of Plastic Surgeons about their preferences regarding different abdominoplasty techniques and their most frequent complications.^[6] The analysis comprised 20,029 procedures, of which 55% were traditional abdominoplasties, 35% were lipoabdominoplasties, and 10% were limited abdominoplasties, also known as mini-abdominoplasties. The local complication rates were 20%, 10.3%, and 13.5%, respectively. The systemic complication rate was less than 0.1% for all techniques. The present study was conducted to compare scalpel and electrocautery in abdominoplasty and its complications.

In present study, group I comprise of patients in which dissection with scalpel was done and group II patients underwent abdominoplasty with electrocautery forceps. Both groups had 31 patients each. Males were 30 and females were 32. Marsh et al.^[7] published a prospective randomized study comparing scalpel and handheld electrocautery dissection, finding no difference in the seroma rate between the 2 groups.

We found that seroma was seen in 6 in group I and 4 in group II. Drain output was 120.2 milliliters in group I and 82.6 milliliters in group II. Pollock and Pollock published their ex-perience with 597 patients,^[8] in whom progressive tension sutures were used for this purpose, reporting only 1 case of seroma in 12 years (Level of Evidence: Therapeutic, IV). In a similar manner, fibrin glue has also been proposed for collapsing the space below the abdominal flap.

Hensel et al,^[9] conducted a study in which primary outcome measure such as postoperative seroma formation on clinical examination, secondary outcome measures are drain volume, weight of tissue removed, effect of liposuction and patient BMI was calculated. Both study groups were similar in demographics with no significant difference in weight of tissue excised, BMI, drain output or post operative complications. There was no significant difference in seroma formation rates between the handheld electrocautery group (17.2%) and the sharp dissection group (20.1%). Overall, the seroma rate was 18.6%. Liposuction to the flanks at the time of abdominoplasty was found to significantly increase the incidence of seroma, compared to patients having abdominoplasty alone.

Rousseau et al.^[10] retrospectively analysed 647 abdominoplasty patients which suggested that cutting diathermocoagulation use leads to an increased risk of non infective post operative fluid collection when compared to sharp dissection (8.8% v 4.9%). Yilmaz et al,^[11] looked at seroma formation post mastectomy and suggest electrocautery use may lead to an increase in seroma formation although numbers are small and seroma rates high in both knife and electrocautery group (37% and 53.8% respectively). Others have found that in thyroidectomy patients use of electrocautery or scalpel for flap dissection does not significantly affect seroma formation whereas Porter et al,^[12] suggested electrocautery leads to an increase in seroma formation post mastectomy although the results were only significant at the 90% confidence interval. It may

be from these studies on electrocautery use in mastectomy patients that the idea electrocautery causes seroma in abdominoplasty surgery may have come yet clearly a mastectomy is a very different procedure to an abdominoplasty.

Conclusion

Authors found both techniques effective in abdominoplasty. Seroma was most common complication seen in both techniques.

References

1. Baroudi R, Ferreira CA. Seroma: how to avoid it and how to treat it. *Aesthet Surg J* 1998;18:439-41.
2. Grazer FM. Abdominoplasty. *PlastReconstrSurg* 1973;51: 617-23.
3. Ousterhout DK. Combined suction-assisted lipectomy, surgical lipectomy, and surgical abdominoplasty. *Ann PlastSurg* 1990;24:126-32.
4. Najera RM, Asheld W, Sayeed SM, et al. Comparison of se-romaformation following abdominoplasty with or without liposuction. *Plast ReconstrSurg* 2011;127:417-22.
5. Rogliani M, Silvi E, Labardi L, et al. Obese and nonobese patients: complications of abdominoplasty. *Ann PlastSurg* 2006;57:336-8.
6. Swanson E. Prospective outcome study of 360 patients treated with liposuction, lipoabdominoplasty, and abdominoplasty. *PlastReconstrSurg* 2012;129:965-78.
7. Marsh DJ, Fox A, Grobbelaar AO, et al. Abdominoplasty and seroma: a prospective randomised study comparing scalpel and handheld electrocautery dissection. *J PlastReconstrAesthetSurg* 2015;68:192-6.
8. Pollock TA, Pollock H. Progressive tension sutures in abdominoplasty: a review of 597 consecutive cases. *AesthetSurg J* 2012;32:729-42.
9. Hensel JM, Lehman JA Jr, Tantri MP, et al. An outcomes analysis and satisfaction survey of 199 consecutive abdominoplasties. *Ann PlastSurg* 2001;46:357-63.
10. Rousseau P, Vincent H, Potier B, Arnaud D, Darsonval V. Diathermocoagulation in cutting mode and large flap dissection. *PlastReconstrSurg* 2011; 127(5):2093-8.
11. Yilmaz KB, Dogan L, Nalbant H, et al. Comparing scalpel, electrocautery and ultrasonic dissector effects: the impact on wound complications and pro-inflammatory cytokine levels in wound fluid from mastectomy patients. *J Breast Cancer* 2011;14(1):58-63.
12. Porter KA, O'Connor S, Rimm E, Lopez M. Electrocautery as a factor in seroma formation following mastectomy. *Am J Surg* 1998; 176(1):8- 11.

Copyright: © the author(s), 2019. It is an open-access article distributed under the terms of the Creative Commons Attribution License (CC BY 4.0), which permits authors to retain ownership of the copyright for their content, and allow anyone to download, reuse, reprint, modify, distribute and/or copy the content as long as the original authors and source are cited.

How to cite this article: Goyal H, Agarwal R, Avtar R. Outcome of Scalpel and Electrocautery in Abdominoplasty and Seroma Formation- A Comparative Study. *Acad. J Surg.* 2019;2(2):1-6.

DOI: [dx.doi.org/10.21276/ajs.2019.2.2.1](https://doi.org/10.21276/ajs.2019.2.2.1)

Source of Support: Nil, **Conflict of Interest:** None declared.