

# Evaluation on Different Treatment Methods of Pilonidal disease: A Teaching Hospital Based Study

D. Krishna Chaitanya<sup>1</sup>

<sup>1</sup>Associate Professor, Department of Surgery, Nimra Institute of Medical Sciences, Nimra Nagar, Ibrahimpatnam, Jupudi, Vijayawada, Andhra Pradesh-521456.

## Abstract

**Background:** Pilonidal disease is a common chronic disease of the sacrococcygeal region. The cause of pilonidal sinus remains controversial. It occurs more often in overweight people, persons with abundant body hair and occurs more often in men than in women. **Subjects and Methods:** The study was conducted in the department of general surgery, Nimra Institute of Medical sciences (NIMS), Vijayawada, on 100 patients who were admitted with pain and swelling over the sacro coccygeal region, who were selected for surgical excision. The follow up of these patients were over a period of 4yrs. **Results:** The Results were amazingly good as expected with wide excision of the pilonidal sinus without immediate closure of the wound. Some patients were subjected for secondary suturing, some patients were not sutured at all, the wound was left open to heal on its own. But the results are equal in both the conditions unlike in primary closure where the recurrence is more. **Conclusion:** In apparently large, inflamed and recurrent situations, we should prefer the Open Excision, where the healing time is longer but the percentage of success is greater.

**Keywords:** Pilonidal sinus, primary suturing, secondary or delayed suturing and Recurrence rate.

**Corresponding Author:** Dr. D. Krishna Chaitanya, Associate Professor, Department of Surgery, Nimra Institute of Medical Sciences, Nimra Nagar, Ibrahimpatnam, Jupudi, Vijayawada, Andhra Pradesh-521456.

Received: May 2019

Accepted: June 2019

## Introduction

The term pilonidal is derived from the Latin word Pilus (hair) and Nidus (nest) and this term was coined and described by Hodges in 1880. It is diagnosed by the finding of a characteristic epithelial tract (the sinus) located in the natal cleft, a short distance behind the anal verge and generally containing hair.<sup>[1]</sup> Pilonidal disease is a common chronic disease of the sacrococcygeal region. The cause of pilonidal sinus remains controversial. It occurs more often in overweight people, persons with abundant body hair and occurs more often in men than in women.<sup>[2,3]</sup> Numerous kinds of surgical procedures were described for treating pilonidal disease and abscess, i.e. drainage and curettage,<sup>[4]</sup> cryosurgery,<sup>[5]</sup> Z-plasty procedure,<sup>[6,7]</sup> lancing under local anesthesia, vacuum assisted closure,<sup>[8]</sup> excision with secondary healing, excision with primary closure local flap surgery and Bascom procedure,<sup>[9-15]</sup> have been described by various authors. Pilonidal disease can appear as an acute abscess along with sinus tract formation. A more complex manifestation can be characterized by chronic or recurrent abscesses with extensive, branching sinus tracts.<sup>[16]</sup> The common form is an acute abscess characterized by the existence of a midline pit in the natal cleft typically identified 4 to 8 cm from the anus. The skin enters the sinus giving the opening a smooth edge. This primary tract leads into a subcutaneous cavity, which contains granulation tissue

and usually a nest of hairs that are present in two thirds of cases in men and in one third of those in women and may be seen projecting from the skin opening. Many patients have secondary lateral openings 2 to 5 cm above the midline pit. The skin opening and the superficial portion of the tract are lined with squamous cell epithelium, but the deep cavity and its extensions are not.

Today pilonidal sinuses are widely accepted to be acquired abnormalities as a result of the drainage of a hair follicle that ruptured in the subcutaneous fat,<sup>[17-20]</sup> producing acute or chronic inflammation resulting in an abscess or a tract.<sup>[19,21]</sup> The invasion of the follicle occurs through the expandable orifice of the vestigial scent gland and is a result of inflammation and rupture in the subcutaneous fat of the follicle.<sup>[22,23]</sup> Aim of the present study was to compare the different methods used by clinicians and to determine the outcomes in relation to healing, hospitalization time and recurrence rate.

## Subjects and Methods

This present study was conducted in the Department of Surgery, Nimra institute of medical sciences, Vijayawada during the period from 2015 to 2019. Out of 100 patients, 62 were males and 38 were females. Ages ranged from 16 to 45 years with an average age of about 30.5 years. We have studied all the cases of patients with Pilonidal sinus that were

treated surgically in NIMS, Vijayawada. In OPD, we practice the Open or Primary Suture Excision and marsupialization techniques. We studied following variables; Age, Sex, Method of treatment, Time of hospitalization, Time of healing and Recurrence rate.

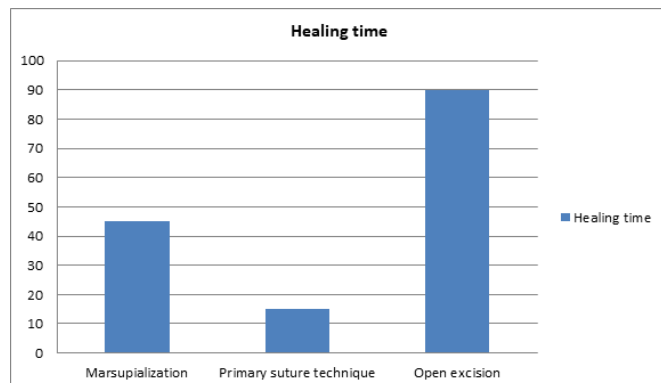
### Results & Discussion

Among these 100 patients, 62 (62%) were males and 38 (38%) were females. Ages ranged from 16 to 45 years with an average age of about 30.5 years. In OPD, we practice the Open or Primary Suture Excision and marsupialization techniques. There was no inflammation in any of the 100 treated patients. If there was prior inflammation, it was treated first with incision and drainage followed by administration of medication, including antibiotics and non-steroid anti-inflammatory drugs. Of the 100 patients, 55 were treated with marsupialization and the remaining 45 were treated by excision (in 27 of them open excision was preferred, while the remaining 18 received the primary suture technique). From the total number of patients, 92 (92%) were discharged from the hospital after the surgical procedure, while in the remaining 8 cases, hospitalization for 24 hours was deemed necessary. The results are depicted in the table below for better understanding [Table-1].

**Table 1: Depicting the analysis of results**

Sr. no.	Variables	Primary suturing n=50 Cases	Secondary suturing N=50 Cases
1.	Male	30	32
2.	Female	20	18
3.	Average age in yrs	16-45	18-45
4.	Recurrence rate	29 (58%)	1 (2%)
5.	Average duration	Immediate suturing	45 days

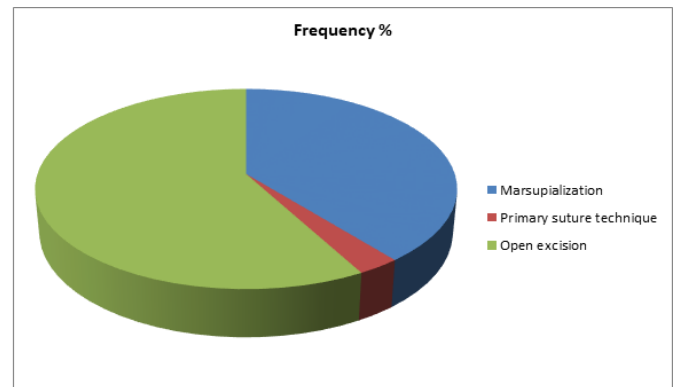
The time of healing of the patients that were subjected to marsupialization peaked at 45 days (average 25.2), in contrast to the patients subjected to the primary suture technique, which peaked at 15 days (average 12.4). The patients that were subjected to the open excision method had a healing time that peaked at 90 days (average 44.2) [Figure 1].



**Figure 1: Healing time of the surgical techniques.**

Recurrence of sinus disease) was observed in 30 patients (30%). 17 (30.9%) of the 55 patients subjected to marsupialization experienced recurrence. Of the 27 patients

subjected to open incision, there was only 1 (3.7%) recurrence, while 12 (63.1%) of the 18 patients subjected to primary closure experienced recurrence [Figure 2].



**Figure 2: Pie chart shows the Recurrence rate of the surgical techniques**

The pilonidal disease is not a very common problem but it needs a proper evaluation and deep thinking regarding the management aspects. My experience and techniques mainly focused to decrease the recurrence rate of the disease by following the best techniques. We did a comparative study in 100 patients of which half of the patients were subjected for primary suturing of the wound and sent the patient immediately to home with oral antibiotics and analgesics. Rest of the patients were subjected for delayed suturing of the wound, with regular dressings, oral antibiotics and some patients were sutured after 4wks, some patients took very long time almost 3 months. Some wounds were left open to heal on its own. Pilonidal disease affects men between 16-25 years of age most often.<sup>[24]</sup> Usually it is associated with obese and hirsute individuals who experience profuse sweating and have a sedentary lifestyle.<sup>[25,26]</sup> The treatment of pilonidal disease is mostly surgical. The most commonly used procedures today are: simple incision, excision, plastic surgery techniques, marsupialization and fistulotomy. Simple incision implies a midline incision through the mouths of the pits and is effective in those cases of so-called raphe cannulization where infection spreads from pit to pit.<sup>[27]</sup> After unroofing the tract it is cleaned and drained. The final cure is done after the end of inflammation.<sup>[28]</sup> This is usually reserved for acute infective swelling. Recurrence is frequent and is mostly used in acute situations where relief of pain is urgent. Excision is used for chronic and recurrent pilonidal sinuses. Excision of all involved skin and subcutaneous tissue may be necessary for definitive treatment. These wounds may then be managed openly, with healing by secondary intention, allowing the wound to granulate, or is closed by primary suture.<sup>[29]</sup> Laying the sinus open permits adequate drainage. The healing requires more time, but has lower recurrence.<sup>[30]</sup> In the primary suture the pilonidal sinus is excised and the wound sutured by using deep tension sutures tied over a gauze dressing. The advantages are quicker healing and an early return to work, albeit with higher recurrence when compared to the open technique.<sup>[31]</sup> Plastic surgery techniques that include these procedures do not only cover the wound but also, in theory, fatten the natal cleft, reduce hair accumulation, mechanical irritation and risk

of recurrence.<sup>[32]</sup> Various kinds of flaps have been used: 1-2 skin flaps, fasciocutaneous flaps like the V-Y flap (for recurrent and complicated sinus disease) and rhomboid excision and the Limberg flap.<sup>[33]</sup> Moreover, the Karydakis flap achieves asymmetric closure of the pilonidal wounds by avoiding to place the wound in the midline at the depth of the natal cleft and also flattens the cleft reducing hair accumulation and mechanical irritation in order to decrease recurrence.<sup>[34]</sup> Marsupialization involves milossis and opening up of the cavity.<sup>[35]</sup> After excision of the sinus front and lateral tracts the cavity is scrubbed to remove hair and granulation tissue. Then, the skin flaps are sutured to the presacral fascia and the wound healing is done by secondary intention.<sup>[36]</sup> It is vital to have a strong front tract in order to succeed. Fistulotomy involves milossis of the cavernous resource, opening up, removal of hair and scrubbing of granulation tissue and healing by secondary intention.<sup>[37]</sup> For my cases, we used incision and drainage of the abscessed bladders followed by excision (Open or with Primary Closure) and marsupialization.<sup>[37]</sup> Clear criteria for selecting the treatment method do not exist. Nevertheless, it is emphasized that Primary Closure should be used in small, uncomplicated bladders and the open excision in larger bladders. After incision and drainage of the bladder has been performed, and after inflammation has subsided, a permanent treatment can be applied. Based on my 100 observed surgical cases, marsupialization is the surgical method of choice as it had a low percentage of recurrence and an acceptably short healing period. It should be noted that selecting marsupialization as a treatment method presupposes the absence of inflammation and that the case is not a recurrence.<sup>[38]</sup> In apparently large, inflamed and recurrent situations, we should prefer the Open Excision, where the healing time is longer but the percentage of success is greater. We observed the patients almost 4yrs.some patients were reluctant or forgot to com for follow up; we personally telephoned them to visit the surgical OPD. We were surprised to see around 5 young girls affected with this disease, we treated them with secondary suturing without any possible recurrence over a period of years.

## Conclusion

These findings suggest that the absence of inflammation and/or recurrence, marsupialization is the surgical method of choice as it has a low percentage of recurrence and an acceptably short healing period. In apparently large, inflamed and recurrent situations, open excision is preferred. Based on our observed surgical cases, marsupialization is the surgical method of choice as it had a low percentage of recurrence and an acceptably short healing period. It should be noted that selecting marsupialization as a treatment method presupposes the absence of inflammation and that the case is not a recurrence. In apparently large, inflamed and recurrent situations, we should prefer the Open Excision, where the healing time is longer but the percentage of success is greater.

## References

1. Total recovery time and hospital stay was significantly more in open technique group than in Z-plasty group.
2. Chintapatla S, Safarani N, Kumar S, Haboubi N. Sacrococcygeal pilonidal sinus: historical review, pathological insight and surgical options. *Tech Coloproctol* 2003;7(1):3e8.
3. Isbister WH, Prasad J. Pilonidal disease. *Aust N Z J Surg* 1995;65(8):561e3.
4. Vahedian J, Nabavizadeh F, Nakhaee N, Vahedian M, Sadeghpour A. Comparison between drainage and curettage in the treatment of acute pilonidal abscess. *Saudi Med J* 2005;26(4):553e5.
5. Gage AA, Dutta P. Cryosurgery for pilonidal disease. *Am J Surg* 1977;133(2):249e54.
6. Toubanakis G. Treatment of pilonidal sinus disease with the Z-plasty procedure (modified). *Am Surg* 1986;52(11):611e2.
7. Mansoori A, Dickson D. Z-plasty for treatment of disease of the pilonidal sinus. *Surg Gynecol Obstet* 1982;155(3): 409e11.
8. McGuinness JG, Winter DC, O'Connell PR. Vacuum-assisted closure of a complex pilonidal sinus. *Dis Colon Rectum* 2003;46:274-6.
9. Obeid SA. A new technique for treatment of pilonidal sinus. *Dis Colon Rectum* 1988;31:879-85.
10. Tritapepe R, Di Padova C. Excision and primary closure of pilonidal sinus using a drain for antiseptic wound flushing. *Am J Surg* 2002;183:20911.
11. Topgül K, Ozdemir E, Kiliç K, Gökbayır H, Ferahköse Z. Longterm results of limberg flap procedure for treatment of pilonidal sinus: A report of 200 cases. *Dis Colon Rectum* 2003;46:1545-8.
12. Bozkurt MK, Tezel E. Management of pilonidal sinus with the Limberg flap. *Dis Colon Rectum* 1998;41:775-7.
13. Mosquera DA, Quayle JB. Bascom's operation for pilonidal sinus. *J R Soc Med* 1995;88:45P-6P.
14. Eryilmaz R, Sahin M, Alimoglu O, Dasiran F. Surgical treatment of sacrococcygeal pilonidal sinus with the Limberg transposition flap. *Surgery* 2003;134:745-9.
15. Senapati A, Cripps NP, Thompson MR. Bascom's operation in the day-surgical management of symptomatic pilonidal sinus. *Br J Surg* 2000;87:1067-70.
16. Bendewald FP, Cima RR. Pilonidal disease. *Clin Colon Rectal Surg.* 2007;20(2):86-95.
17. King ES. The nature of the pilonidal sinus. *Aust N Z J Surg.* 1947;16(3):182-92.
18. Patey DH. A reappraisal of the acquired theory of sacrococcygeal pilonidal sinus and an assessment of its influence on surgical practice. *Br J Surg.* 1969;56(6):463-6.
19. Patey DH, Scarff RW. Pathology of postanal pilonidal sinus; its bearing on treatment. *Lancet.* 1946;2(6423):484-6.
20. Bascom J. Pilonidal disease: origin from follicles of hairs and results of follicle removal as treatment. *Surgery.* 1980;87(5):567-72.
21. Surrell JA. Pilonidal disease. *Surg Clin North Am.* 1994;74(6):1309-15.
22. Bascom J. Pilonidal disease: long-term results of follicle removal. *Dis Colon Rectum.* 1983;26(12):800-7.
23. Bascom J, Bascom T. Failed pilonidal surgery: new paradigm and new operation leading to cures. *Arch Surg.* 2002;137(10):1146-51.
24. Karydakis GE. New approach to the problem of pilonidal sinus. *Lancet.* 1973;2(7843):1414-5.
25. Bascom J. Surgical treatment of pilonidal disease. *BMJ.* 2008;336(7649):842-3.
26. Louis A. Buie. Classic articles in colonic and rectal surgery. 1890-1975: Jeep disease (pilonidal disease of mechanized warfare). *Dis Colon Rectum.* 1982;25(4):384-90.
27. Bascom J, Bascom T. Failed pilonidal surgery: new paradigm and new operation leading to cures. *Arch Surg.* 2002;137(10):1146-51.
28. Bascom J, Bascom T. Utility of the cleft lift procedure in refractory pilonidal disease. *Am J Surg.* 2007;193(5):606-9.
29. Armstrong JH, Barcia PJ. Pilonidal sinus disease. The conservative approach. *Arch Surg.* 1994;129(9):914-9.
30. Miocinovic M, Horzic M, Bunoza D. The treatment of pilonidal disease of the sacrococcygeal region by the method of limited excision and open wound healing. *Acta Med Croatica.* 2000;54(1):27-31.
31. Jones DJ. ABC of colorectal diseases. Pilonidal sinus. *BMJ.* 1992;305(6850):410-2.
32. Sondenaa K, Andersen E, Nesvik I, Soreide JA. Patient characteristics and symptoms in chronic pilonidal sinus disease. *Int J Colorectal Dis.* 1995;10(1):39-42.
33. Chintapatla S, Safarani N, Kumar S, Haboubi N. Sacrococcygeal pilonidal sinus: historical review, pathological insight and surgical options. *Tech Coloproctol.* 2003;7(1):3-8.

34. Karydakis GE. Easy and successful treatment of pilonidal sinus after explanation of its causative process. *Aust N Z J Surg.* 1992;62(5):385-9.
35. Solla JA, Rothenberger DA. Chronic pilonidal disease. An assessment of 150 cases. *Dis Colon Rectum.* 1990;33(9):758-61.
36. Bascom JU. Repeat pilonidal operations. *Am J Surg.* 1987;154(1):11822.
37. Kitchen PR. Pilonidal sinus: experience with the Karydakis flap. *Br J Surg.* 1996;83(10):1452-5.
38. Akca T, Colak T, Ustunsoy B, Kanik A, Aydin S. Randomized clinical trial comparing primary closure with the Limberg flap in the treatment of primary sacrococcygeal pilonidal disease. *Br J Surg.* 2005;92(9):1081-4.

**Copyright:** © the author(s), 2019. It is an open-access article distributed under the terms of the Creative Commons Attribution License (CC BY 4.0), which permits authors to retain ownership of the copyright for their content, and allow anyone to download, reuse, reprint, modify, distribute and/or copy the content as long as the original authors and source are cited.

**How to cite this article:** Chaitanya DK. Evaluation on Different Treatment Methods of Pilonidal disease: A Teaching Hospital Based Study. *Acad. J Surg.* 2019;2(1):16-19.

DOI: [dx.doi.org/10.21276/ajs.2019.2.1.6](https://doi.org/10.21276/ajs.2019.2.1.6)

**Source of Support:** Nil, **Conflict of Interest:** None declared.