

# Various Modalities of Scalp Reconstruction: A Review of Literature and Case Series

Ali Adil Mahmud<sup>1</sup>, Fahud Khurram<sup>2</sup>, Amar D N<sup>3</sup>, Aravind Naik<sup>4</sup>

<sup>1</sup>Assistant Professor, Plastic Surgery, Srinivas Institute of Medical Sciences and Research centre Mangalore, <sup>2</sup>Assistant Professor, Plastic Surgery, plastic surgery JNMCH, AMU Aligarh, <sup>3</sup>Associate Professor, General surgery, Srinivas Institute of Medical Sciences and Research centre Mangalore, <sup>4</sup>Assistant Professor, General Surgery, Srinivas Institute of Medical Sciences and Research centre Mangalore.

## Abstract

**Background:** The human scalp has various functions from protecting the skull bone to providing an aesthetic look. Various condition of the scalp that can cause full or partial thickness scalp loss are trauma (gunshot, RTA, avulsion injuries), acute and post burn injuries, post tumour excision defects and scalp infection etc. **Subjects and Methods:** This retrospective observational study was conducted over a period of 3 years in a tertiary care centre and the different etiologies of scalp injuries along with the various techniques of scalp reconstruction were discussed. **Results:** A total of 50 patients of both sexes and any age with full or partial thickness scalp defects were admitted. The most common age of presentation was 20-40 years age (40%) with trauma (56%) being the most common etiology followed by burns in 30% patients. 40 % of the patients were reconstructed with skin grafts while in 30% patients local flaps and in 10% patients tissue expanders were used. **Conclusion:** An aesthetically pleasing scalp reconstruction requires a precise preoperative planning with detailed knowledge of scalp anatomy and blood supply. The wide armamentarium of techniques for reconstruction allows the plastic surgeon to give a much pleasing final result.

**Keywords:** Scalp defect, scalp reconstruction.

**Corresponding Author:** Dr, Aravind Naik, Assistant Professor, General Surgery, Srinivas Institute of Medical Sciences and Research centre Mangalore.

Received: November 2018

Accepted: December 2018

## Introduction

The human scalp has tough skin that provides various functions from protecting the cranium to providing and aesthetic look. The scalp tissue being exposed is subjected to a lot of conditions causing full or partial thickness loss.

Various etiologies that are associated with scalp loss are trauma (RTA, gunshots, scalp avulsions, necrotizing infections, post burns, reconstruction post tumour excision, post traumatic alopecia.

The main criteria for scalp reconstruction are 1. Size of defect, 2. Its thickness 3.the aesthetic concerns of the patient, 4. surrounding tissue pliability, 5.the hair line and surrounding hair quality and density 6.presence of healthy pericranium and 7 comorbidities of the patient.<sup>[1]</sup>

Various treatment modalities have been described in literature from primary closure to microvascular free tissue transfer.<sup>[2]</sup>

History will always remember the pioneers in reconstructive plastic surgery like Robinson in 1908 who advocated the use of STSG (split thickness skin grafts) for intact pericranium.<sup>[3]</sup>

Ortichochia in 1967 for his four flap technique of scalp closure.<sup>[4]</sup> While Neuman introduced the concept of tissue expansion in 19575, it was in 1984, when Manders et al used tissue expansion for the first time to reconstruct a scalp defect with an expanded hair bearing flap<sup>6</sup>. Microvascular surgery has advanced by leaps and bounds and in 1976, Miller et al demonstrated the first successful scalp reimplantation,<sup>[7]</sup> while many authors have described greater omentum muscle (Latissimus Dorsi) and fasciocutaneous flaps (ALT, RAFF) for calvarial cover.<sup>[8-10]</sup>

We present a case series of 50 patients who presented to our institute with full or partial thickness scalp loss due to various etiologies and their management.

### Various modalities of scalp reconstruction

The human scalp can be divided into 5 layers depicted by the pneumatic SCALP [S (Skin), C (Subcutaneous tissue), A (Galea Aponeurotica), L (loose Areolar tissue), P (Pericranium)].<sup>[10]</sup> Reconstructive surgeons were primarily concerned with covering the exposed calvarium to prevent bone necrosis and dessication but today the demands to reconstruct a more cosmetically appealing hair bearing scalp has to be met. The following describes the basic reconstructive options depending on the size of the defect:

**Primary closure:** Defects size < 3cm can be closed primarily with tissue undermining.

**Secondary closure-** with serial debridements and closure or application of negative pressure wound therapy (NPWT) to decrease wound size and stimulate granulation tissue.

**Split thickness skin grafts:** can be used on healthy pericranium or galea in acute trauma or on the residual defect from where a flap is elevated. If the pericranium is absent the calvaria can be burr holed to stimulate granulation tissue and secondary skin grafting can be done, but the grafted area lacks sweat glands and hair follicles and is prone to frequent break downs.

Defects of 3-6 cm can be closed by local rotation flaps and the donor sites can be closed primarily by wide undermining. Defects 6-9 cm need larger local flaps based on single or double named feeding vessels, with the donor site being covered with a skin graft.

Defects > 9cm need free tissue cover either fasciocutaneous flaps (eg ALT flap), myocutaneous flaps (eg Latissimus dorsi) or greater omentum with skin grafting.

Tissue expansion is a revolutionary way to cover defects with healthy hair bearing tissue. Scalp defects of almost 50 % have been documented to be covered. The drawbacks are that it cannot be done in an acute sitting and requires placement of tissue expanders below the surrounding healthy tissue and serial expansion over a number of weeks to have adequate tissue for flap transposition, but cost, infection, the time of therapy are its drawback.

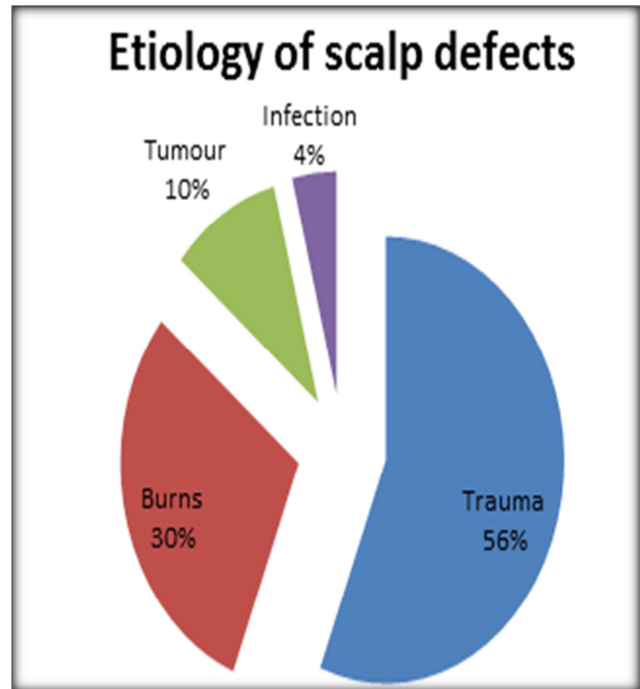
### Subjects and Methods

This is a retrospective observational study conducted over a period of 3 years from December 2015-2018 in tertiary care hospital. All patients of any age or sex presenting to our OPD or casualty with scalp tissue loss were included in this study. Various etiologies of scalp loss and our modes of reconstruction were documented. The data was tabulated and the mean and ratios were calculated using statistical calculators.

### Results

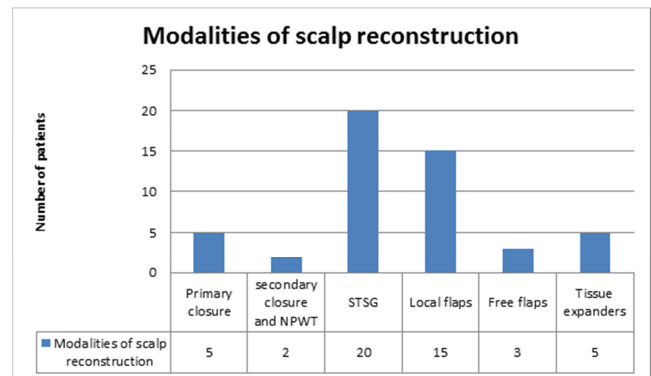
A total of 50 patients were included in this study of which the male:female ratio was 2.3:1. The most common age of presentation was 20-40 years (40%) followed by 0- 20 years (32%).

Trauma (RTA, Scalp avulsion, gunshot injury) was the most common etiology 28 (56%) followed by acute burns( electric/thermal) and post thermal alopecia 15(30%),5 patients (10%) had scalp defects post tumour excision , and 2 (4%) were due to post infection



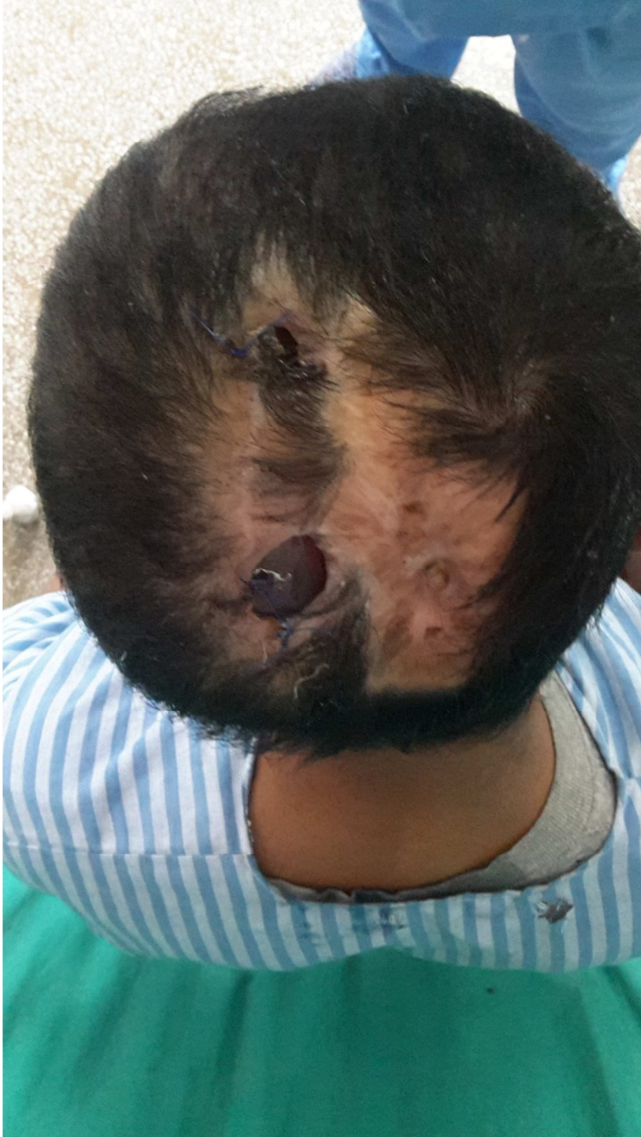While split thickness skin grafting (STSG) was the most common modality of reconstruction (40%) ,local flaps( rotation or transposition) were done in 15(30%) and tissue expanders were used in 5(10%)

The most common complication in flap cover patients was bleeding in 8 patients (16%) and infection in 2 patients (4%) patients with tissue expanders and partial graft loss in 12 (24%) patients.

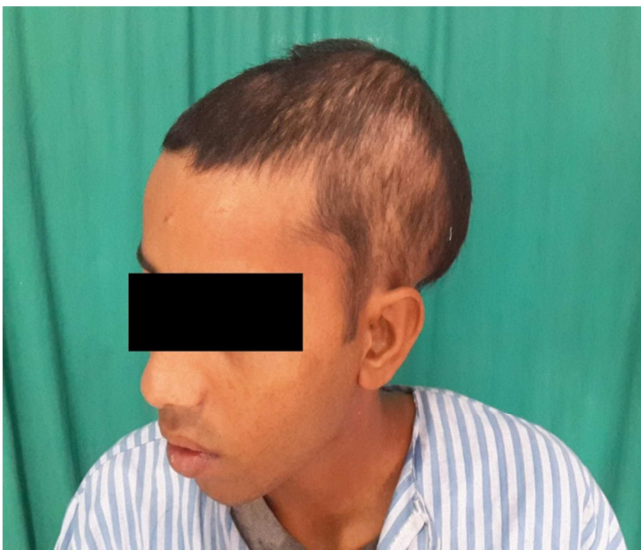

### Discussion

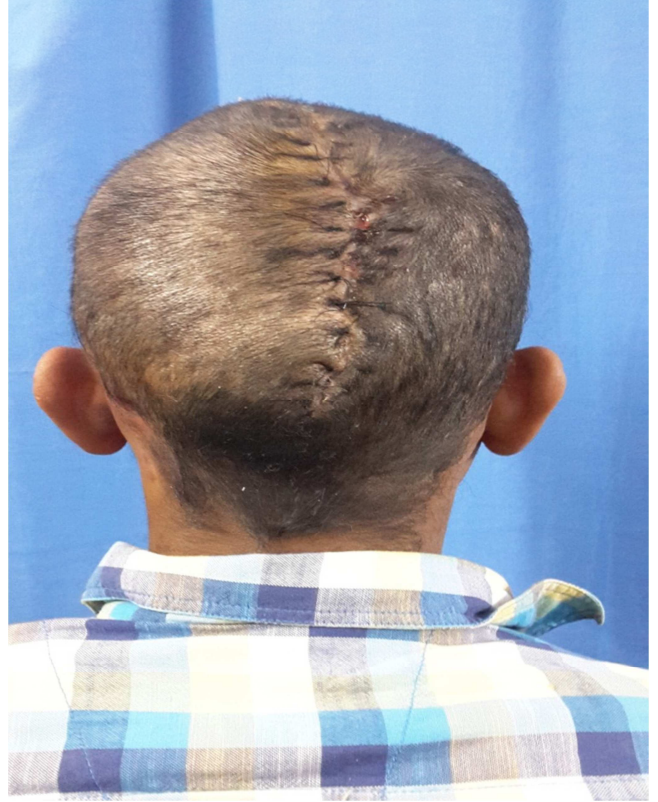Scalp reconstruction has changed dramatically over the years from trephination and waiting for secondary closure to microvascular free flaps and and tissue expansion. With the current demand changing, from just calvarial cover to a current more demanding cosmetic cover with hair bearing tissue, the plastic and reconstructive surgeon has to use all the tools in his reconstructive armamentarium keeping in mind the patient's condition and financial status.



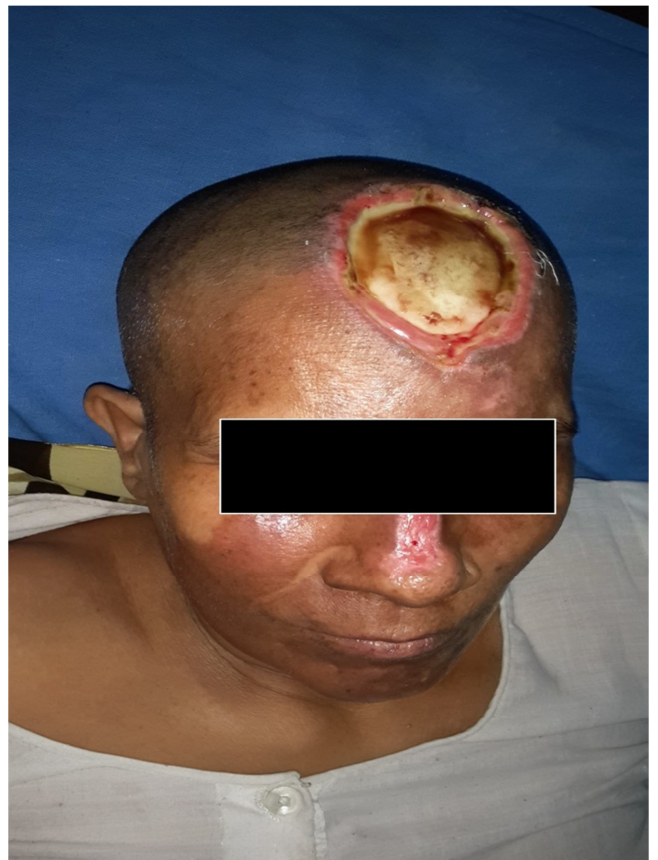**Figure 1: Post electric burn alopecia**



**Figure 2: Tissue expander in situ**



**Figure 3: Primary closure after expander removal with good hairline**



**Figure 4: Post electric burn full thickness loss of scalp and forehead**



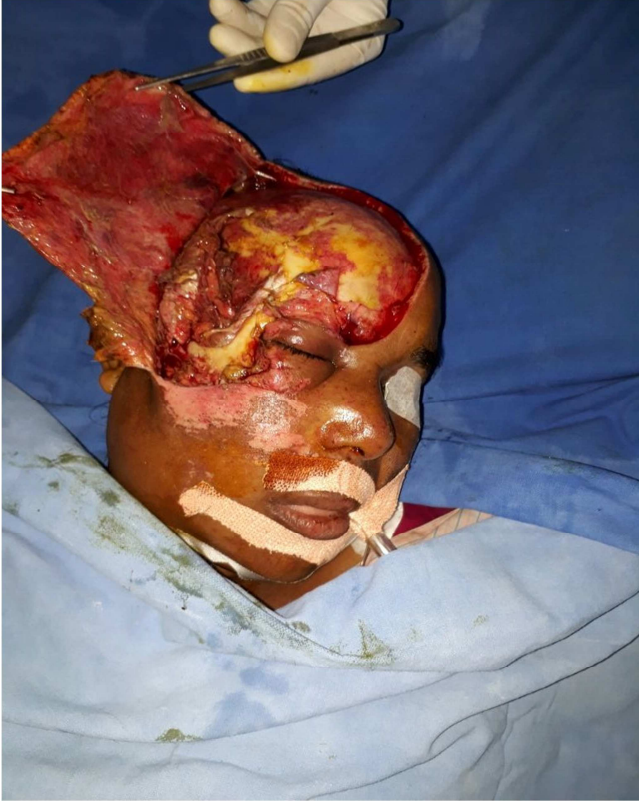

Figure 5: Local rotation flap

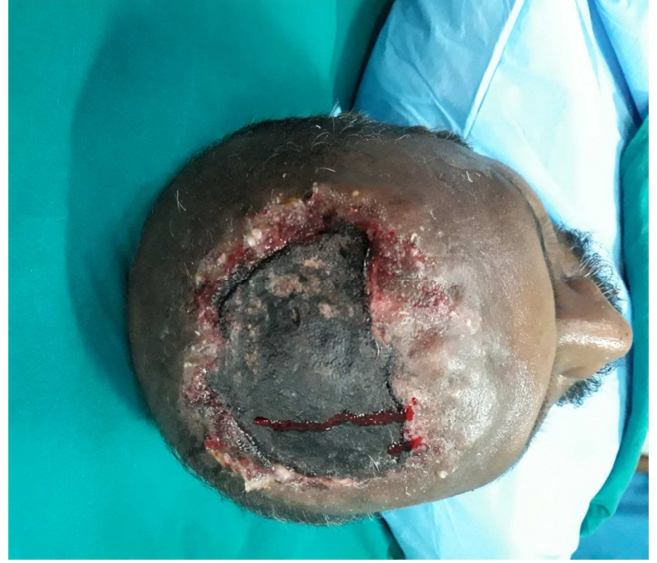

Figure 7: Spreading cellulitis scalp

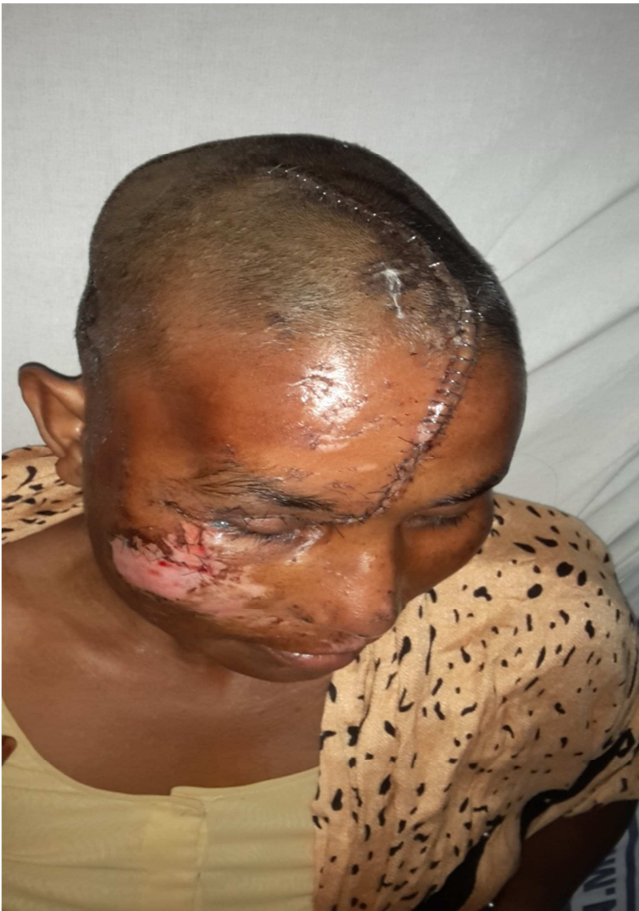

Figure 6: Post op

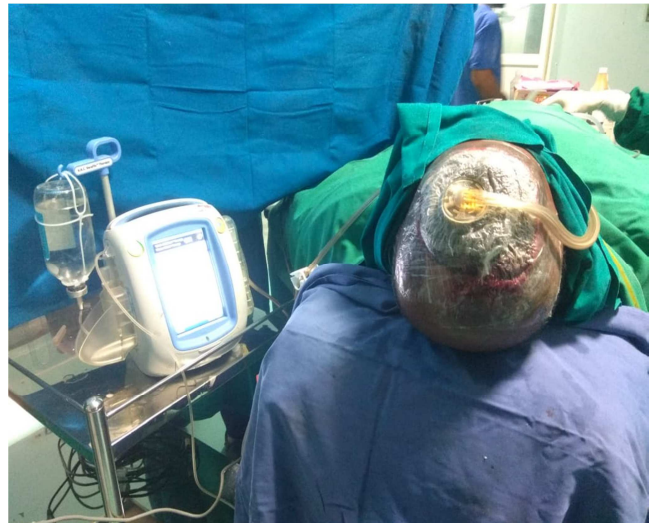

Figure 8: After placing NPWT

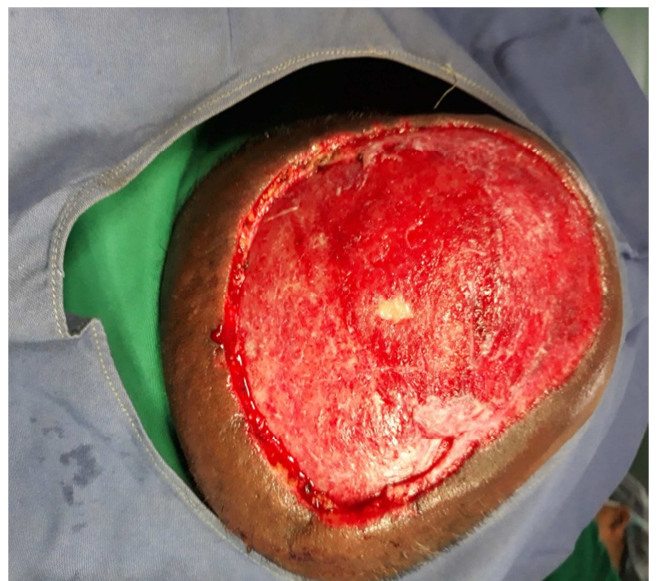

Figure 9: Post NPWT good granulation tissue



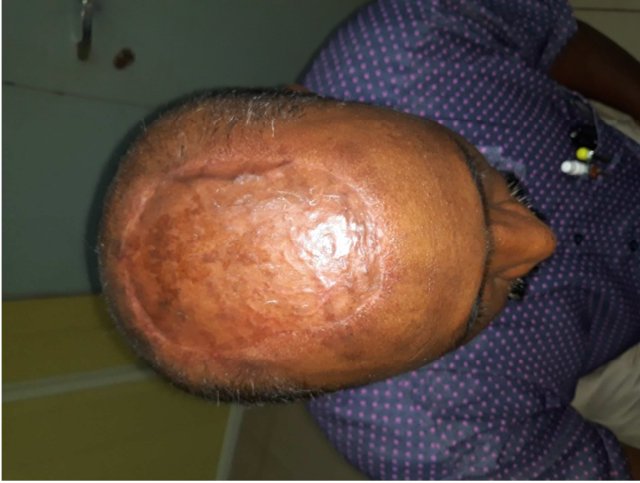

Figure 10: After STSG

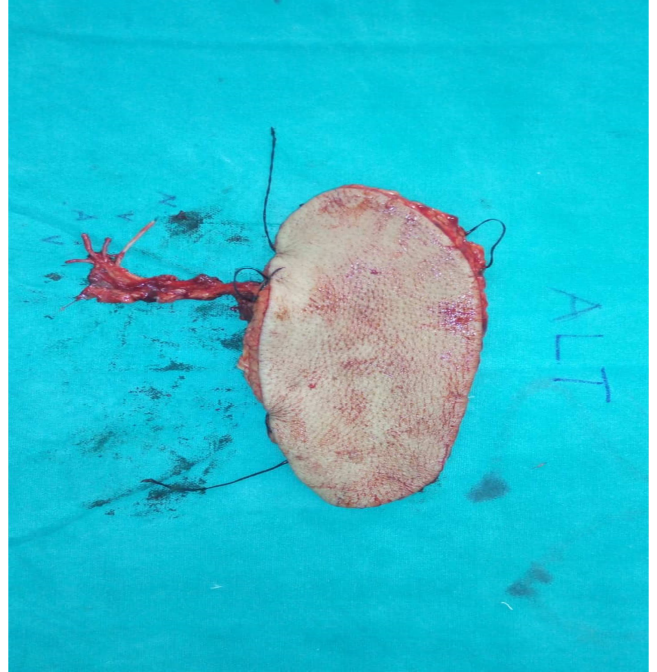

Figure 13: Free ALT flap

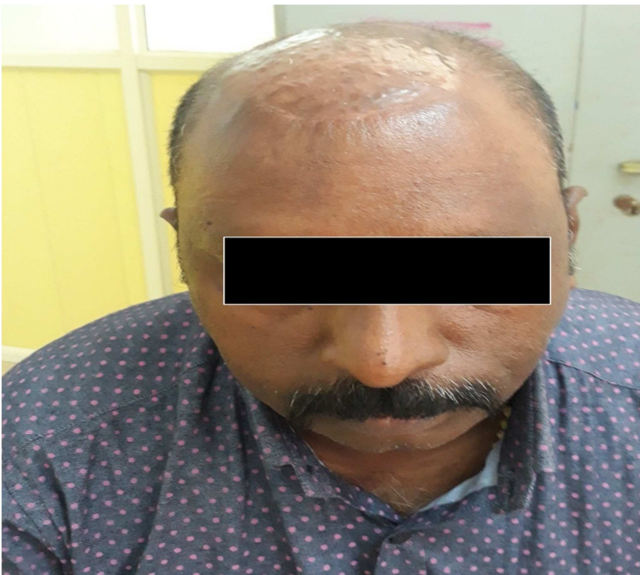

Figure 11: well settled STSG and good contour

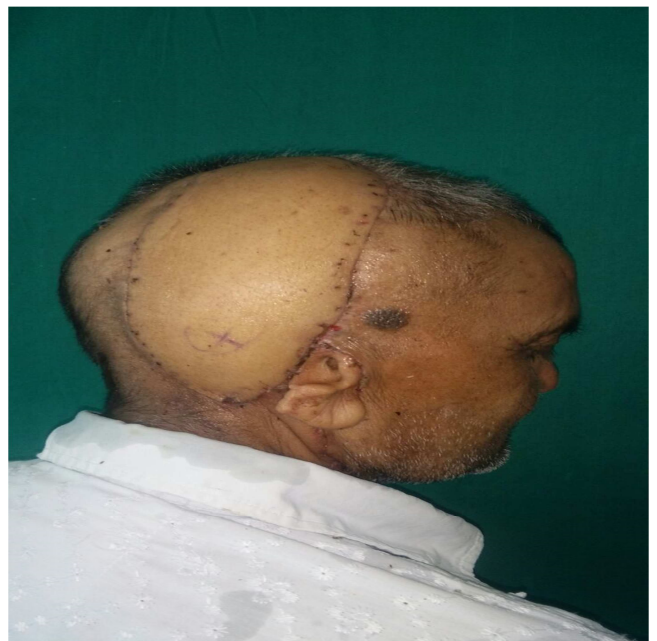

Figure 14: Well settled flap

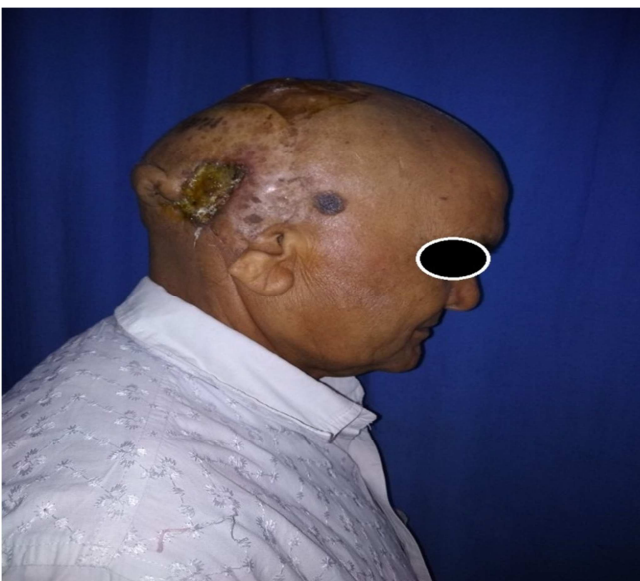

Figure 12: Case of scalp Tumour

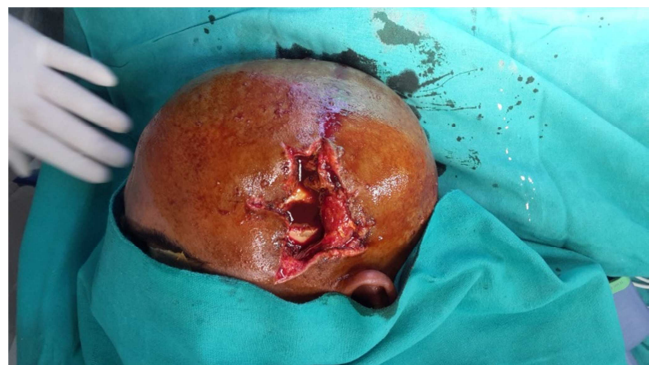

Figure 15: Gunshot Scalp



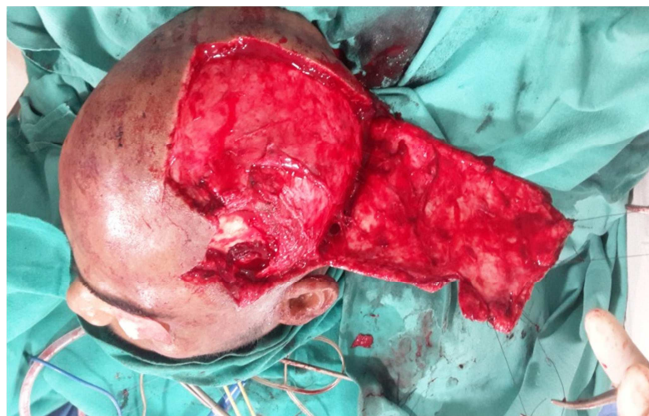


Figure 16: Debridement and transposition flap cover

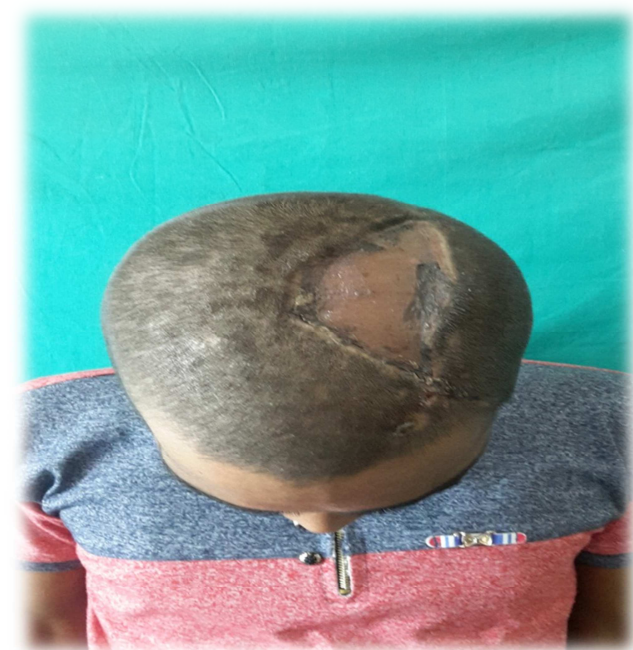

Figure 17: well settled flap with donor site STSG

Vivtor J et al 2017,<sup>[2]</sup> conducted a study on 135 electrical burn patients and found 9 patients to have scalp burn requiring reconstruction with grafts or flaps, in our study 15(30%) patients presented due to acute and chronic post burn alopecia requiring reconstruction [Figure 4,5,6].

Microsurgical reimplantation of avulsed scalp tissue or using free tissue transfer has revolutionized scalp reconstruction in a study done by Kalra et al (2013),<sup>[10]</sup> they performed microvascular reconstruction in 22 patients all being women, they reported 5 patients to have partial flap loss and 2 to have total flap loss needing repeat surgery, in our study microvascular scalp reimplantation was done in 1 female patient and two free ALT flaps were done in elderly males for post tumour reconstruction of the residual defect [Figure 12,13,14]. The free ALT flaps healed well but the scalp reimplant showed partial flap loss which was managed by skin grafting. Scalp reimplant shows variable take but only successful and immediate microvascular anastomosis can ensure adequate flap survival.<sup>[11,12]</sup>

Negative pressure wound therapy (NPWT) has

revolutionized the reconstructive process by stimulating granulation tissue and causing wound contracture, allowing for simpler reconstructive options like FTSG or STSG rather than complicated flaps. Bast F et al 2017,<sup>[13]</sup> used NPWT post scalp tumour excision in 2 patients and covered the wound with STSG within 3 weeks of the initial procedure, they reported good graft take and satisfactory patient response. In our study we too used NPWT in 2 patients but in their etiology were due to spreading scalp infection. NPWT stimulated good granulation and decreased surrounding tissue edema and infection, STSG could be achieved within 10 days of start of treatment with good graft take and patient satisfaction [Figure 7,8,9,10,11]

Tissue expansion has a unique advantage of covering a scalp defect with healthy hair bearing tissue various authors have described expanders for covering post burn alopecia and scalp defects.<sup>[14-16]</sup> We used tissue expanders in 5 patients with the main complication reported as infection due to the expander in 2 patients which was managed by antibiotics [Figure 1,2,3]. Calculating the size shape and number of expanders has always been a debate but many authors have given a few guide lines to help this.<sup>[17-19]</sup>

## Conclusion

An aesthetically pleasing scalp reconstruction requires a precise preoperative planning with detailed knowledge of scalp anatomy and blood supply. The wide armamentarium of techniques for reconstruction allows the plastic surgeon to give a much pleasing final result.

## References

1. Jason E.L, Jeffrey E. J. Reconstruction of Acquired Scalp Defects: An Algorithmic Approach. *Plast. Reconstr. Surg.* 116:54e, 2005.
2. Victor J, Shetty N, Manickavachakan N, Dinakara D. An algorithmic approach to reconstruction of complex scalp defects in electric burns. *Indian J Burns* 2017;25:44-51.
3. Robinson, E. F. Total avulsion of the scalp. *Surg. Gynecol. Obstet.* 7: 663, 1908
4. Orticochea, M. Four-flap scalp reconstruction technique. *Br. J. Plast. Surg.* 20: 159, 1967.
5. Neumann, C. G. The expansion of an area of skin by progressive distension of a subcutaneous balloon. *Plast. Reconstr. Surg.* 19: 124, 1957
6. Manders, E. R., Schenden, M. J., Furrey, J. A., et al. Skin expansion to eliminate large scalp defects. *Plast. Reconstr. Surg.* 74: 493, 1984
7. Miller, G. D. H., Anstee, E. J., and Snell, J. A. Successful replantation of an avulsed scalp by microvascular anastomoses. *Plast. Reconstr. Surg.* 58: 133, 1976.
8. Ikuta, Y. Microvascular free transfer of omentum. In L. O. Vasconez and B. Strauch (Eds.), *Grabb's Encyclopedia of Flaps*, 2nd Ed. Philadelphia: Lippincott-Raven, 1998. Pp. 42-44.
9. Pennington, D. G., Stern, H. S., and Lee, K. K. Free flap reconstruction of large defects of the scalp and calvarium. *Plast. Reconstr. Surg.* 83: 655, 1989.
10. Chicarelli, Z. N., Ariyan, S., and Cuono, C. B. Single-stage repair of complex scalp and cranial defects with the free radial forearm flap. *Plast. Reconstr. Surg.* 77: 577, 1986.
11. Tolhurst, M. D., Carstens, M. H., Greco, R. J., and Hurwitz, D. J. The surgical anatomy of the scalp. *Plast. Reconstr. Surg.* 87: 603, 1991
12. Kalra GS, Goil P, Chakotiya PS. Microsurgical reconstruction of major scalp defects following scalp avulsion. *Indian J Plast Surg* 2013;46:486-92
13. Lu MM. The successful replacement of avulsed scalp. *Plast Reconstr Surg* 1969;43:231-4.
14. Araki K, Hatano T, Toki M, Ogino A, Tsukahara T. Replantation of a



- totally avulsed scalp without microvascular anastomosis. *Acta Neurochir (Wien)* 1999;141:1353-4
15. Bast F, Chadha P, Jakharia-Shah N, Collier J. Treatment of Large Cutaneous Defects of the Scalp by Vacuum-Assisted Wound Dressing. *Ann Clin Otolaryngol.* 2017; 2(3): 1020.
  16. Guzey S, Alhan D, Şahin I, Aykan A, Eski M, Nişancı M, et al. Our experiences on the reconstruction of lateral scalp burn alopecia with tissue expanders. *Burns* 2015;41:631-
  17. Raposio E. Scalp expansion: Surgical considerations and possible future directions. *Indian J Plast Surg* 2018;51:84-8
  18. Mailet-Declerck M, Calibre C, Herbaux B, Duquennoy-Martinot V. Long-term results in scalp tissue expansion in children. *Eur J Pediatr Surg* 2012;22:269-73.
  19. Desai SC, Sand JP, Sharon JD, Branham G, Nussenbaum B. Scalp reconstruction: An algorithmic approach and systematic review. *JAMA Facial Plast Surg* 2015;17:56-66
  20. Nordström RE, editor. *Scalp*. In: *Tissue Expansion*. Boston (MA): Butterworth-Heinemann; 1996. p. 107-23.
  21. Nordström RE, Raposio E, Fan J. Geometric planning. In: Nordstrom RE, editor. *Tissue Expansion*. Boston (MA): Butterworth-Heinemann; 1996. p. 13-7.

**Copyright:** © the author(s), publisher. Academia Journal of Surgery is an Official Publication of “Society for Health Care & Research Development”. It is an open-access article distributed under the terms of the Creative Commons Attribution Non-Commercial License, which permits unrestricted non-commercial use, distribution, and reproduction in any medium, provided the original work is properly cited.

**How to cite this article:** Mahmud AA, Khurram F, Amar DN, Naik A. Various Modalities of Scalp Reconstruction: A Review of Literature and Case Series. *Acad. J Surg.* 2018;1(2):4-10.

DOI: [dx.doi.org/10.21276/ajs.2018.1.2.2](https://doi.org/10.21276/ajs.2018.1.2.2)

**Source of Support:** Nil, **Conflict of Interest:** None declared.