

# Inflammatory Fibroid Polyp of Jejunum Causing Intussusceptions Leading to Acute Intestinal Obstruction - 2 Case Reports and Review of Literature

Kavatekar Prasad<sup>1</sup>, Darshan S Nayak<sup>2</sup>, Rashmi Vaidya<sup>3</sup>

<sup>1</sup>Consultant and HOD, Department of Surgical Gastroenterology, Sahyadri Narayana Multi-specialty Hospital, Shimoga, Karnataka, India, <sup>2</sup>Consultant, Department of Surgical Gastroenterology, Sahyadri Narayana Multi-specialty Hospital, Shimoga, Karnataka, India, <sup>3</sup>Consultant Pathologist, Sahyadri Narayana Multi-specialty Hospital, Shimoga, Karnataka, India.

## Abstract

Intussusception is a serious condition in which part of the intestine slides into an adjacent part of the intestine, this telescoping action often cause blocking of food or fluid from passing through. Inflammatory fibroid polyp of jejunum is very rare, it is leading to jejuno jejunal intussusception is also very rare. These polyps are benign, tumour like lesions in the gastrointestinal tract which are typically observed in the stomach, but can occur anywhere in the gastrointestinal tract. We report 2 cases with an inflammatory fibroid polyp of the jejunum presenting as an acute intussusception who were successfully treated with resection and primary anastomosis.

**Keywords:** Jejunojejunal intussusception, inflammatory fibroid polyp.

**Corresponding Author:** Darshan S Nayak, Consultant, Department of Surgical Gastroenterology, Sahyadri Narayana Multi-specialty Hospital, Shimoga, Karnataka, India.

E-mail: [dr.darshan.nayak@gmail.com](mailto:dr.darshan.nayak@gmail.com)

Received: 30 June 2021

Revised: 02 September 2021

Accepted: 12 September 2021

Published: 30 November 2021

## Introduction

Intussusception is a serious condition in which part of the intestine slides into an adjacent part of the intestine, this telescoping action often cause blocking of food or fluid from passing through. Intussusception is very rare in adults.<sup>[1]</sup> Small bowel intussusceptions are typically caused by benign lesions and radiologic examinations can be used for their diagnosis.<sup>[2]</sup> Conservative management of small bowel intussusceptions tried successfully in children which includes fluid therapy, electrolyte replacement, and bowel rest. In adults usually it is complete obstruction and surgical management should be considered.<sup>[3]</sup>

The exact etio pathogenesis for IFPs remains unknown. Most small bowel IFPs are asymptomatic and usually go undetected until they produce symptoms. IFPs are responsible for roughly 2% of all small bowel intussusceptions. They act as a lead point for intussusception by telescoping into the distal bowel loops.<sup>[4,5]</sup> Nearly 87 such cases have been reported in the literature.<sup>[6-16]</sup> However, if the IFP is sufficiently large and pedunculated, it could cause mechanical intraluminal obstruction with or without Intussusception. The most

effective treatment for Intussusception caused by an IFP is an exploratory laparotomy. Here we report 2 cases of an IFP in the jejunum (rare) and presenting as intussusception.

### Case 1

50 Yr old obese female patient with hypertension and post-hysterectomy status presented with pain abdomen for 7 days, on and off, associated with abdominal distension, vomiting and obstipation for 5 days. No h/o fever, Jaundice, urinary disturbances or G.I bleeding. She has altered bowel habits since 5 months for which she wasn't evaluated earlier. For the above symptoms recently she was admitted and got evaluated in another hospital with USG abdomen where they suspected as intestinal obstruction possibly due to ileo-ileal/ ileo-caecal intussusception and she was referred to us for further evaluation and management.

On examination she was found to be in haemodynamically stable except tachycardia (HR - 110/min), abdomen was distended with generalized tenderness, no guarding or rebound tenderness. She was reevaluated in our center with CECT abdomen [Figure 1] which showed dilatation of jejunal loops with transition point in the mid ileum. Bowel within bowel

appearance in the mid ileum with mesenteric fat stranding in the central bowel. Findings are of concern for small bowel Intussusception with proximal small bowel obstruction, underlying neoplastic etiology has to be excluded. The distal ileal loops and colonic loops are collapsed. No evidence of strangulation.

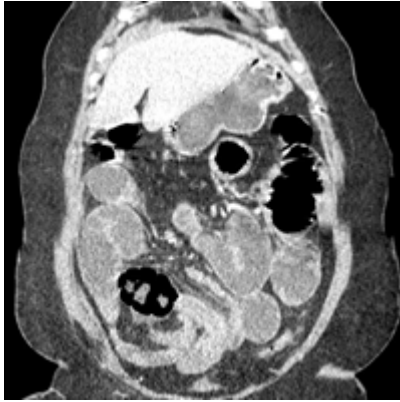


Figure 1: Coronal image showing bowel within bowel with hypodense lesion.

She was taken up for emergency exploratory laparotomy and found to have a) intussusception in mid segment of small bowel (5ft from DJ flexure and 10ft from IC junction) with significant dilatation of proximal jejunum and collapsed distal segment of ileum. [Figure 2]. No e/o gangrene or perforation of bowel. After reducing the intussusception found a firm to hard lesion of 5x3cm within the jejunum with few soft lymph nodes at the root of mesentery measuring approximately 1x1cm. Liver- normal, no e/o metastasis. Mild sero purulent free fluid in abdomen. Affected segment was resected giving adequate margins on either side and primary anastomosis performed(side to side stapled). Cut section of mucosa showed 5x3cms pedunculated, firm to hard growth within the lumen.

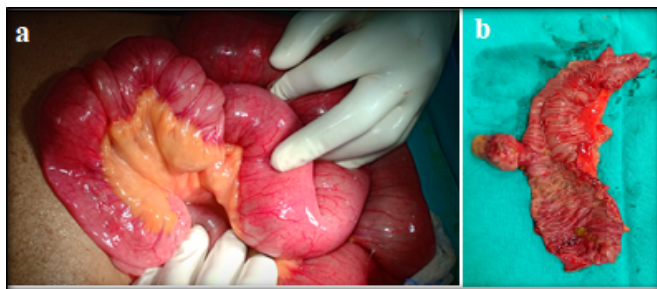


Figure 2: a: operative photo of jejunum-jejunal intussusception, b: Cut section of bowel showing pedunculated polyp

Post-operative period was uneventful, was kept nil by mouth with ryle's tube aspiration for 3 days, started orally from

day 4 onwards and later soft diet which she tolerated well and discharged on day 6. She had mild surgical site wound infection which was managed conservatively with regular dressing and improved over 1 month.

Histopathology [Figure 3] of specimen were s/o Inflammatory Fibroid Polyp with IHC CD 34 positive and CD -117 being negative and Ki 67 index is < 5%.

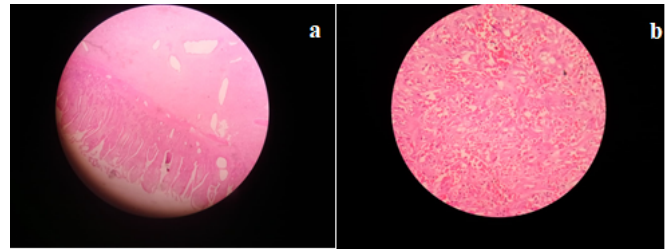


Figure 3: a) Microscopic image showing well defined lesion located in the submucosa, b) Showing spindle shaped cells with Congested vessels, benign fibrous tissue. H and E, 10X.

## Case 2

46 year old male patient presented with h/o pain in upper abdomen since 3-4 months, on and off, increased since 1 month, associated with h/o vomiting 7-8 episodes in 20days, and upper abdominal distension. Pain and distension relieved following vomiting.

He also give h/o dyspepsia, epigastric burn, heart burn, increased belching present during these period. Recent h/o loss of appetite and insignificant weight loss also present.

On examination his vitals were stable, abdominal examination revealed mild tenderness in right and left upper quadrant and an ill defined lump palpable just above umbilicus, No guarding/ rebound tenderness.

Initially he was admitted under Medical gastroenterologist for evaluation and underwent CECT abdomen (fig.4) which showed intussusception involving the proximal small bowel loops with dilatation of the proximal jejunum with a non enhancing polypoid soft tissue as the lead point (? malignant polyp) with few enlarged mesenteric lymph nodes.

He was taken up for emergency exploratory laparotomy and found to have minimal serous fluid in peritoneal cavity, evidence of jejunum-jejunal intussusception – starting ~20-25cms from duodeno jejunal flexure, for a length of ~10-15cms. Following reduction of intussusception, a hard growth palpable within the jejunal lumen (which was a lead point). Cut section of mucosa showed a large pedunculated, polypoid growth in Jejunum, ~5x3cms, with at least 10cms margin on either side. (fig.5) along with few multiple enlarged mesenteric

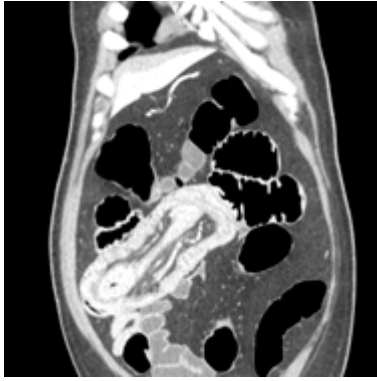


Figure 4: Coronal image showing intussusception with a large hypodense lesion within the bowel.

lymph nodes, firm to hard in consistency, largest ~2cms. Proximal small bowel were grossly dilated and edematous.

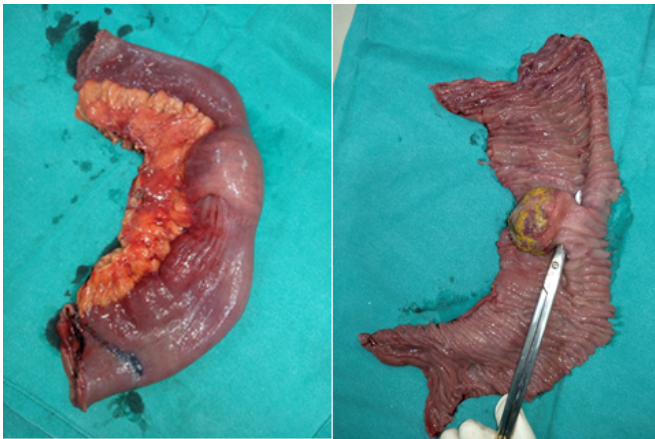


Figure 5: a). Resected segment of intussusception, b: Cut section showing pedunculate polyp

Hence he also underwent resection of affected segment giving adequate margin on either side and hand sewn primary anastomosis performed. feeding Jejunostomy was added to support the nutrition in post operative period. Post operatively intravenous albumin infusion was started and was given for 3 days in view of significant bowel dilatation and hypoalbuminemia (s.alb-2.5gm/dl). Enteral feeds were started from day1 onwards which was gradually progressed. He was kept nil by mouth and on ryle's tube aspiration for 5 days. Ryle's tube was removed on day 5 and he was started on liquid diet which was gradually progressed to soft diet and was discharged in stable condition on day 7.

Histopathology [Figure 6] of the specimen with IHC were suggestive of Inflammatory fibroid polyp with CD 34 positive

and CD - 117 negative and ki 67 index < 5%.

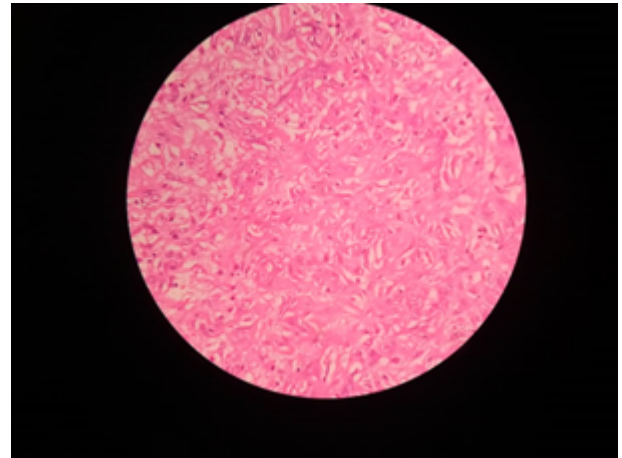


Figure 6: Microscopic image Showing spindle shaped cells with Congested vessels, benign fibrous tissue. H and E, 10X

## Discussion

IFPs have no metastatic potential. They remain dormant until they are large enough to produce local symptoms that are dependent on their location.<sup>[4]</sup> Small bowel lesions are not usually diagnosed pre-operatively because they present with vague symptoms of bowel obstruction due to intussusception. Laboratory investigations and plain radiographs are not helpful in making the diagnosis as they will demonstrate non-specific findings that are more in keeping with bowel obstruction.<sup>[5]</sup>

Diagnostic laparoscopy may be useful.<sup>[3]</sup> Resection and anastomosis of the small bowel remains the gold standard of treatment of small bowel IFPs. Stomas are reserved for a few cases that may present late after perforation, with severe peritoneal contamination that may be hostile for anastomotic healing. They are well localized tumors with no risk for local recurrence after complete excision and they lack malignant potential.<sup>[4]</sup>

Generally, IFPs are grey, sessile, or pedunculated polypoid lesions that arise from the sub mucosa into the lumen of the bowel, often with the ulceration of the overlying mucosa. IFPs typically measure 2–5 cm in diameter, although giant IFPs larger than 20 cm have been reported.<sup>[14]</sup>

Histologically, IFPs are characterized by inflammatory infiltrates (predominantly eosinophils) and the localized proliferation of mononuclear spindle-shaped cells.<sup>[17]</sup> IHC is confirmatory in diagnosis where it is positive only for CD 34 and vimentin but negative for CD 117 (specific for GIST).<sup>[18]</sup> Gastric IFPs are treated with endoscopic removal, and all 87 cases

of small bowel IFPs reported from 1976 to 2011 were treated by surgical resection.<sup>[6-16]</sup> Intussusception caused by an IFP is best treated with an exploratory laparotomy, because IFPs do not recur after surgical resection.

## Conclusion

We have described a rare case of Intussusception caused by IFP, where surgical resection was necessary to alleviate the patient's symptoms.

## References

1. Agha FP. Intussusception in adults. *AJR Am J Roentgenol*. 1986;146(3):527-558. Available from: <https://doi.org/10.2214/ajr.146.3.527>.
2. Akbulut S. Intussusception due to inflammatory fibroid polyp: a case report and comprehensive literature review. *World J Gastro-enterol*. 2012;18(40):5745-52. Available from: <https://doi.org/10.3748/wjg.v18.i40.5745>.
3. Fevang BT, Jensen D, Svanes K, Viste A. Early operation or con-servative management of patients with small bowel obstruction? *Eur J Surg*. 2002;168(8-9):475-81. Available from: <https://doi.org/10.1080/110241502321116488>.
4. Marinis A, Yiallourou A, Samanides L, Dafnios N, Anastasopoulos G, Vassiliou I, et al. Intussusception of the bowel in adults: A review. *World J Gastroenterol*. 2009;15(4):407-411. Available from: <https://dx.doi.org/10.3748/wjg.15.407>.
5. Johnstone JM, Morson BC. Inflammatory fibroid polyp of the gastrointestinal tract. *Histopathology*. 1978;2(5):349-61. Available from: <https://doi.org/10.1111/j.1365-2559.1978.tb01727.x>.
6. Vijayaraghavan R, Sujatha Y, Kv V, Belagavi CS. Inflammatory fibroid polyp of jejunum causing jejunojejunal intussusception. *Indian J Gastroenterol*. 2004;23:190-192.
7. Winkler H, Zelikovski A, Gutman H, Mor C, Reiss R. Inflammatory fibroid polyp of the jejunum causing intussusception. *Am J Gastroenterol*. 1986;81:598-601.
8. Sah S, Agrawal C, S R. Inflammatory fibroid polyp of the jejunum presenting as intussusception. *Indian J Pathol Microbiol*. 2002;45(1):119-121.
9. Shimer G, Helwig E. Inflammatory fibroid polyps of the intestine. *Am J Clin Pathol*. 1984;81(6):708-714. Available from: <https://doi.org/10.1093/ajcp/81.6.708>.
10. Gönül II, Erdem Ö, Ataoglu Ö. Inflammatory fibroid polyp of the ileum causing intussusception: Case report. *Turk J Gastroenterol*. 2004;15(1):59-62.
11. Shih LN, Chang SL, Chuang SM, Kuo CF. Inflammatory fibroid polyp of the jejunum causing intussusception. *Am J Gastroenterol*. 1997;92:162-164.
12. Dawson PM, Shousha S, Burn JI. Inflammatory fibroid polyp of the small intestine presenting as intussusception. *Br J Clin Pract*. 1990;44(11):495-502.
13. Mashiko T, Sakoda N, Nakano A, Masuoka Y, Hirabayashi K, Yamamoto S, et al. Adult Ileo-ileal Intussusception Due to Inflammatory Fibroid Polyp: A Case Report. *Tokai J Exp Clin Med*. 2020;45(4):202-206.
14. Rubinstein R, Mogle P, Merguerian P, Rosenmann E. Inflammatory fibroid polyp of the small intestine: report of two cases and review of the literature. *Israel J Med Sci*. 1983;19(9):828-861.
15. Rehman S, Gamie Z, Wilson TR, Coup A, Kaur G. Inflammatory fibroid polyp (Vanek's tumour), an unusual large polyp of the jejunum: a case report. *Cases J*. 2009;2:7152. Available from: <https://dx.doi.org/10.1186/1757-1626-2-7152>.
16. Cawich SO, Gibson TN, Mitchell DI. Adult Intussusception from an Inflammatory Fibroid Polyp: A Case Report And Review Of The Literature. *Internet J Pathol*. 2008;7(1):1.
17. Navas-Palacios JJ, Colina-Ruizdelgado F, Sanchez-Larrea MD, Cortes-Cansino J. Inflammatory fibroid polyps of the gastrointestinal tract. An immunohistochemical and electron microscopic study. *Cancer*. 1982;51(9):1682-90. Available from: [https://doi.org/10.1002/1097-0142\(19830501\)51:9%3C1682::aid-cnrcr2820510921%3E3.0.co;2-p](https://doi.org/10.1002/1097-0142(19830501)51:9%3C1682::aid-cnrcr2820510921%3E3.0.co;2-p).
18. Suen KC, Burton JD. The spectrum of eosinophilic infiltration of the gastrointestinal tract and its relationship to other disorders of angitis and granulomatosis. *Hum Pathol*. 1979;10(1):31-43. Available from: [https://doi.org/10.1016/s0046-8177\(79\)80070-2](https://doi.org/10.1016/s0046-8177(79)80070-2).

**Copyright:** © the author(s), 2021. It is an open-access article distributed under the terms of the Creative Commons Attribution License (CC BY 4.0), which permits authors to retain ownership of the copyright for their content, and allow anyone to download, reuse, reprint, modify, distribute and/or copy the content as long as the original authors and source are cited.

**How to cite this article:** Prasad K, Nayak DS, Vaidya R. Inflammatory Fibroid Polyp of Jejunum Causing Intussusceptions Leading to Acute Intestinal Obstruction - 2 Case Reports and Review of Literature. *Acad. J Surg*. 2021;4(2):14-17.

DOI: [dx.doi.org/10.47008/ajs/2021.4.2.4](https://doi.org/10.47008/ajs/2021.4.2.4)

**Source of Support:** Nil, **Conflict of Interest:** None declared.