

Role of Prophylactic Neck Dissection in Node Negative Carcinoma of Tongue

Kaushik Hari^{1D}, CN Srikanth^{1D}

Assistant Professor, Department of Surgical Oncology, Saptagiri Institute of Medical Sciences and Research Centre, Bangalore, Karnataka, India.

Abstract

Background: To ascertain the role of prophylactic neck dissection in cN0 tongue cancers. To assess the role of tumour thickness as a guide for the choice type of neck dissection in tongue cancers. **Subjects and Methods:** A single institutional study by the Department of Surgical Oncology in a tertiary care centre. Biopsy of the tumour site has been done and biopsy proven carcinoma tongue cases have been included in the study. A total of 110 cases of carcinoma tongue were recorded. 50 cases out of the 110 cases were cN0. All the cases were operated by wide local excision of primary tumour and modified radical neck dissection. After the histopathological assessment tumours were divided into two categories, tumours with thickness more than 4mm and those with thickness less than 4mm. Pathological node positivity in both these categories is studied. All the cases were followed up and those with positive nodes were advised post-operative radiotherapy. **Results:** Among 110 cases studied 50 cases have no clinical nodes at presentation and 60 had cervical lymph node metastases at presentation. Among the 50 cases with no clinical nodes at presentation, histopathology showed that 20 cases (40%) had primary tumour less than 4mm and 30 cases(60%) had primary tumour more than 4mm. 10 of the 20 cases(50%) with tumour thickness less than 4mm had lymph node metastases on pathological assessment and 24 of the 30 cases(80%) with tumour thickness more than 4mm had lymph node metastases on pathological assessment. Among the category of tumor thickness less than 4mm, 4 cases (20%) had lymph node metastases to level 1, 3 cases (15%) had lymph node metastases to level 2, 3 cases (15%) had lymph node metastases to level 3, 1 case (5%) had lymph node metastases to level 4. Among category of tumour thickness more than 4mm, 10 cases (33.3%) had metastases to level 1, 9 cases (30%) had metastases to level 2, 5 cases(16.6%) had metastases to level 3, 3 cases(10%) had metastases to level 4 and 4 cases (13.33%) had metastases to level 5. **Conclusion:** The role of neck dissection is the most important step in the management of carcinoma tongue. Prophylactic neck dissection has a definitive role in clinically node negative tongue cancers. Type of neck dissection based on our results showed supraomohyoid neck dissection would be sufficient for tumours less than 4mm and modified radical neck dissection for tumours more than 4mm thickness. Even most advanced imaging techniques like PET scan and SLNB could not completely derail the need for prophylactic neck dissection in carcinoma tongue.

Keywords: Carcinoma tongue, cN0, cervical lymph node metastases, wide local excision, modified radical neck dissection, supraomohyoid neck dissection, post operative radiotherapy, advanced imaging techniques.

Corresponding Author: CN Srikanth, Assistant Professor, Department of Surgical Oncology, Saptagiri Institute of Medical Sciences and Research Centre, Bangalore, Karnataka, India.

E-mail: sreekanthchakravaram@gmail.com

Received: 26 June 2020

Revised: 21 July 2020

Accepted: 6 August 2020

Published: 31 December 2020

Introduction

Oral cavity cancer is one of the most common cancers in India.^[1,2] Carcinoma tongue is the most common site of oral cavity cancer worldwide. The management of carcinoma tongue has been challenging because of its aggressive lymph nodal spread and adverse effects of treatment on Oral and pharyngeal function. Advanced disease has a poor prognosis and drastically effects the quality of life. Squamous cell carcinoma is the most common malignancy of the tongue.^[3,4]

Cervical lymph node metastases is the most important prognostic factor in oral cavity cancers.^[5] So the management of cervical lymph node metastases has attained a most important role in the management of carcinoma tongue. The role of prophylactic neck dissection in carcinoma tongue has been a topic of debate since long since its incorporation into the management protocol of carcinoma tongue.^[6,7]

Aims and Objectives

To ascertain the role of prophylactic neck dissection in cN0 tongue cancers

To assess the role of tumour thickness as a guide for the choice type of neck dissection in tongue cancers

Subjects and Methods

A single institutional study by the department of Surgical Oncology in a tertiary care centre. Biopsy of the tumour site has been done and biopsy proven carcinoma tongue cases have been included in the study.

Inclusion criteria

All cases of SCC of anterior 2/3rd of tongue

Exclusion criteria

Patients of posterior 1/3rd of tongue malignancies

Patients with lymph node metastasis

Duration: June 2018 to December 2019

A total of 110 cases of carcinoma tongue were recorded. 50 cases out of the 110 cases were cN0. All the cases were operated by wide local excision of primary tumour and modified radical neck dissection. After the histopathological assessment tumours were divided into two categories, tumours with thickness more than 4mm and those with thickness less than 4mm. Pathological node positivity in both these categories is studied. All the cases were followed up and those with positive nodes were advised post-operative radiotherapy.

Results

Among 110 cases studied 50 cases have no clinical nodes at presentation and 60 had cervical lymph node metastases at presentation.

Table 1: Number of Cases

Number of cases	110
cN0	50
cN+	60

Among the 50 cases with no clinical nodes at presentation, histopathology showed that 20 cases (40%) had primary tumour less than 4mm and 30 cases (60%) had primary tumour more than 4mm.

10 of the 20 cases (50%) with tumour thickness less than 4mm had lymph node metastases on pathological assessment and 24 of the 30 cases (80%) with tumour thickness more than 4mm had lymph node metastases on pathological assessment.

Among the the category of tumor thickness less than 4mm, 4 cases (20%) had lymph node metastases to level 1, 3 cases (15%) had lymph node metastases to level 2, 3 cases (15%)

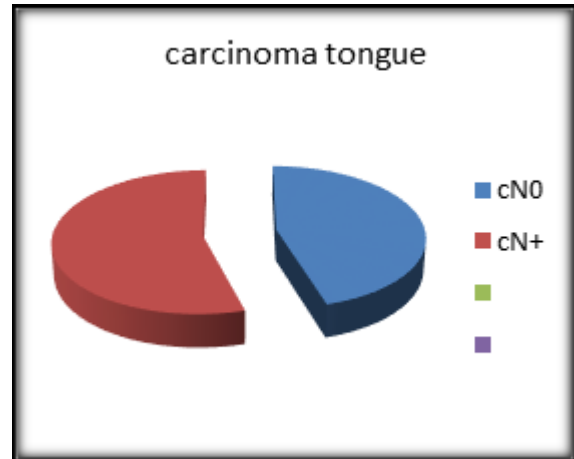


Figure 1: Clinical node status

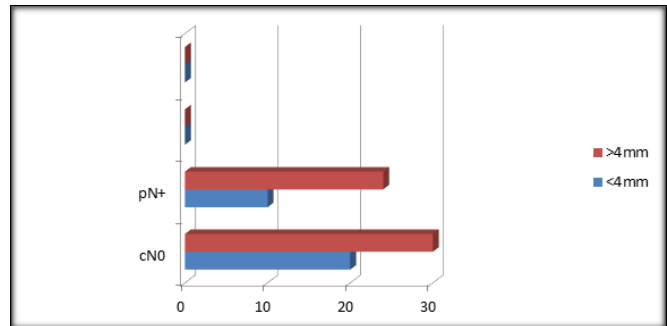


Figure 2: Categories

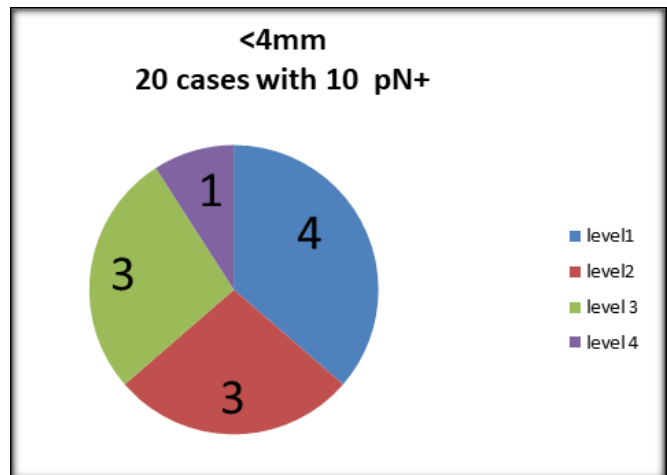


Figure 3: Level Wise Nodal Distribution In <4MM Category.

Table 2: Categories

Categories	Less than 4mm	Percentage	More than 4mm	Percentage
Number of cases	20	40%	30	60%
Positive nodes	10	50%	24	80%
Levels	Percentage		Percentage	
1	4	20%	10	33.3%
2	3	15%	9	30%
3	3	15%	5	16.6%
4	1	5%	3	10%
5	-	-	4	13.33%

had lymph node metastases to level 3, 1 case (5%) had lymph node metastases to level 4.

Among category of tumour thickness more than 4mm, 10 cases (33.3%) had metastases to level 1, 9 cases (30%) had metastases to level 2, 5 cases (16.6%) had metastases to level 3, 3 cases (10%) had metastases to level 4 and 4 cases (13.33%) had metastases to level 5.

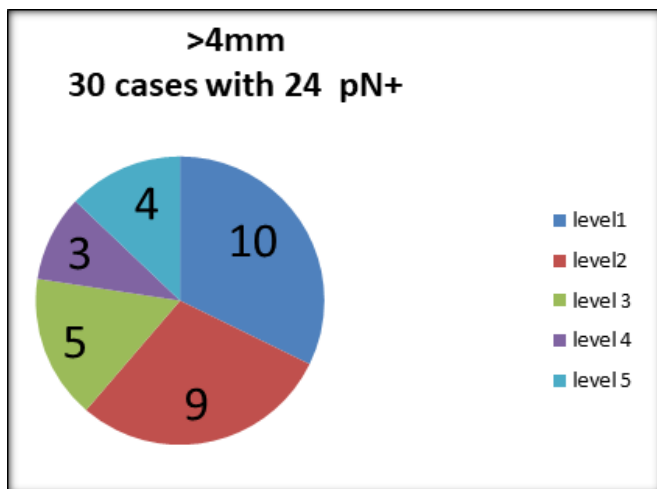


Figure 4: Level wise nodal distribution in >4MM Category.

Discussion

Cervical Lymph node metastases is the most important prognostic factor in squamous cell carcinoma of tongue.^[8] The incidence of cervical lymph node metastases in carcinoma tongue is about 40 to 50%.^[9] Identification of patients at risk of cervical lymph node metastases can improve the survival in the patients. Imaging can detect suspected cervical lymph node metastases but its sensitivity has been less.^[10,11] Histopathological factors like tumour thickness and grade

have been increasingly used as a guide to cervical lymph node metastases.^[12-15]

In our study we had lymph node spread to all levels of cervical lymph nodes in tumours more than 4mm and up to level 4 in tumours less than 4mm thickness. The percentage of nodes involved is clearly in association with tumour thickness. 80 percent of tumours more than 4mm thickness had cervical lymph node metastases whereas only 50 percent of tumours less than 4mm thickness had cervical lymph node metastases. There is multiple level involvement and increased number of nodes involved in association with tumour thickness. There is a definite role of elective prophylactic neck dissection in carcinoma tongue. Based on our study we found that supraomohyoid neck dissection for tumours less than 4mm thickness and modified radical neck dissection for tumours more than 4mm is the most appropriate choice of neck dissection.

Conclusion

The role of neck dissection is the most important step in the management of carcinoma tongue. Prophylactic neck dissection has a definitive role in clinically node negative tongue cancers. Type of neck dissection based on our results showed supraomohyoid neck dissection would be sufficient for tumours less than 4mm and modified radical neck dissection for tumours more than 4mm thickness. Even most advanced imaging techniques like PET scan and SLNB could not completely derail the need for prophylactic neck dissection in carcinoma tongue.

References

1. Parkin DM, Whelan SL, Ferlay J. Cancer incidence . 1997;11(3):24-9.
2. Indian Council of Medical Research: Annual reports of National Cancer Registry project of India. ICMR. 1982;17(4):113-8.

3. Byers RM, El-Naggar AK, Lee YY, Rao B, Fornage B, Terry NHA, et al. Can we detect or predict the presence of occult nodal metastases in patients with squamous carcinoma of the oral tongue? *Head Neck*. 1998;20(2):138–144. Available from: [https://dx.doi.org/10.1002/\(sici\)1097-0347\(199803\)](https://dx.doi.org/10.1002/(sici)1097-0347(199803)).
4. Warnakulasuriya S. Global epidemiology of oral and oropharyngeal cancer. *Oral Oncology*. 2009;45(4-5):309–316. Available from: <https://dx.doi.org/10.1016/j.oraloncology.2008.06.002>.
5. Ren ZH, Wu HJ, Tan HY, Wang K, Zhang S. Transfer of anterolateral thigh flaps in elderly oral cancer patients: complications in oral and maxillofacial reconstruction. *J Oral Maxillofac Surg*. 2015;73:534–574. Available from: <https://doi.org/10.1016/j.joms.2014.09.021>.
6. Bocca E, Pignatarao O, Oidini C. Functional neck dissection: an evaluation of 853 cases. *Laryngoscope*. 1984;94:942–947. Available from: <https://doi.org/10.1288/00005537-198407000-00015>.
7. Byers RM. Modified neck dissection: a study of 967 cases from 1970 to 1980. *Am J Surg*. 1985;150:414–435. Available from: [https://doi.org/10.1016/0002-9610\(85\)90146-1](https://doi.org/10.1016/0002-9610(85)90146-1).
8. Shah JP. Patterns of cervical lymph node metastasis from squamous carcinomas of the upper aerodigestive tract. *Am J Surg*. 1990;160:405–414.
9. Tytor M, Olofsson J. Prognostic Factors in Oral Cavity Carcinomas. *Acta Otolaryngol Suppl*. 1992;492:75–78. Available from: <https://dx.doi.org/10.3109/00016489209136815>.
10. Merritt RM, Williams MF, James TH, Porubsky ES. Detection of Cervical Metastasis: A Meta-analysis Comparing Computed Tomography With Physical Examination. *Arch Otolaryngol Head Neck Surg*. 1997;123(2):149–152. Available from: <https://dx.doi.org/10.1001/archotol.1997.01900020027004>.
11. Stuckensen T, Kovács AF, Adams S, Baum RP. Staging of the neck in patients with oral cavity squamous cell carcinomas: a prospective comparison of PET, ultrasound, CT and MRI. *J Craniomaxillofac Surg*. 2000;28(6):319–324. Available from: <https://dx.doi.org/10.1054/jcms.2000.0172>.
12. Fakhri AR, Rao RS, Borges AM, Patel AR. Elective versus therapeutic neck dissection in early carcinoma of the oral tongue. *Am J Surg*. 1989;158(4):309–313. Available from: [https://dx.doi.org/10.1016/0002-9610\(89\)90122-0](https://dx.doi.org/10.1016/0002-9610(89)90122-0).
13. Kligerman J, Lima RA, Soares JR, Prado L, Dias FL, Freitas EQ, et al. Supraomohyoid neck dissection in the treatment of T1/T2 squamous cell carcinoma of oral cavity. *Am J Surg*. 1994;168(5):391–394. Available from: [https://dx.doi.org/10.1016/s0002-9610\(05\)80082-0](https://dx.doi.org/10.1016/s0002-9610(05)80082-0).
14. Mohit-Tabatabai MA, Sobel HJ, Rush BF, Mashberg A. Relation of thickness of floor of mouth stage I and II cancers to regional metastasis. *Am J Surg*. 1986;152(4):351–353. Available from: [https://dx.doi.org/10.1016/0002-9610\(86\)90303-x](https://dx.doi.org/10.1016/0002-9610(86)90303-x).
15. Urist MM, O'Brien CJ, Soong SJ, Visscher DW, Maddox WA. Squamous cell carcinoma of the buccal mucosa: Analysis of prognostic factors. *Am J Surg*. 1987;154(4):411–414. Available from: [https://dx.doi.org/10.1016/0002-9610\(89\)90014-7](https://dx.doi.org/10.1016/0002-9610(89)90014-7).

Copyright: © the author(s), 2020. It is an open-access article distributed under the terms of the Creative Commons Attribution License (CC BY 4.0), which permits authors to retain ownership of the copyright for their content, and allow anyone to download, reuse, reprint, modify, distribute and/or copy the content as long as the original authors and source are cited.

How to cite this article: Hari K, Srikanth CN. Role of Prophylactic Neck Dissection in Node Negative Carcinoma of Tongue. *Acad. J Surg*. 2020;3(2):59-62.

DOI: dx.doi.org/10.47008/ajs/2020.3.2.15

Source of Support: Nil, **Conflict of Interest:** None declared.