

Assessment of Single Incision Laparoscopic Assisted Appendectomy Cases

C. Asha¹, S. Vijay Kumar²

¹Associate Professor, Department of General Surgery, Subbaiah Institute of Medical Sciences, Shivamogga, Karnataka, India, ²Professor, Department of General Surgery, Surabhi institute of Medical Sciences, Siddipet, Telangana, India.

Abstract

Background: Acute appendicitis represents the most common indication of emergency nontraumatic abdominal surgery in the world. The present study was conducted to assess the cases of single incision laparoscopic assisted appendectomy. **Subjects & Methods:** The present study was done in Department of General Surgery for a period of one year in a tertiary care hospital among 142 patients of acute appendicitis of both genders underwent single incision laparoscopic assisted appendectomy was performed. This technique was evaluated for operative time, post-operative pain, post-operative length of stay and complication rate. **Results:** Out of 142 patients, males were 80 and females were 62. Common clinical features were abdominal pain in 136, vomiting in 70, constipation/diarrhea in 45 and anorexia in 59 cases. The mean age of the patients was 45.6 years, post-operative pain (VAS) after 12 hours was 6.2, after 1 day was 4 and after 2 days was 1.4. The difference was significant ($P < 0.05$). Mean hospital stay was 1.4 days. **Conclusion:** Single incision laparoscopic assisted appendectomy found to be effective in cases of appendicitis with less post-operative pain.

Keywords: Telangana

Corresponding Author: S. Vijay Kumar, Professor, Department of General Surgery, Surabhi institute of Medical Sciences, Siddipet, Telangana, India.

E-mail: drvijaykumarsura@gmail.com

Received: 3 August 2020

Revised: 11 September 2020

Accepted: 18 September 2020

Published: 31 December 2020

Introduction

Acute appendicitis is the most common condition which leads to emergency abdominal surgeries in young adults. Acute appendicitis represents the most common indication of emergency nontraumatic abdominal surgery in the world.^[1] This pathological process occurs more frequently between the second and third decades of life. The risk of presenting it is 16.33% in men and 16.34% in women. Its annual incidence is 139.54 per 100,000 habitants; in 18.5% it is associated with overweight and in 81.5% with obesity.^[2]

The central pathogenic event of acute appendicitis is obstruction of the appendicular lumen, which may be secondary to fecaliths, lymphoid hyperplasia, foreign bodies, parasites, primary tumors (carcinoid, adenocarcinoma, Kaposi's sarcoma, lymphoma, etc.) or metastatic tumors (colon and breast). Inflammation of the appendicular wall is the initial phenomenon, vascular congestion, ischemia, perforation and, occasionally, development of localized (contained) abscesses or generalized peritonitis ensue later. During these phenomena, bacterial proliferation occurs, in the early course of the

disease, aerobic microorganisms appear and later, mixed forms (aerobic and anaerobic) appear.^[3]

In a classic LA or LAA, three to four incisions are required for the placement of multiple trocars. Driven by a quest towards less abdominal trauma, improved cosmesis, reductions in postoperative pain and hospital stay, technique of Single Incision Laparoscopic Surgery (SILS) has been developed. SILS is one of the recent advances made in the field of Minimal Access Surgery (MAS). Again, SILS appendectomy includes disadvantages of laparoscopic appendectomy.^[4] To combine the advantages of SILS and LAA and to reduce their disadvantages, Single Incision Laparoscopic Assisted Appendectomy (SILAA) has been introduced. Most of the authors have described SILS assisted appendectomies done with umbilical approaches in children.^[5] The present study was conducted to assess the cases of single incision laparoscopic assisted appendectomy.

Subjects and Methods

The present study was done in Department of General Surgery for a period of one year in a tertiary care hospital among 142 patients of acute appendicitis of both genders. All were informed regarding the study and their written consent was obtained. Institutional ethics committee approval obtained for the study.

Data such as name, age, gender etc. was recorded. In all patients, single incision laparoscopic assisted appendectomy was performed. This technique was evaluated for operative time, post-operative pain, post-operative length of stay and complication rate. Post-operative pain was evaluated at 12 hrs, day 1 and day 2 post-operatively by using a visual analogue scale (VAS) which ranged from 0 to 10. Results were statistically analyzed P value less than 0.05 was considered significant.

Results

Table 1: Distribution of patients

Total- 142		
Gender	Males	Females
Number	80	62

[Table 1] shows that out of 142 patients, males were 80 and females were 62.

Table 2: Clinical features

Parameters	Number	P-value
Abdominal pain	136	0.04
Vomiting	70	
Constipation/ diarrhea	45	
Anorexia	59	

[Table 2] shows that common clinical features were abdominal pain in 136, vomiting in 70, constipation/diarrhea in 45 and anorexia in 59 cases. The difference was significant (P< 0.05).

Table 3: Assessment of parameters

Parameters	Value	P-value
Age (mean) years	45.6	-
Post- operative pain		
After 12 hours	6.2	0.01
1 day	4.0	
2 days	1.2	
Hospital stay (Mean)	1.4	-

[Table 3 & Figure 1] shows that mean age of the patients was 45.6 years, post-operative pain (VAS) after 12 hours was 6.2, after 1 day was 4 and after 2 days was 1.4. The difference was significant (P< 0.05). Mean hospital stay was 1.4 days.

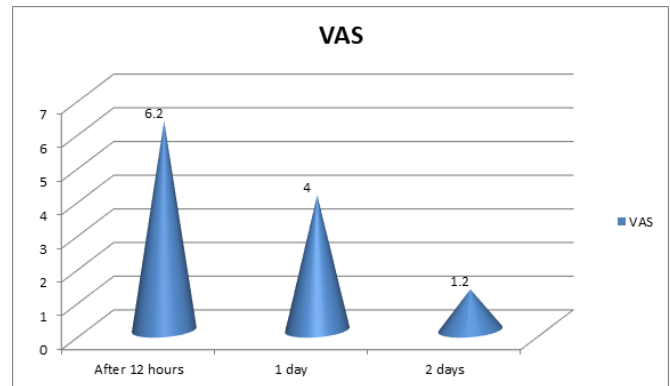


Figure 1: Assessment of parameters

Discussion

Abdominal pain is the most frequent symptom that occurs in patients, although other symptoms such as anorexia, nausea, constipation/diarrhea and fever are also described.^[6] Pain is typically periumbilical and epigastric, and later migrates to the lower right quadrant; however, despite being considered a classic symptom, migratory pain occurs only in 50 to 60% of patients with acute appendicitis.^[7] The appearance of nausea and vomiting occurs after the installation of pain, and fever usually manifests around six hours after the general clinical picture. This varies considerably from person to person, which in some cases is attributable to the location of the tip of the appendix.^[8] For example, an anteriorly located appendix produces marked and localized pain in the right lower quadrant, whereas a retro-cecal one can cause dull abdominal pain or pain in the lower lumbar region. Likewise, due to the irritation produced by the appendix, other symptoms such as urinary urgency, dysuria or rectal symptoms such as tenesmus or diarrhea may appear.^[9] The present study was conducted to assess the cases of single incision laparoscopic assisted appendectomy.

In present study, out of 142 patients, males were 80 and females were 62. We found that common clinical features were abdominal pain in 136, vomiting in 70, constipation/diarrhea in 45 and anorexia in 59 cases. Kumar et al,^[10] in their study single incision laparoscopic assisted appendectomy was done in 82 patients who were diagnosed with acute or chronic appendicitis. A single 10 mm incision made over right lower quadrant was used for placing two 5 mm trocars and appendectomy was done as in open surgery, after delivering

out the appendix from the incision. Mean operative time was 32.56 ± 15.5 minutes. Mean post-operative pain scores as per visual analogue scale were 6.5, 4.2 and 1.2 on 12 hours day 1 and day 2 after surgery respectively. Mean length of hospital stay was 1.4 ± 1.2 days.

We found that mean age of the patients was 45.6 years, post-operative pain (VAS) after 12 hours was 6.2, after 1 day was 4 and after 2 days was 1.4. The difference was significant ($P < 0.05$). Mean hospital stay was 1.4 days. Single Incision Laparoscopic Surgery (SILS) is a new technique that is now being utilized at many centres for doing appendectomies. The major difficulty faced with this new technique is the sacrifice that has to be made in terms of comfort and ergonomics.^[11] As all instruments and camera are inserted through the same incision, the ability to triangulate the instruments around the target is lost. Although this can be partially rectified by the use of rotator instruments, surgeon ends up working with his/her hands held very close together, and he/she often finds himself/herself being impeded by the laparoscope and the assistant. Similarly, the surgeon's right hand will control the left-sided instrument on the screen and his/her left hand will control the right-sided instrument on screen. These technical difficulties do make SILS a more demanding procedure on the operating surgeon than normal laparoscopic techniques.^[12]

The shortcoming of the study is small sample size.

Conclusion

Authors found that single incision laparoscopic assisted appendectomy found to be effective in cases of appendicitis with less post-operative pain.

References

- Meljnikov I, Radojic B, Grebeldinger S, Radojic N. History of surgical treatment of appendicitis. *Med Pregl*. 2009;62(9):489–92.
- Laine S, Rantala A, Gullichsen R, Ovaska J. Laparoscopic appendectomy - is it worthwhile: a prospective randomized study in young women. *Surg Endosc*. 1997;11(2):95–97. Available from: <https://doi.org/10.1007/s004649900305>.
- Garbutt JM, Soper NJ, Shannon WD, Botero A, Littenberg B. Meta-analysis of randomized controlled trials comparing laparoscopic and open appendectomy. *Surg Laparosc Endosc*. 1999;9(1):17–26.
- Fallahzadeh H. Should a laparoscopic appendectomy be done? *Am Surg*. 1998;64(3):231–264.
- Anders Kald BAM Eric Kullman. Cost-minimisation Analysis of Laparoscopic and Open Appendectomy. *Eur J Surg*. 1999;165(6):579–582. Available from: <https://dx.doi.org/10.1080/110241599750006497>.
- Katkhouda N, Mason RJ, Mavor E. Two-trocar laparoscopic-assisted appendectomy versus conventional laparoscopic appendectomy in patients with acute appendicitis. *J Laparoendosc Adv Surg Tech A*. 1999;189(1):27–32. Available from: <https://doi.org/10.1089/lap.2006.16.27>.
- Konstadoulakis MM, Gomatos IP, Antonakis PT, Manouras A, Albanopoulos K, Nikiteas N, et al. Two-Trocar Laparoscopic-Assisted Appendectomy Versus Conventional Laparoscopic Appendectomy in Patients with Acute Appendicitis. *J Laparoendosc Adv Surg Tech A*. 2006;16(1):27–32. Available from: <https://dx.doi.org/10.1089/lap.2006.16.27>.
- Nicholson T, Tiruchelvam V. Comparison of Laparoscopic-Assisted Appendectomy with Intracorporeal Laparoscopic Appendectomy and Open Appendectomy. *JLSV*. 2001;5(1):47–51.
- Li P, Chen ZH, Li QG, Qiao T, Tian YY, Wang DR. Safety and efficacy of single-incision laparoscopic surgery for appendectomies: A meta-analysis. *World J Gastroenterol*. 2013;19(25):4072–4082. Available from: <https://doi.org/10.3748/wjg.v19.i25.4072>.
- Kumar A, Sinha AN, Deepak D, Pandey NK. Single incision laparoscopic assisted appendectomy: experience of 82 cases. *J Clin Diagn Res*. 2016;10(5):1–3. Available from: <https://doi.org/10.7860/jcdr/2016/8146.7775>.
- Nazzal M, Ali MA, Turfah F, Kaidi A, Saba A, Pleatman M, et al. Laparoscopic Appendectomy: A Viable Alternative Approach. *J Laparoendosc Adv Surg Tech A*. 1997;7(1):1–6. Available from: <https://doi.org/10.1089/lap.1997.7.1>.
- Bhangu A, Søreide K, Saverio SD, Assarsson JH, Drake FT. Acute appendicitis: modern understanding of pathogenesis, diagnosis, and management. *Lancet*. 2015;386(10000):1278–1287. Available from: [https://dx.doi.org/10.1016/s0140-6736\(15\)00275-5](https://dx.doi.org/10.1016/s0140-6736(15)00275-5).

Copyright: © the author(s), 2020. It is an open-access article distributed under the terms of the Creative Commons Attribution License (CC BY 4.0), which permits authors to retain ownership of the copyright for their content, and allow anyone to download, reuse, reprint, modify, distribute and/or copy the content as long as the original authors and source are cited.

How to cite this article: Asha C, Kumar SV. Assessment of Single Incision Laparoscopic Assisted Appendectomy Cases. *Acad. J Surg*. 2020;3(2):56-58.

DOI: dx.doi.org/10.47008/ajs/2020.3.2.14

Source of Support: Nil, **Conflict of Interest:** None declared.