

Single Center Experience of Laparoscopic Management of Pediatric Gall Stone Disease

Samir Kant Acharya¹, Deepak Bagga², Ajay Verma³, Brajesh Ranjan⁴

¹Associate Professor & Head, Department of Pediatric Surgery, Vardhman Mahaveer Medical College & Safdarjung Hospital, New Delhi, India, ²Professor, Department of Pediatric Surgery, Vardhman Mahaveer Medical College & Safdarjung Hospital, New Delhi, India, ³Assistant Professor, Department of Pediatric Surgery, All India Institute of Medical Sciences, New Delhi, India, ⁴Assistant Professor, Department of Anatomy, Government Allopathic Medical College, Banda, Uttar Pradesh, India.

Abstract

Background: The aim of this retrospective study is to analyze the result of pediatric gall stone disease at a large volume single center. **Subjects and Methods:** This is a retrospective study, where patients operated at a single center between August 2007 to August 2020 were evaluated for presenting clinical features, cause of gall stone disease, surgery performed, intra op & post op complications and outcome at the time of discharge from hospital from clinical case files. **Results:** Total 253 patients underwent laparoscopic cholecystectomy between August 2007 and August 2020. Three patients were converted to open due to complications and were removed from the final analysis. Age distribution was 3 years to 12 years. Pain abdomen was most common feature as a clinical presentation. Hemolytic anemia was documented in only 10 patients. Twenty five patients were obese with BMI > 2SD. Standard 4 port laparoscopic cholecystectomy was done in all the patients. Stone was absent in 32 cases and only sludge was found on gross examination, twenty two cases has single stone & rest had multiple stone. Duration of surgery was 30 minutes to 45 minutes with median of 35 minutes. Two patients out of 250 had CBD injury. All patients were discharged within 7 days of surgery. **Conclusion:** Gall stone disease is increasingly common in patient presenting with repeated pain abdomen. Hemolytic anemia is not a common cause of pediatric gall stone disease. Laparoscopy is well tolerated in children with very few complications in experienced hands.

Keywords: Gall stone disease, GSD, Pediatric, Laparoscopy.

Corresponding Author: Brajesh Ranjan, Assistant Professor, Department of Anatomy, Government Allopathic Medical College, Banda, Uttar Pradesh, India.

E-mail: drbrajeshranjan@gmail.com

Received: 10 October 2020

Revised: 24 November 2020

Accepted: 02 December 2020

Published: 30 December 2020

Introduction

Laparoscopic cholecystectomy (LC) is currently considered the standard of care for managing gallstone disease. The worldwide acceptance of LC is mainly due to lower postoperative wound complaints, faster recovery, better postoperative cosmetic results, shorter hospital stay, and earlier return to work. Although numerous studies have been published addressing both the advantages and complications of LC in acute cholecystitis, there is still limited information concerning the safety and efficacy of LC in the management of acute cholecystitis for sickle cell disease (SCD) pediatric patients, and controversies remain unresolved.

Subjects and Methods

This is a retrospective study, where patients operated at a single large volume center between August 2007 to August 2020 were evaluated. These were identified from clinical

records, and their medical files were examined. Patients aged 3–12 years with calculi causing an acoustic shadow in the gall bladder determined at ultrasonography were included in the study. Patients were evaluated in terms of age, sex, presentation symptoms, body mass index, accompanying diseases, family history of gallstones, history of prolonged drug use, laboratory tests, ultrasonographic findings and results. Complete blood count, reticulocyte, peripheral smear, direct Coombs, osmotic fragility, transaminases, γ -glutamyl transferase, total protein, albumin, total-direct bilirubin, and lipid profile results for etiology were recorded from the file. Intra operative findings and post-operative complications were noted from clinical case records.

Results

Total 309 patients presented to us with diagnosis of GB calculi based on USG examination out of which 253 patients

underwent laparoscopic cholecystectomy between August 2007 and August 2020. Three patients were converted to open due to intra operative complications and were removed from the final analysis. One child had bleeding which was converted to open and other two had difficulty in identification of anatomical landmarks so were converted to open. Age distribution was 3 years to 12 years. There was no significant difference between number of male & female children, pain abdomen was most common feature as a clinical presentation (n=180), other presentation was jaundice(n=2) and nausea (n=15). Children were evaluated to know the cause of GB calculi and we found that hemolytic anemia was present in 10 patients. [Table 1] Twenty-five patients were obese with BMI > 2SD. Standard 4 port laparoscopic cholecystectomy was done in all the patients. Stone was replaced by sludge in 32 cases, 22 cases has single stone & rest had multiple stone. Duration of surgery was 30 minutes to 45 minutes with median of 35 minutes. Two patients out of 250 had CBD injury and were managed by open roux en-Y hepatico-jejunostomy in the same admission. All patients who underwent uneventful laparoscopic cholecystectomy were discharged within 7 days of surgery.

Table 1: Patients with hemolytic anemia

Sickle cell anemia	2 (two)
Thalassemia major	6 (six)
Hereditary spherocytosis	2 (two)

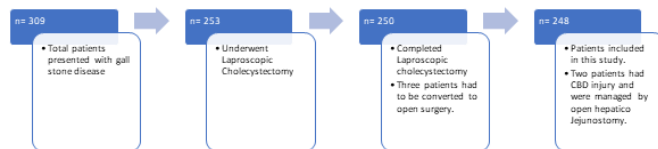


Figure 1: Plan of study.

Discussion

The epidemiology of cholelithiasis in children has been less explored and still has un-answered questions. Cholelithiasis was considered to be uncommon in young infants and small children but have been increasingly diagnosed in recent years due to wide- spread use of ultrasonography.^[1] However, there is not much of information from India and no consensus among Indian pediatricians and pediatric surgeons regarding management of gallstones in children. The sex ratio of cholelithiasis was equal. Only in the adolescent group (14–18 years) was there a female predilection for gallstones. This may correspond with the time at which cholesterol saturation in bile

increases, preceding the development of cholesterol-related gallstones.^[2,3] Obesity, ileal disease, and a family history of childhood gallstones are factors associated with cholelithiasis in elderly children. Similar to the influence of puberty in female adolescents, obesity, ileal disease and a family history are known risk factors for development of cholesterol-related gallstones in adolescence. In contrast to other reports, chronic hemolysis was not the most common predisposing factor for cholelithiasis in our series. This probably explains why gallstones found in children are predominantly mixed stones. Feeding by TPN as a risk factor for biliary stones was not noted in this study. Only 4% of our patients had hemolytic disease related gallstones, which is less than described in previous reports.^[4,5]

A number of studies have examined the role of defective gallbladder motility (that is, increased fasting and postprandial gallbladder volumes and slower postprandial emptying in response to meal) as a major risk factor for cholesterol gallstone formation. Indeed, intraluminal gallbladder stasis provides a sufficiently prolonged time for nucleation of excess biliary cholesterol and gallstone growth but is this mechanism of gall stone formation the primary pathophysiology behind the gall stone disease in children is a matter of further study.

In this present study the total stay in the hospital was comparable to the other adult studies and the complication rate was also not high. Since this is a retrospective study done in children presenting to a surgical facility, the prevalence of gall stone disease in children with hemolytic anemia can not be extrapolated; however, we do want to emphasize that the incidence of gall stone disease in patients with hemolytic anemia is quite low in Indian population as compared to the available literature.

Conclusion

Gall stone disease is increasingly common in patient presenting with repeated pain abdomen. Hemolytic anemia is not a common cause of pediatric gall stone disease. Laparoscopy is well tolerated in children with very few complications in experienced hands.

References

1. Poddar U. Gallstone disease in children. Indian Pediatr. 2010;47:945–953. Available from: <https://dx.doi.org/10.1007/s13312-010-0159-2>.
2. Gilger MA. Cholelithiasis and cholecystitis. Co PGDWBS, editor; 1993.
3. Janowitz P, Kratzer W, Zemmler T, Tudyka J, Wechsler JG. Gallbladder sludge: Spontaneous course and incidence of complications in patients without stones. Hepatology. 1994;20(2):291–294. Available from: <https://dx.doi.org/10.1002/hep.1840200204>.

4. Serdaroglu F, Koca YS, Fatmaa S, Koca T, Dereci S, Akcam M, et al. Gallstones in childhood: etiology, clinical features, and prognosis. *Eur J Gastroenterol Hepatol* . 2016;28(12):1468–1472. Available from: <https://doi.org/10.1097/meg.0000000000000726>.
5. Gökçe S, Yıldırım M, Erdoğan D. A retrospective review of children with gallstone: single-center experience from Central Anatolia. *Turk J Gastroenterol*. 2014;25(1):46–53. Available from: <https://doi.org/10.5152/tjg.2014.3907>.

Copyright: © the author(s), 2020. It is an open-access article distributed under the terms of the Creative Commons Attribution License (CC BY 4.0), which permits authors to retain ownership of the copyright for their content, and allow anyone to download, reuse, reprint, modify, distribute and/or copy the content as long as the original authors and source are cited.

How to cite this article: Acharya SK, Bagga D, Verma A, Ranjan B. Single Center Experience of Laparoscopic Management of Pediatric Gall Stone Disease. *Acad. J Surg*. 2020;3(2):49-51.

DOI: [dx.doi.org/10.47008/ajs/2020.3.2.12](https://doi.org/10.47008/ajs/2020.3.2.12)

Source of Support: Nil, **Conflict of Interest:** None declared.