

Comparative Evaluation of Open and Laproscopic Method of Appendectomy in Acute Appendicitis

Amarnath Gupta¹, Awdesh Prasad Singh²

¹Senior Resident, Department of General Surgery, Government Medical College, Bettiah, Bihar, India, ²Professor & HOD, Department of General Surgery, Government Medical College, Bettiah, Bihar, India.

Abstract

Background: There is definitely added advantage of laparoscopic operations. Most of the surgeons now prefer these minimally invasive procedures. Laparoscopy has become the number one choice of educated and affording patients. The aim of the study was to compare and evaluate the open and laproscopic method of appendectomy in acute appendicitis. **Subjects and Methods:** The subjects undergoing appendectomy were evaluated for age, sex, episode number, duration of pain before presentation in hospital, operative time, conversion rate, wound infection, post-operative intra-abdominal abscess formation, and stay in hospital. **Results:** It was found that average operative time in open surgery was 67.5 minutes and 104 minutes in laparoscopic surgery, with a conversion to open in about 20% of the cases. Oral feeding in the open group was around the 5th day while it was around 2nd day in the laparoscopic group. Average hospital stay was also low in the laparoscopic group, being only around 5 days in laparoscopic group and around 8 days in the open group. Overall complications were also low in the laparoscopic surgery group. **Conclusion:** It was noted that though conversion to open operation was definitely high but there were other advantages of laparoscopic surgery as well. Stay in the hospital, beginning of oral feeds, requirement of analgesics, wound infection, intra-abdominal abscess; pulmonary complications were less in laparoscopy group.

Keywords: Appendectomy, Open vs laparoscopic appendectomy

Corresponding Author: Amarnath Gupta, Senior Resident, Department of General Surgery, Government Medical College, Bettiah, Bihar, India. E-mail: amarpmch@gmail.com

Received: 20 December 2019

Revised: 22 January 2020

Accepted: 27 January 2020

Published: 26 May 2020

Introduction

In present era of minimal access surgery most of the surgeons are very well trained in laparoscopic surgical maneuvers in hepatobiliary, resection-anastomoses of gut, anal surgeries, thoracic and urological operations. The surgeons have now started doing more complex operations due to increased sophistication, availability of good quality of instruments and growing surgical experience.^[1-4] These things have also improved the final outcome of any kind of surgery simple or complicated. There is definitely added advantage of laparoscopic operations in the form of lesser hospital stay, lesser wound infection, early work resumption, lesser pain and agony to patients. In obese patients the time taken for operations is more but there are fewer complications with minimal access surgery as compared to open procedures. Even in first trimester of pregnancy laparoscopic appendectomy and other operations are safer with laparoscopy.^[5-8] Most of the surgeons now prefer these minimally invasive procedures. Laparoscopy has become the number one choice of educated

and affording patients.

Acute appendicitis has many complications at the time of presentation because of waiting for spontaneous recovery, delay in diagnosis by peripheral health care workers or reluctance of patients for undergoing operation due to financial constraints.^[9-12] The diagnosis of acute appendicitis may be straight forward or difficult in some situations. The diagnosis of acute appendicitis and its complications can be done easily with surety.

The aim of the study was to compare and evaluate the open and laproscopic method of appendectomy in Acute appendicitis.

Subjects and Methods

This prospective study was conducted at Government Medical College (GMC), Bettiah. The study was approved by the institutional research committee. The study sample consisted of eighty-one patients of Acute appendix that reported to the department of general surgery at our hospital from January

2018 to June 2019. Twenty nine patients were operated laparoscopically and fifty two cases were operated with open approach. Pre-operative diagnosis was established by clinical examination, blood investigations and radiological findings and was confirmed intra-operatively.

The parameters studied were age of the patients, sex, episode number, duration of pain before presentation in hospital, operative time, conversion rate, wound infection, post-operative intra- abdominal abscess formation, and stay in hospital. Subjects with appendicular mass, peritonitis or intestinal obstruction were not included in the study. Multiport method for appendicular perforation was followed for the laparoscopic appendectomy. The open surgical appendectomy was started with Rutherford Morison muscle incision for easy approach.

All patients received preoperative antibiotics a third generation cephalosporin, IV fluids, analgesics. Antibiotics were given intravenously for three days and orally for five days' post operatively. Oral intake allowed gradually and all the patients were fully oral on fourth or fifth postoperative day. All the patients were mobilized on the third or fourth postoperative day. Patients were discharged on seventh post-operative day after removal of stitches. Complications of the procedure were noted during hospital stay. Patients were followed weekly in first month, fortnightly for two months and monthly for six months. Some of the patients did not complete the full follow up period and were absent after few visits.

Results

Analysis of variables like age, sex, operative time, amount of analgesics used, and hospital stay was done. Complications noted were wound infection, intra-abdominal abscess formation and post- operative ileus. The other parameters studied were episode number, duration of pain before presentation in hospital and conversion rate.

Out of eighty-one complicated cases of acute appendicitis most of the patients were young and had good physical health. There was slight dominance of female over male patients. The sequence number of clinical episode of appendicitis in our series was noted as first and second. With more episodes the appendix becomes fibrosed and less vulnerable to infection and inflammation. Pain was present for four to five days before coming to hospital. Pulse, temperature, respiratory rate, mild abdominal distension and guarding were present in almost all cases and were related to duration of pain. Late reporting to hospital was due late referral and financial constraints. All these above factors were common in both groups.

The Operative time for Open Surgery 52-83 min, 67.5 mins. The same for the Laparoscopic surgery: ranged from 81-127 min with an average time of 104 mins. Of the 29 subjects

operated using laparoscopic method 6 subjects were converted to open method during the surgery. This criteria was not applicable to the remaining 52 cases that had undergone open method. The open surgical patients resumed to oral feed on the 5th Post-operative day, while the laparoscopic group subjects resumed to the oral feed on the 2nd Post-operative day. The Laparoscopy group subjects were discharged on 5th post-operative day while the Open group subjects were discharged on 8th post-operative day. [Table 1]

In the open method group 23 subjects faced post-operative complication in terms of wound infection and 2 subjects suffered intra-abdominal abscess. The number of subjects suffering wound infection and intra-abdominal abscess in laparoscopic method was 6 and 2 respectively. [Figure 1 & 2]

Table 1: Open vs. laparoscopic surgery.

Variables	Average operative time	Conversion rate	Oral feed started post operatively (average)	Average hospital stay
Open surgery	67.5 minutes	N/A	Post-operative day: 5	8 days
Laparoscopic surgery	104 minutes	6/29 = 20%	Post-operative day: 2	5 days

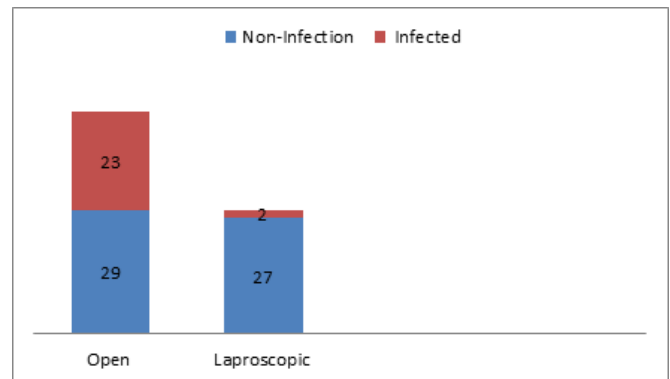


Figure 1: Wound Infection in Open and Laparoscopic group

In open group we have to use analgesics more frequently. The analgesics used were diclofenac sodium and tramadol. No other strong opioids were needed. The incidence of prolonged ileus was more in laparoscopy group (2/29 Vs 1/52) most likely due to pneumoperitoneum. No other complications occurred in this series.

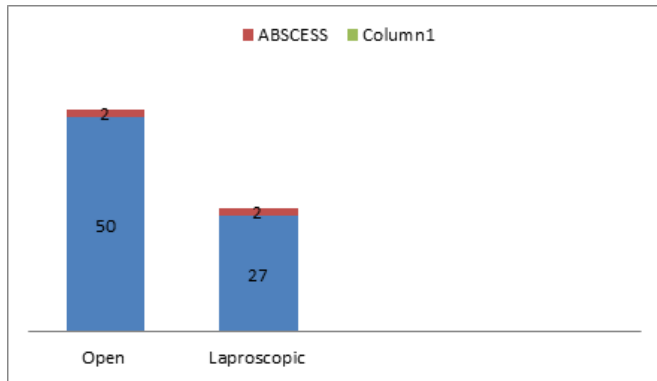


Figure 2: Wound Abscess in Open and Laparoscopic group

Discussion

Our study is not based on a large sample size but we can find some trend. Operative time was a little more in laparoscopic appendectomy. It was about thirty minutes more. Conversion to open operation was definitely high though there were other advantages of laparoscopic surgery. Stay in the hospital, beginning of oral feeds, wound infection, intra-abdominal abscess; pulmonary complications were less in laparoscopy group. A study by Yau K et al, where a similar comparative study in 1,133 patients was done showed 42 patients with complicated appendicitis.^[13] The mean hospital stay was 5 days in the Laparoscopic group which was the same in our study whereas the study had an average hospital stay of 6 days as opposed to 8 days in our open surgery group. Another study by Pokala N in which a total of 104 patients were studied, 43 underwent laparoscopic and 61 underwent open surgeries.^[14] There was a slight predominance in number of females as was seen in our study. The conversion rate in the study was 18.6% which was quite similar and around 20% in our study. Overall complications rate was higher in Laparoscopic group than in open group. Another study by Garg CP which studied a total of 110 patients, 61 of whom underwent open appendectomy and the rest 49 underwent Laparoscopic appendectomy.^[15] Operative time was noted to be higher in laparoscopic surgery as was in our study, also it was noted that laparoscopic surgery was associated with less analgesic use, shorter hospital stay. Thus it can be noted that laparoscopic surgery for complicated appendicitis is safe and feasible. It has less postoperative pain, lower infectious complications and short hospital stay when compared with patients who had an open surgery.

Conclusion

It was noted that though conversion to open operation was definitely high but there were other advantages of laparoscopic

surgery as well. Stay in the hospital, beginning of oral feeds, requirement of analgesics, wound infection, intra-abdominal abscess; pulmonary complications were less in laparoscopy group.

References

- Ponnusamy K, Mohr C, Curet MJ. Clinical outcomes with robotic surgery. *Curr Probl Surg.* 2011;48(9):577–656. doi:10.1067/j.cpsurg.2011.05.002.
- Dobbs TD, Cundy O, Samarendra H, Khan K, Whitaker IS. A Systematic Review of the Role of Robotics in Plastic and Reconstructive Surgery-From Inception to the Future. *Front Surg.* 2017;15(4):66–66. doi:10.3389/fsurg.2017.00066. eCollection 2017.
- Yau KK, Siu WT, Tang CN, Yang GPC, Li MKW. Laparoscopic Versus Open Appendectomy for Complicated Appendicitis. *J Am Coll Surg.* 2007;205(1):60–65. Available from: <https://dx.doi.org/10.1016/j.jamcollsurg.2007.03.017>. doi:10.1016/j.jamcollsurg.2007.03.017.
- Pokala N, Sadhasivam S, Kiran RP, Parithivel V. Complicated Appendicitis-Is the Laparoscopic Approach Appropriate? A Comparative Study with the Open Approach: Outcome in a Community Hospital Setting. *Am Surg.* 2007;73(8):737–742. Available from: <https://dx.doi.org/10.1177/000313480707300801>. doi:10.1177/000313480707300801.
- Garg CP, Vaidya BB, Chengalath MM. Efficacy of laparoscopy in complicated appendicitis. *Int J Surg.* 2009;7(3):250–252. Available from: <https://dx.doi.org/10.1016/j.ijsu.2009.04.007>. doi:10.1016/j.ijsu.2009.04.007.
- Beldi G, Vorburger SA, Bruegger LE, Kocher T, Inderbitzin D, and DC. Analysis of stapling versus endoloops in appendiceal stump closure. *Br J Surg.* 2006;93(11):1390–1393. Available from: <https://dx.doi.org/10.1002/bjs.5474>. doi:10.1002/bjs.5474.
- Sahm M, Kube R, Schmidt S, Ritter C, Pross M, Lippert H. Current analysis of endoloops in appendiceal stump closure. *Surg Endosc.* 2011;25(1):124–129. Available from: <https://dx.doi.org/10.1007/s00464-010-1144-5>. doi:10.1007/s00464-010-1144-5.
- Ohno Y, Furui J, Kanematsu T. Treatment strategy when using intraoperative peritoneal lavage for perforated appendicitis in children: a preliminary report. *Pediatr Surg Int.* 2004;20(7):534–541. Available from: <https://dx.doi.org/10.1007/s00383-004-1210-y>. doi:10.1007/s00383-004-1210-y.
- Agresta F, Ansoloni L, Baiocchi GL, Bergamini C, Campanile FC, Carlucci M. Laparoscopic approach to acute abdomen from the Consensus Development Conference of the Societa Italiana di Chirurgia Endoscopica. *Surg Endosc.* 2012;26:2134–64.
- Moore CB, Smith RS, Herbertson R, Toevs C. Does Use of Intraoperative Irrigation with Open or Laparoscopic Appendectomy Reduce Post-Operative Intra-abdominal Abscess? *Am Surg.* 2011;77(1):78–80. Available from: <https://dx.doi.org/10.1177/000313481107700126>. doi:10.1177/000313481107700126.

11. Peter SDS, Adibe OO, Iqbal CW, Fike FB, Sharp SW, Juang D, et al. Irrigation Versus Suction Alone During Laparoscopic Appendectomy for Perforated Appendicitis. *Ann Surg.* 2012;256(4):581–585. Available from: <https://dx.doi.org/10.1097/sla.0b013e31826a91e5>. doi:10.1097/sla.0b013e31826a91e5.
12. Schein M. To drain or not to drain? The role of drainage in the contaminated and infected abdomen: an international and personal perspective. *World J Surg.* 2008;138:314–338.
13. Pessaux P, Msika S, Atalla D, Hay JM, Flammant Y. Risk factors for postoperative infectious complication in noncolorectal abdominal surgery : a multivariate analysis based on a prospective multicenter study of 4718 patients. *Arch Surg.* 2003;138:314–338.
14. Sleem R, Fisher S, Gestring M, Cheng J, Sangosanya A, Stassen N, et al. Perforated appendicitis: Is early laparoscopic appendectomy appropriate? *Surgery.* 2009;146(4):731–738. Available from: <https://dx.doi.org/10.1016/j.surg.2009.06.053>. doi:10.1016/j.surg.2009.06.053.
15. Masoomi H, Mills S, Dolich MO, Ketana N, Carmichael JC, Nuguen NT. Comparison of outcomes of laparoscopic versus open appendectomy in adults. *J Gastrointest Surg.* 2006;15:2226–2257.

Copyright: © the author(s), 2020. It is an open-access article distributed under the terms of the Creative Commons Attribution License (CC BY 4.0), which permits authors to retain ownership of the copyright for their content, and allow anyone to download, reuse, reprint, modify, distribute and/or copy the content as long as the original authors and source are cited.

How to cite this article: Gupta A, Singh AP. Comparative Evaluation of Open and Laproscopic Method of Appendectomy in Acute Appendicitis. *Acad. J Surg.* 2020;3(1):8-11.

DOI: dx.doi.org/10.47008/ajs/2020.3.1.2

Source of Support: Nil, **Conflict of Interest:** None declared.