

Assessment of Potential of First Trimester Ultrasonography in Detection of Fetal Congenital Structural Malformations- A Retrospective Study

G Rajesh¹, Waseem Akhtar²

¹Associate Professor, Department of Radiology, FH Medical College, Tundla, ²Assistant Professor, Department of Radiology, FH Medical College, Tundla.

Abstract

Background: Early detection of malformation is tremendously improved with improvement in imaging technology. Yet in a developing country like India majority of pregnant women are not privileged to get timely diagnosis. Present study aimed to assess the potential of first trimester ultrasonography in detection of fetal congenital structural malformations. **Subjects and Methods:** All pregnant women had anomaly scan and women with fetal structural malformations were included. All patients were screened for congenital anomalies by 11-14 week ultrasound scan (first trimester anomaly scan) as part of routine prenatal care. Second trimester scan was conducted at 18 to 22 weeks gestation. The results of the first trimester anatomic survey were correlated with second trimester target scan to evaluate value of first trimester scan for early detection of anomalies. **Results:** It showed that out of 924 pregnant women 472 fall under high risk category and 452 under low risk category. Out of 924 women subjected to First Trimester Anomaly Scan 18 patients demonstrated some sort of congenital anomaly whereas Mid Gestation Ultrasound Scan revealed 9 women out of 892 who gave birth to babies with congenital anomaly. Overall only 3% pregnant women revealed congenital anomalies among babies. **Conclusion:** There is immense need for early diagnosis and timely intervention in the field of prenatal detection of congenital malformation. Earlier detection of fetal structural malformations would allow for earlier antenatal referral to a tertiary care facility and coordination of care among appropriate subspecialists. Focus and emphasis should aim at detection of malformation earlier than 12 weeks owing to the very unique and clear facts that first trimester detection leads to easy termination of pregnancy and lessening of women's mental, physical, and psychological trauma.

Keywords: Congenital Anomaly, Ultrasonography.

Corresponding Author: Dr. Waseem Akhtar, Assistant Professor, Department of Radiodiagnosis, FH Medical College, Tundla.

Received: June 2019

Accepted: August 2019

Introduction

Ultrasound is the main screening and diagnostic tool for congenital structural abnormalities. The early pregnancy (first trimester) scan was initially introduced with the primary intention of measuring the fetal crown rump length to achieve accurate pregnancy dating. With growing experience of sonographers and improving equipment, detailed depiction of fetal structures including the fetal heart became possible. With improvement in the resolution of ultrasound machines and wide application of the nuchal translucency (NT) scan, it is possible to delineate normal fetal anatomy and diagnose a wide range of fetal abnormalities in the first trimester.^[1,2]

Fetal structural malformations are seen in 3 to 5% of all pregnancies. Detection of malformation is tremendously improved with improvement in imaging technology. In majority of countries worldwide, second trimester scan between 18 and 22 weeks remains the standard of care for fetal anatomical assessment; however, most recent literature shows a significant improvement in detection of fetal abnormalities in first trimester of pregnancy. Besides nuchal abnormalities a wide range of central nervous system, heart, anterior abdominal wall, urinary tract, and skeletal

abnormalities can be diagnosed between 11 and 14 weeks of scan. The clear benefits of first trimester ultrasound are early detection and exclusion of major congenital anomalies (not compatible with life or followed by severe handicap), reassurance, and relatively easier pregnancy termination if required.^[2-5]

We see a fair number of patients who are diagnosed with fetal malformation beyond 20 weeks and in that situation they are forced to seek termination services at small substandard centres since they get refusals from all relatively good hospitals due to legal issues associated with termination. Many of such patients get deteriorated due to septic abortion and unnecessary hysterotomy and so forth.^[2,5,6] Question then arises that where lies the fault, the awareness of the patients or the expertise of the sonologist. Henceforth, the study was planned to assess the potential of first trimester ultrasonography in detection of fetal congenital structural malformations in a tertiary care centre in India.

Subjects and Methods

This was a retrospective observational study including all pregnant women who underwent ultrasound and those with

fetal structural malformations were evaluated further. Malformations were classified according to gestational age of diagnosis, system involved, and type of malformation. In case of suspicion of anomalies, additional information on referrals to a fetal medicine unit was included, genetic investigations and pathology reports were retrieved from the clinic databases, and the national birth registry and the pathology and clinical genetics department of the tertiary care center were consulted. Descriptive proportions and frequencies have been used to depict the data.

Patients were divided into two groups based on risk associated with pregnancy

High risk pregnancy was defined as any one of the following risk factors

1. Advanced maternal age (>30 years)
2. Previous history of any congenital anomaly or pregnancy loss
3. Family history of structural defects
4. Pregnancy after assisted reproductive techniques
5. Maternal diseases like Diabetes mellitus or Epilepsy
6. Multiple pregnancy
7. History of smoking or alcohol consumption in antenatal period
8. Previous affected child with chromosomal aberration

Low risk pregnancy was defined as a young women <30 years of age and not having the above mentioned risk factors.

All patient and US data were entered into an electronic database. The retrieved data needed for the study were extracted from the clinical package, anonymized, and subsequently transferred to Microsoft Access. SPSS Statistics version 23.0 (IBM Corp., Armonk, NY, USA) was used to perform descriptive and comparative statistics. All results were considered statistically significant with $\alpha < 0.05$.

Results

A total number of 1250 women visited the antenatal clinic during the study period. Out of which 224 women were excluded as per exclusion criterion mentioned above. One hundred and two women were lost to follow up and therefore excluded from the study. Ultimately 924 pregnant women were enrolled in the study.

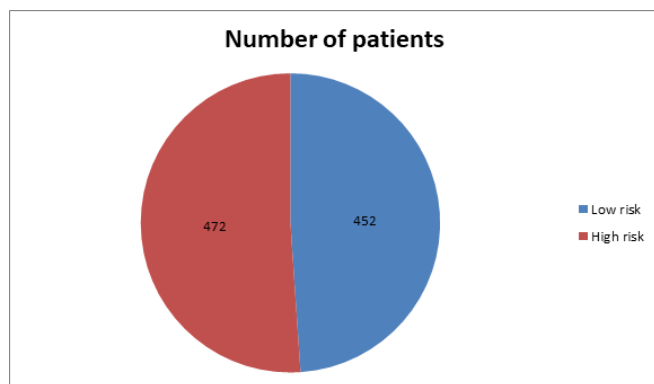


Figure 1: Graph demonstrating distribution of Patients Based on risk associated with pregnancy

[Figure 1] showed that out of 924 pregnant women 472 falls under high risk category and 452 under low risk category.

Table 1: Distribution of Patients Based on Gravida, Parity, Live Issues and Abortions

	Low risk (n=452)	High Risk (n=472)	p-value
Age(Years)	22.8±2.4	24.2±4.6	0.001
BMI	22.04 ±4.68	26.02 ±4.86	0.864
Gravida			
G1	236 (52.21)	96 (20.33)	<0.0001
G2	158 (34.95)	98(20.7)	
G3-4	58 (12.83)	220 (46.6)	
>G5	00	58 (12.28)	
Parity			
P0	236 (52.21)	156 (33.05)	<0.0001
P1	158 (34.95)	165(34.95)	
P2-3	58 (12.83)	138 (29.23)	
>P4	00	13(2.75)	

Table 2: First Trimester Anomaly Scan (FTAS)

	First Trimester Anomaly Scan		Mid Gestation Ultrasound Scan	
	Low Risk (n=452)	High risk (n=472)	Low Risk (n=438)	High Risk (n=454)
Anencephaly	0	1	0	0
Acrania	0	1	0	0
Cystic hygroma	1	2	1	0
Choroid plexus cyst	1	1	0	0
Holoprosencephaly	0	1	0	0
Omphalocele	1	1	0	1
Hydrocephalus	0	1	0	1
Hydrops	0	1	1	1
Spin a bifida	1	2	0	1
Talipes Bilateral	0	1	0	0
Congenital Heart Disease	0	2	0	0
Unilateral Renal agenesis	0	0	1	1
Bilateral Renal Agensis	0	0	0	1
Achondroplasia	0	0	0	0
Total	4	14	3	6

[Table 2] showed that out of 924 women subjected to First Trimester Anomaly Scan 18 patients demonstrated some sort of congenital anomaly whereas Mid Gestation Ultrasound Scan revealed 9 women out of 892 who gave birth to babies with congenital anomaly. Overall only 3% pregnant women revealed congenital anomalies among babies.

Discussion

Traditionally, in prenatal medicine, detailed anomaly scan is performed in the second trimester. With growing experience of sonographers and improving equipment, detailed depiction of fetal structures including the fetal heart became possible. Since more than a decade, there is growing evidence 5 that some of the major anomalies including major cardiac defects may already be detected at the end of the first trimester. Meanwhile, there is growing acceptance that at least in high risk pregnancies, detailed FTAS and

FTFE should be performed.^[6,7]

Present study showed that out of 924 women subjected to First Trimester Anomaly Scan 18 patients demonstrated some sort of congenital anomaly whereas Mid Gestation Ultrasound Scan revealed 9 women out of 892 who gave birth to babies with congenital anomaly. Overall only 3% pregnant women revealed congenital anomalies among babies. Our study emphasizes that a large number of major anomalies can be detected or suspected at the end of the first trimester. Rossi and Prefumo⁷ also laid stress that first trimester ultrasound can detect half of fetal malformations. They included nineteen studies on 78,002 fetuses, with 996 with malformations that were confirmed by postnatal or postmortem examinations. USG at 11 to 14 weeks detected malformation in 472 of the malformed fetuses (51%). Detection rate was highest for neck anomalies (92%) and lowest for limbs, face, and genitourinary anomalies (34% for each). The presence of associated anomalies appears to increase the accuracy of early ultrasonography. Multiple defects were more likely to be identified than isolated malformations (60% versus 44%). Detection rates ranged from 1% to 49% for spina bifida or hydrocephalus, ranged from 50% to 99% for valvular disease and septal defects, were 100% for acrania and anencephaly, and were 0% for corpus callosum agenesis and bladder exstrophy. Combination of transabdominal and transvaginal techniques resulted in a 62% detection rate versus 51% for transabdominal technique only and 34% for transvaginal technique only.

Although first trimester ultrasound can detect about 50% of fetal malformations, it cannot replace second trimester ultrasound because several malformations develop later than the first trimester. Also to be kept in mind is the fact that accuracy of early ultrasonography can be compromised by transient findings like midgut herniation, small septal defects, and hydronephrosis which might get resolved during intrauterine life.

Iliescu et al.^[8] did a prospective two-centre 2-year study of 5472 consecutive unselected pregnant women examined at 12 to 13+6 gestational weeks. The first trimester scan identified 40.6% of the cases detected overall and 76.3% of major structural defects. Major congenital heart disease (either isolated or associated with extracardiac abnormalities) was 90%. Major central nervous system anomalies were 69.5%. Fetuses with increased nuchal translucency (NT), the first trimester DR for major anomalies, were 96% compared to 66.7% amongst those with normal NT.

Nattu N et al,^[9] conducted a study to assess the feasibility and value of first trimester anomaly scan in both high risk and low risk pregnant patients. All patients were screened for congenital anomalies by 11-14 week ultrasound scan as part of routine prenatal care. Second trimester scan was conducted at 18 to 22 weeks gestation. Overall prevalence of congenital anomalies in study population was 2.6%. Out of these 64.4% were detected by first trimester anomaly scan, while another 35.6% were detected by mid gestation scan. Results obtained were similar to our present study.

There have been several studies seeing application for an extended protocol in which first trimester sonography is supported by a second anomaly scan. The obvious advantage of an extended protocol is that parents are offered the option of earlier and safer termination of pregnancy for the large majority of severe/lethal abnormalities.

Early ultrasound might be more accurate than second trimester ultrasonography for detection of malformations associated with oligohydramnios and anhydramnios which lead to poor visualization at later gestation necessitating amnioinfusion.^[6,8]

However, a detailed first trimester examination protocol involves supplementary resources: additional examination time and specialized personnel for the abnormal suspected/detected cases. Healthcare systems are yet to determine whether early first trimester diagnosis of most major structural abnormalities is cost-effective. Previous research, albeit using inferior ultrasound technology and a less extended protocol, found that the first trimester anomaly scan was cost-efficient in terms of medical and economic expenses, although they obtained lower detection rates.^[3,5,7,8]

The present study about the effectiveness of early ultrasonography in the diagnosis of structural defects does have some conflicts, which made it a challenge that to what extent structural congenital abnormalities could be detected by the routine scanning of fetal anatomy combined with nuchal translucency measurement. Few other basic prerequisites associated with early prenatal diagnosis consist of the high experience required and high costs in terms of time and equipment.

Conclusion

There is immense need for early diagnosis and timely intervention in the field of prenatal detection of congenital malformation. Earlier detection of fetal structural malformations would allow for earlier antenatal referral to a tertiary care facility and coordination of care among appropriate subspecialists. Parents are mentally prepared for these anomalies and a better co-ordination with specific sub-specialties can be assured to the baby. A detailed examination of fetal anatomy during the routine 11-14 weeks of gestation scan provides a comprehensive assessment of fetal anatomy and can detect approximately half of major structural defects in both low-risk and high-risk pregnancies. Detection rate increases markedly beyond 13 weeks of gestation compared with 11 weeks of gestation. Focus and emphasis should aim at detection of malformation earlier than 12 weeks owing to the very unique and clear facts that first trimester detection leads to easy termination of pregnancy and lessening of women's mental, physical, and psychological trauma.

References

1. Gembruch U, Knopfle G, Bald R et al. Early diagnosis of fetal congenital heart disease by transvaginal echocardiography. *Ultrasound*

Rajesh & Akhtar; First Trimester Ultrasonography in Detection of Fetal Congenital Structural Malformations

- ObstetGynecol 1993; 3:310-7.
- Allan LD. Cardiac anatomy screening: what is the best time for screening in pregnancy? *CurrOpinObstetGynecol* 2003;15:143-6.
 - Bhat AH, Sahn DJ. Latest advances and topics in fetal echocardiography. *CurrOpinCardiol* 2004; 19:97-103.
 - Carvalho JS, Moscoso G, TekayA et al. Clinical impact of first and early second trimester fetal echocardiography on high risk pregnancies. *Heart* 2004; 90:921-6.
 - Hernadi L, Torocsik M. Screening for fetal anomalies in the 12th week of pregnancy by transvaginalsonography in an unselected population. *PrenatDiagn* 1997;17:753-9.
 - Taipale P, Ammala M, Salonen R et al. Two-stage ultrasonography in screening for fetal anomalies at 13-14 and 18-22 weeks of gestation. *ActaObstetGynecolScand* 2004; 83:1141-6.
 - Rossi AC, Prefumo F. Accuracy of ultrasonography at 11- 14 weeks of gestation for detection of fetal structural anomalies: a systematic review. *ObstetGynecol* 2013;122(6):1160-7.
 - Iliescu, S, Tudorache, A, Comanescu et al., "Improved detection rate of structural abnormalities in the first trimester using an extended examination protocol," *Ultrasound in Obstetrics and Gynecology*, vol. 42, no. 3, pp. 300–309, 2013.
 - Natu N, Wadnere N, Yadav S, Kumar R. Utility of First Trimester Anomaly Scan in Screening of Congenital Abnormalities in Low and High Risk Pregnancies. *JK Science* 2014;16:151-155

Copyright: © the author(s), publisher. Asian Journal of Medical Radiological Research is an Official Publication of "Society for Health Care & Research Development". It is an open-access article distributed under the terms of the Creative Commons Attribution Non-Commercial License, which permits unrestricted non-commercial use, distribution, and reproduction in any medium, provided the original work is properly cited.

How to cite this article: Rajesh G, Akhtar W. Assessment of Potential of First Trimester Ultrasonography in Detection of Fetal Congenital Structural Malformations- A Retrospective Study. *Asian J. Med.Radiol.Res.* 2019;7(2):52-55.

DOI: [dx.doi.org/10.21276/ajmrr.2019.7.2.12](https://doi.org/10.21276/ajmrr.2019.7.2.12)

Source of Support: Nil, **Conflict of Interest:** None declared.

