

Prolapsed Lumbar Intervertebral Disease (PLID) Treatment in Acupuncture- A Case Study at Suoxi Acupuncture Hospital in Bangladesh

SM. Shahidul Islam¹, Hui Hui Li², Sabina Yasmin³

¹Visiting Consultant & Acupuncture Specialist, Suo-Xi Hospital (Acupuncture), Shaan Tower, Chamelibag, Santinagar, Dhaka, Bangladesh

²Consultant Department of Orthopedics and Traumatology, Peoples Hospital of Chinese Medicine, Ruian City, China.

³CEO, Suo-Xi Hospital (Acupuncture), Shaan Tower, Chamelibag, Santinagar, Dhaka, Bangladesh

Abstract

Background: Low back pain and sciatica are very prevalent medical complaints. As a consequence of these adjustments, fewer hours will be worked and less of a toll will be taken on the national economy. A complete medical checkup is required before starting any kind of therapy for these people. Inadequate medical or surgical therapy may exacerbate symptoms, increasing the likelihood of this occurring. This research aims to learn whether and how acupuncture may improve standard PLID care. **Subjects and Methods:** This inquiry took place at Suoxi Hospital, Shaan Tower, Chamelibag, Shantinagar, Dhaka, Bangladesh. A 55-year-old male patient has been complaining of lower back discomfort for the last ten years. It had been seven years since he had found relief from the pain in his lower back, but now he was pain-free. The results of this research suggest that acupuncture may be helpful for those with PLID.

Keywords: PLID, Acupuncture, Acupuncture, Physiotherapy, Mobilization, Manipulation, Stretching, Chinese Method, Low Back-pain, lumbar disc.

Corresponding Author: Dr. S. M. Shahidul Islam, PhD fellow, Visiting Consultant, Acupuncture Specialist, Suo-xi Hospital (Acupuncture), Dhaka, Bangladesh, India.

Email: drshahidul@gmail.com

ORCID ID: 0000-0002-6234-1688

Received: 05 December 2022

Revised: 20 January 2023

Accepted: 05 February 2023

Published: 27 February 2023

Introduction

Chronic back and leg pain have afflicted humans for as long as history books have been kept. In 1909, Oppenheims and Krause successfully removed a herniated intervertebral disc by surgery. Unfortunately, the disc tissue that was removed was misdiagnosed as an enchondroma.^[1] In 1929, Dandy reported successful excision of a disc tumor or chordoma from a patient suffering from sciatica. 2 Sciatica was first linked to a lumbar disc herniation by Barr in 1932.^[2] Seemes introduced a novel technique in 1939 to treat a ruptured intervertebral disc, which included partial laminectomy and retraction of the dural sac to expose and remove the disc while the patient was under local anesthetic.^[3] Couples using the same technique for disc removal have had the same level of success while operating separately.^[4] Total laminectomy followed by a transdural approach to the disc was the gold standard for disc removal. After disc excision, Mixer and Barr.^[5] suggested fusing the lumbar spine to stabilize it. In contrast, research by Frymoyer et al.^[6] and others shows that spinal fusion offers little benefit at all, if any at all. Misdiagnosis, performing surgery on the incorrect level, and the recurrence of disc prolapse at the same level or at a different level are all potential reasons why surgery fails.

Subjects and Methods

Case Report

A patient who was a 55-year-old man and who had been complaining of continuously increasing low back pain for the past seven years reached our institution. The patient's complaint was that the pain had been becoming worse over time. It had been seven years since he first started feeling this difficulty before he sought medical attention. During the course of this investigation that was carried out in an environment that was maintained under constant surveillance inside the constraints of a laboratory. In addition, the results imply that the existence of PLID is compatible with these discoveries, which is in line with what was discovered. This is in accordance with what was observed. Mobilization, manipulation, and stretching of the lumbar spine, in addition to acupuncture of the lower back, are often used as the first lines of defense in the treatment of low back pain. The patient is placed at ease with a combination of lumbar mobility and manipulation, which is one of the strategies we use. The follow-up investigation yielded heartening findings, and the conclusions that were drawn from those findings were also positive in general. The condition of the patient significantly

improved after he had acupuncture on his lower back for the seventh time. The patient was taken aback when his long-term lower back discomfort miraculously began to improve all of a sudden.

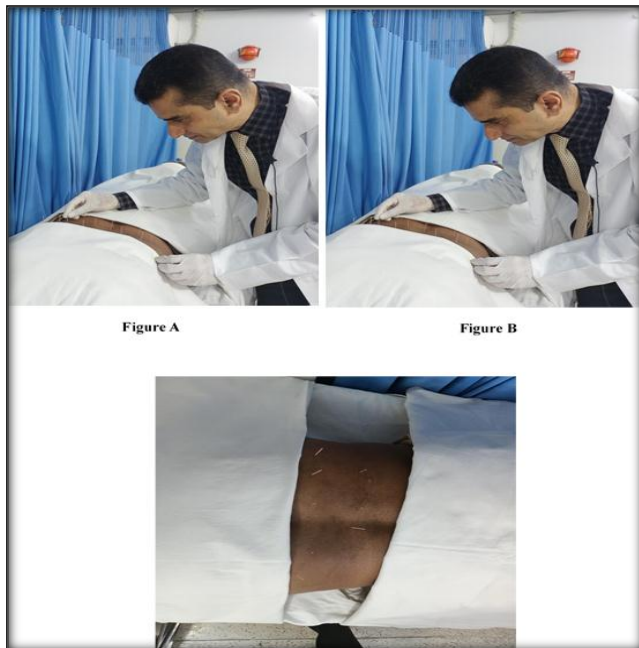


Figure A, B, C: Giving Acupuncture at the Lumbar Region

Results & Discussion

When combined, pelvic traction and exercise may alleviate symptoms in 90% of patients.^[2] If non-invasive methods have already been exhausted, surgical options should be considered. The patient and the physician both need to understand that disc surgery is not a permanent solution but rather may help alleviate some of the symptoms. It does nothing to correct the underlying pathology that permits the herniation to arise or to return the back to normal. Patients undergoing surgical procedures should make an effort to improve their posture and body mechanics. Repetitive flexion of the spine, such as in bending, twisting, or lifting, should be minimized or avoided. If long-term improvement is desired, lifestyle changes must be made by patients. Accurately selecting patients for disc surgery is crucial to achieving positive outcomes. The ideal patient has had persistent, unilateral leg discomfort below the knee for at least six weeks. Although relaxation and anti-inflammatory drugs may have temporarily alleviated the pain, it should have returned to its pre-treatment levels after at least 6 weeks of therapy. When examining the sciatic nerve, look for symptoms of inflammation and, if possible, objective indicators of localizing neurological damage. The patient's examination results should be confirmed by CT, MRI, or myelography. Spangfort discovered that 30 percent of patients who had lumbar disc excisions reported discomfort in the back following surgery [8]. A 55-year-old man attended our clinic complaining of low back pain he'd been

having for nearly ten years. Adjusting to such excruciating pain was a difficult process. Many of the tests were conducted by us, but we did it independently and paid for the materials ourselves. The results of finding the diagnosis of the patient reveal PLID. Lumbar spine degeneration was detected at an early stage. Acupuncture and physical therapy, used together, helped alleviate the patient's symptoms. When all factors were considered, it was clear that this was the best option. After 7th sessions of acupuncture, the patient reported a substantial reduction in their lower back pain. Even so, the illness was successfully treated with medicine.

Conclusion

Experts were taken aback by the findings of the follow-up study. After the seventh acupuncture session, the patient reported decreased discomfort in her lower back. The pain in my back has fully subsided. The use of acupuncture for the treatment of prolapsed lumbar intervertebral disc has been shown to be successful (PLID).

References

1. William KD, Park AL. The back. In: Canale ST (ed). Campbell's operative orthopaedics. 10th edn. Philadelphia Pennsylvania: Mosby, 1998: 1955-2028
2. Barr JS, Hampton AO, Mixter WJ. Pain low in the back and sciatica due to lesions of the intervertebral disc. JAMA 1937; 109: 1265.
3. Semmes RE. Diagnosis of ruptured intervertebral disc without contrast myelography and comment upon recent experiences with modified laminectomy for their removal. Yale J B Med 1929; 11: 333.
4. Love JG. Removal of intervertebral disc without laminectomy. Proc staff meet Mayo clinic 1930; 14: 8000.
5. Mixter WJ, Barr JS. Rupture of the intervertebral disc with involvement of the spinal canal. N Engl J Med 1934; 211: 210.
6. Frymoyer WJ, Hailey EN, Howe J. A comparison of radiographic finding in fusion and nonfusion patients ten or more years following lumbar disc surgery. Spine 1934; 5: 435. Tang, S., Qian, X., Zhang, Y., & Liu, Y. (2016). Treating low back pain resulted from lumbar degenerative instability using Chinese Tuina combined with core stability exercises: A randomized controlled trial. Complementary Therapies in Medicine, 25, 45–50.
7. Apley G, Solomon L. The back. In: Apley G, Solomon L (eds). Apley's system of orthopaedics & fracture. 7th edn. Oxford: Butterworth Heineman Ltd., 1993: 348-382.
8. Spangfort EV. The lumbar disc herniation: a computer aided analysis of 2504 operation. Acta Orthop 1972; 142(Suppl 2): 1.

Copyright: © the author(s), published in Asian Journal of Medical Radiological Research, Vol-11, Issue-1. This is an open access article under the Attribution-Non Commercial 2.0 Generic (CC BY-NC 2.0) license. (<https://creativecommons.org/licenses/by-nc/2.0/>)

How to cite this article: Islam SS, Li HH, Yasmin S. Prolapsed Lumbar Intervertebral Disease (PLID) Treatment in Acupuncture- A Case Study at Suoxi Acupuncture Hospital in Bangladesh. Asian J. Med. Radiol. Res. 2023;11(1):6-7.

DOI: [dx.doi.org/10.47009/ajmrr.2023.11.1.2](https://doi.org/10.47009/ajmrr.2023.11.1.2)

Source of Support: Nil, Conflict of Interest: None declared.