

Measurement Of Morphological Characteristic Of Sudanese Female Pelvis Compare To Other Nationalities.

*Fatima Dahi Mohammed¹ Al Taher Osman Ali², Hamed Osman¹Ikhlal Abdelaziz Hassn³, Asma Ibrahim Ahmed³

¹College of Applied Medical Science. Al Taif University Saudia Arabia.

²Dean of postgraduate college Al Ribat University.

³College of Medical Radiologic Sciennce. P.O.Box 1908, Khartoum

Abstract

The main objectives of this study were to establish standard measurement of Sudanese female pelvis and comparing the measurements with other nationalities in order to develop a Sudanese reference document. The study also aimed to describe the, characteristic of Sudanese female pelvis, specially the birth canal, and to determine the prevalence of different anatomical variation in different parts of the Sudan. The result of this study showed that there were two mains pelvic types in the Sudan, out of four known types in the world, the two types were: The anthropoid pelvis (oval birth canal) and the gynaecoid pelvis (rounded birth canal). The other types of pelvis were not common in Sudan. The two types presented as following: In north of Sudan 68% of cases were anthropoid while 32% of cases were gynaecoid. In South of Sudan, 30% of cases were anthropoid and 70% of cases were gynaecoid. In west of Sudan 49.3% of cases were anthropoid and 50.7% of cases were gynaecoid. In East of Sudan, 22% of cases were anthropoid and 78% of cases are gynaecoid. In conclusion, the anthropoid and gynaecoid pelvises are common in Sudan. While the platypelloid and android pelvises are rare

Key Words: Pelvis , measurement, Sudanese, gynaecoid, platypelloid, anthropoid.

INTRODUCTION

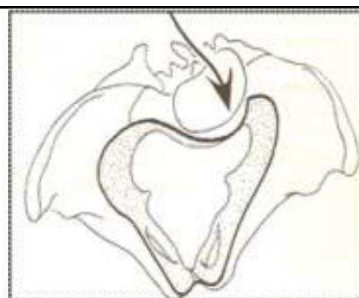
Type of the pelvis. World wide the female pelvis divided into four types :The anthropoid pelvis [dolichopellic]- with long oval pelvic brim the anteroposterior diameter exceeds the transverse diameter. The gynaecoid pelvis [mesatipellic] with rounded pelvic brim the antero-posterior and transverse diameters are of equal length or the former exceeds the latter by not more than 1cm. The android [brachypellic] pelvis shows transverse oval pelvic brim, the transverse diameter exceeds the anteroposterior diameter by more than 1cm but less than 3cm. The platypelloid [platypellic] pelvis has a flat pelvic brim, the transverse diameter exceeds the antero-posterior diameter by 3cm or more.^[4-11]

The present study confirmed these types with different shapes, and measurements in each region of the Sudan. There are some factors affecting shape and size of female pelvis, these factors occasionally due to :poor socioeconomic condition.[shortage of protein and calcium in diet in early stages of development.] it play an important role in the life of individual community or nation- lack of food or bad nutrition which affects the growth of children's bodies, mind and behaviors.^[7,17] also pelvic deformity due to childhood rickets or adult osteomalacia [relatively higher incidence in developing countries].^[18,28] Rickets is softening of the bones in children potentially leading to fracture and deformity. Osteomalacia is the term used to describe a similar condition occurring in adults, generally due to deficiency of V.D.^[18,21] fracture of the pelvis. All the types of fractures of the pelvis after healing may lead to change in shape and size of the pelvis and affect the measurements of the pelvis.^[22,24] Developmental abnormalities also affecting pelvic shape and measurements. Spinal disorders like Lumbar kyphosis of the lower dorsal or lumbar region which starts in

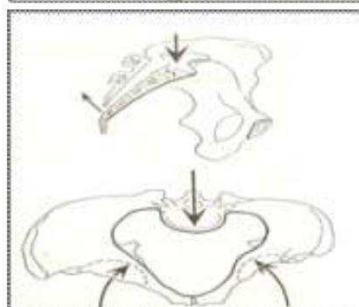
Address for correspondence*

Dr.Fatima Dahi Mohammed .

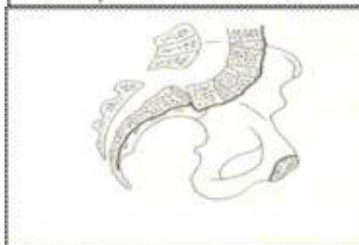
College of Applied Medical Science. Al Taif University
SaudiaArabia.



(Fig.2-1)



(Fig.2-2)



(Fig.2-3).

childhood may alter the shape of the brim of the pelvis, as the weight of the body pushes the upper part of the sacrum backward and the lower part forward. Shape and inclination of the pelvis may be affected. As the result the side walls of the pelvis converge forming a funnel pelvis^[19,22] [Fig.2-1] [Fig.2-2] [Fig.2-3].

Fig [2-1] Showing scoliosis and kyphosis of the pelvis.^[17,24] Fig [2-2] The rachitic pelvis.^[27,28] [Tracing

from a radiograph, arrows showing how pressure of the softened bones alters the shape of the pelvis] and Fig [2-3] Showing spondylolisthesis,^[8] tracing from the radiograph showing the subluxation of the fifth lumbar vertebra upon the sacrum.

Lumbar spondylolisthesis: The 5th lumbar vertebra with the above vertebral column is pushed forward while the promontory is pushed backwards and the tip of the sacrum is pushed forwards leading to outlet contraction [fig.2-2].^[25,28]




Fig (2-2) Showing deformity of the sacrum (Naegele's pelvis of the sacral ala) .[25]

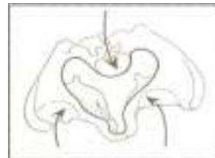


Fig (2-3) Showing osteomalacic pelvis 1[5,25] (arrows show deformity of bones)

Lumbar scoliosis: Scoliosis is an abnormal lateral curvature of the spine. This lateral deviation may occur in one or more of the movable vertebrae, scoliosis is the most common distortion of the spinal curvature. This condition may result from developmental problems, such as incomplete vertebral formation.^[6,18] it generally appears in girls during adolescence, when periods of growth are most rapid .It causes bays on each side of the sacral promontory so that the shape of the brim is asymmetrical. Fig [2-1].^[6-27] Congenital malformation of the sacrum: Present as Naegele's pelvis and Robert's pelvis. These are due to the defective development of one or both sacral lateral masses so that the sacrum fuses with the ilium on one or both sides.^[29] [fig.2-2] The high assimilation pelvis occurs when the fifth lumbar vertebra is fused to the sacrum [sacralization], thus increasing the inclination of pelvic brim, which affects engagement of the fetal head. The low assimilation pelvis results in a sacrum composed of 4 vertebrae, the first sacral is fused to the 5th lumbar vertebra [lumbarization].^[24,25] Congenital malformations of the limbs: The congenital dislocation of the hip, may cause pelvic deformity. The child puts most of its weight on the stronger leg, and on this side the pelvis pressed in, with flattening of the brim on the same side.^[5,6,25] Fig [2-3].

Environment and social habits. The environment in which a women lives has a great impact on her physique and general features. It also has an effective role on her psychological structure and her culture and customs. The female age. The young female has small pelvis, shows shorter diameters of the pelvis due to incomplete growth, development and ossification of bones. The study showed that most of young females have small contracted pelvis because the pelvis has not yet matured fully at age <19 year, and this may change as consequence of physiologic events, during puberty. The young female pelvis grows at an accelerated rate to change from an anthropoid to gynaecoid 1.^[7,25,51] Several hormones act on bone tissue, but over or under production of these hormones, can affect growth and regeneration of bone and tissues and lead to a number of disorders. These hormones are growth hormones, thyroid, parathyroid, androgens and estrogens.^[17] eg. Excessive androgen which may produce android pelvis. Degenerative and autoimmune disorders also can affect bones.^[31] The risk factors include lifestyle habits, specifically exercise and nutrition. Lack of sufficient calcium and vitamin D can have a lifelong impact on bone development and strength, making even young bones more brittle and prone to fracture. Children whose bones are still

forming are recommended to take about 800 mg of calcium daily, adolescents should take about 1300 mg of calcium daily.^[7,27]

MATERIAL AND METHODS

A total of 360 females from all regions of Sudan [North, South, West, East and Middle] in different ages, social status, socioeconomic and environmental conditions were examined in different hospitals in Sudan by different imaging modalities.

The machines used: Conventional X ray machine of different marks were used in this study. These machines were: Siemens and Shimadzu. In addition to Dual CT scanner machine GE and MRI .

Technique used :The X-ray examination of the pelvis is done by different methods as following : Antero-posterior projection and Lateral projection.^[8,9,10] For assessment of major pelvic measurements CT and MRI are preferable and for trauma CT is usually the preferred option.

RESULTS

The results and analysis of the X-ray findings including CT and MRI, which was done from the data collected from Sudanese women in different parts of Sudan. The data included female age, height, weight, occupation, marital status, parity, regions [tribe], mode of delivery, and history of bone and hormonal disorders. The X-ray findings of anteroposterior and lateral views of the pelvis show the morphological characteristics, measurements and types of the pelvis by looking into the shape of:- Ischial spine less prominent ischial spine means anthropoid pelvis, prominent ischial spine means gynaecoid pelvis - Greater sciatic notch, wide greater sciatic notch means anthropoid medium greater sciatic notch means gynaecoid pelvis - narrow sciatic notch means android pelvis - Sacral inclination - slightly curved sacrum means anthropoid pelvis, curved sacrum means gynaecoid pelvis. - Subpubic arch - Subpubic angle, <90 means anthropoid pelvis, subpubic angle > 90 means gynaecoid pelvis. While the measurements included :- - Anteroposterior diameter [AP] - Transverse diameter [TV] - Oblique diameter [Obl] - True conjugate diameter [TC] - Digaonal conjugate [DC] - Lower inner symphysis pubis to sacro coccygeal joint [Lispscj]

DISCUSSION

The present study confirmed that there are two types of pelvis in Sudan, anthropoid and gynaecoid pelvis. The anthropoid pelvis is described as a type of pelvis in which the pelvic inlet is oval and the anteroposterior diameter of the pelvic inlet is much greater than the transverse diameter. The posterior portion of the space in the true pelvis is much greater than the anterior portion. The anthropoid pelvis is present in about 68% of women from the total cases in North of Sudan as Shaygea and another Arabic tribes in different regions in Sudan. While gynaecoid present as 32% of cases. The anthropoid pelvis in the North of Sudan at the reproductive age measured as following: 12.9+0.1 14.1+0.1 12.3+0.1 13.1+0.1 14.6+0.1 14.0+0.2. For AP. TV. Obl. TC. DC. Lispscj respectively. The ischial spine was medium in prominence while the subpubic arch was slightly curved and the subpubic angle less than 90 degree. In the sagittal plane [lateral view], the greater sciatic notch was wide, the sacrum was high and slightly curved, Fig[1-2] Similar description was reported by Caldwell and Moly[31], in their classic work on the female pelvis and they emphasized on the part played by an evolutionary influence. Singh,^[32,35] suggested that female attractiveness my

Table (4.1) Shows mean+ SD for pelvic measurements for tribal groups. The differences between tribal groups was significant at P=0.05 Chi-square $\chi^2= 261$, P= 0.04.

Diameter	Mean + SD measurement of Sudanese female pelvis.					
	North Shaygea Danagla Gaalyaen	South Dainka Niwair Baria		West Bagara Nuba Foar	East Hadandawa Bani A mer	Middle Kawhla (Mixed tribe)
A P	12.6 ± 0.1	11.8 ± 0.2		12.3 ± 0.1	11.0 ± 0.2	11.6 ± 0.2
T V	14.1 ± 0.1	14.2 ± 0.2		14.2 ± 0.1	13.5 ± 0.2	14.1 ± 0.2
Obl	12.3 ± 0.1	12.1 ± 0.1		12.3 ± 0.1	11.8 ± 0.2	12.1 ± 0.2
T C	13.1 ± 0.1	12.4 ± 0.2		12.9 ± 0.1	11.6 ± 0.2	12.1 ± 0.2
DC	14.6 ± 0.1	14.7 ± 0.2		14.8 ± 0.1	14.0 ± 0.2	14.6 ± 0.2
Lispelj	14.0 ± 0.2	13.4 ± 0.2		13.9 ± 0.1	12.3 ± 0.3	13.0 ± 0.2

Table (4.21) Shows the Sudanese female pelvic measurements compared with other nationality.

Obstetric dimension	Sudanese	White American	Black American	Euro Bean	Arabian	Asian	African Nigerian
A P	11.7 ± 0.2	10.7 ± 0.7	10.0 ± 0.7	10.5	11.0	7.9	8.4 ± 0.9
T V	13.5 ± 0.2	13.5	13.0	13.0	13.5	9.5	14.0 ± 0.8
Obl	12.0 ± 0.2	12.0	12.0	12.0	12.5	8.0	13.0
T C	11.5 ± 0.2	11.2	10.5	11.0	11.5	8.4	8.9
DC	13.0 ± 0.2	12.7	12.0	12.5	13.0	9.9	10.4
Outlet	13.0 ± 0.3	12.3 ± 0.1	11.8 ± 0.9	13.0	13.5	8.6	11.5 ± 1.2

The modern Sudanese female pelvic measurements are generally larger than the other nationalities, except the Arabian pelvic measurements which slightly larger than the Sudanese pelvis.

be influenced by female waist size compared with hip size, [waist to hip ratio WHR] and he believes this ratio may indicate female pelvic type , and therefore, the size of reproductive canal. The circumference of anthropoid pelvis exceeds posteriorly and the gynaecoid exceeds laterally. [32] Pawlowski and Grabarczy, [33] agree that WHR determines the body shape of the female. If the hip and thigh increase more than the waist it may mean that the women are healthier and fertile. The waist may increase more than hip, during pregnancy and in the post- reproductive period. It is accepted that accumulation of visceral fat in the waist region can be a signal of higher morbidity risk. The waist is a good indicator for normal level of sex hormones as argued by Bjornorp. [34] The gynaecoid pelvis is a typical female pelvis and is common in Sudan found in 50.6% of women world wide. Presents about 70% of the cases in this study in the South while anthropoid presents about 30% .It is the common pelvic type in South because, the noticeable characteristic of a woman in the South of Sudan is her tallness, as if she has inherited this characteristic from the ebony tree. The Southern woman used to live in the jungle and eat the fruits thereof. She works in agriculture and animal grazing. She brings drinking water and cooking wood on her bare head. She brings up her children on the tribe traditions and cooks her family food. Her walking for long distances among the trees may protect her from obesity. Her food

is limited to Aseeda [food made of dura flour], natural fruits and wild animal's meat. As for cows, they do not slaughter them as they constitute symbols of pride and social value. They are paid as dowries for marriage and social transactions. There is no circumcision like the so-called [pharonic circumcision] in the North. Also there is no problem in her skeletal structure. Her pelvis is wide and normal because she is tall. Some Southern tribes, however, like Baria and Zandi do not have these characteristics. They are short and their female pelvises may be narrower. Nevertheless, they do not suffer from delivery problems. They have not heard of a woman who dies or her baby dies during delivery. There are very rare cases of urinary fistulae. The Southern women rarely suffer from pregnancy or delivery problems, and therefore, they are very reproductive. Baried and Thomas defined that taller women have roomier pelvis and better reproductive histories than the others. But the gynaecoid pelvis in the South has special characteristics in which the subpubic arch is narrow and the subpubic angle is acute [less than 90], Fig[3-4-5]. These findings look similar to the findings in some tribes in the North of Sudan like Galieen tribes, [fig.a-11.a]. The gynaecoid pelvis in the South measured as following: 11.8+ 0.2 14.2+ 0.2 12.1+ 0.1 12.4+ 0.2 14.7+0.2 13.4+0.2 for AP.TV. Obl. TC. DC. Lipscej respectively. The gynaecoid pelvis is 41% in white women and 42% in black women worldwide.^[33] A similar result was reported by Michael.^[37] Who noticed that the gynaecoid pelvis was found in 50.6% of women in the world. And it is more wider and not as high as the male pelvis, the angle of the female pubic arch is wide and round, the female sacrum is wider than the male sacrum and the iliac bone is flatter. In the West of Sudan the morphological appearance of the gynaecoid pelvis in the West of Sudan, is typical and is present in about 50.7%, while anthropoid is present in 40.3%. The anteroposterior radiographs showed that the pelvic brim is almost rounded. In Southern Kordofan [Nuba mountains area], women are characterized with strong bones and body, and hence wide pelvises. This is due to good nutrition of millet, milk, vegetables, meat [..etc] as well as climbing of trees and mountains. Women work in farms and houses and they bring up the children. Pelvic measurements are normal and there are no difficulties in delivery, according to the statistic of Al-Obayid Hospital and other hospitals in the region [personnel communication] In Darfur, however, women suffer from pelvic narrowness. They always work in farms; they graze the animals and carry their young children on their backs during work, a matter which leads to malformation and deformity at the ilium area. The femininity features of these women gradually disappear, because they work very hard in difficult jobs which are limited to men in other regions of Sudan. They do not take care of themselves, or of their nutrition. They have small pelvis which leads to difficult delivery and fistulae. Women are not health-educated and they do not see doctors for pregnancy follow-up. This leads to destruction of women and families. The fistula resulting from small and narrow pelvis and difficult delivery can damage the women's life and that of families. The gynaecoid pelvis is common in Nuba tribe in the South West of Sudan. These tribes have special criteria in which the pelvic brim is slightly heart shape, the ischial spines are not sharp and are less prominent during clinical examination [P.V]. The subpubic arch is flat in the Nuba tribes as it appeared in the X-rays but slightly rounded in other tribes Fig[5] The subpubic angle measured at least 90°, and the greater sciatic notch was medium. The lateral radiograph showed the sacrum to be high, and curved. fig[6-7]. Nuba tribes have got normal gynaecoid pelvis with special characteristics. The women at the Nuba hills are healthier due to

good nutrition and environment, they have no difficulties in delivery except for hereditary factors. The gynaecoid pelvis measured as following: 12.3+0.2 14.2+0.2 12.1+0.2 12.4+0.2 14+0.1 13+0.2 for AP. TV. Ob. TC. DC and Lipscej respectively. The women shape determines the pelvic type. Pawlowski,^[34] described the woman who has gynaecoid pelvis, as having gynaecological body shape during their reproductive period of life. In the East of Sudan the gynaecoid pelvis is common [typical gynaecoid] present in about 78% of female population while anthropoid presents about 22%. The Eastern region of Sudan encompasses multiple tribes, including: Hadandawa, BaniAamir, Bija [..etc]. Caesarian operations are common and noticeable at Port-Sudan Hospital. Patients come from different parts of the East, due to pelvic narrowness and bone malformations. Pelvic narrowness, which may lead to fistulae, and sometimes to fetal death, is attributed to malnutrition, shortness of the body, lack of awareness and practice of women circumcision, a matter which leads to complications and pre-natal death. The main causes of pelvic narrowness among the Eastern women is due to early marriage, hereditary factors and lack of health education [personnel communication]. In the past some tribes in the East had habits of forcing young girls to sleep in certain beds with holes at the site of buttocks and elevating the head region so as to make the pelvis protrude posteriorly. It was noticed this will cause spondylolisthesis later which may reduce the size of the pelvic inlet that may lead to obstructed labour. The women with large pelvis [buttocks] in the East are considered to be attractive and beautiful. The gynaecoid pelvis in the East measured as following: 11.0+ 0.2 13.2+0.2 11.8+0.2 11.6+ 0.2 14.0+ 0.2 12.3+0.1. for AP. TV. Obl. TC. DC. Lipscej respectively. The present study showed that the android pelvis is rare. The previous studies showed that 1.7% of black women and 2.6% of white women in America had android pelvis while it was reported in about 15% of African women [36]. The shape of android pelvis in anteroposterior X-ray image is, heart shaped with funnel shaped pelvis. The ischial spine is not prominent and is directed downwards, in lateral view. The greater sciatic notch is narrower; the subpubic arch is very narrow while the subpubic angle is acute. The sacrum is narrow and curved anteriorly and the midplane diameter of the pelvic outlet is smaller than in gynaecoid pelvis. Similar results were found by Bukar,^[38] who noticed that, the android pelvis shows higher sacrum, narrower apertures and taller funnel shaped than the female pelvis. Vaginal delivery is likely to be difficult unless the overall pelvis is large and the foetus is small. The android pelvis measures as following: 10+0.1, 14+0.1, 12+0.1, 10.5+0.1 cm for AP.TV.Ob. Lipscej respectively. The shape of a woman with android pelvis is like that of a man and she is not attractive. Pawlowski and Dunbar[34] found that, higher WHR and smaller hip width compared to the shoulder diameter indicate android pelvis, Caldwell and Moly[32] in their classic work on the female pelvis confirmed this result. The platypelloid pelvis is not common in Africa and also in Sudan as was shown by this study. It is flat female pelvis and women with this type of pelvis have great difficulty in giving birth.^[38]

CONCLUSION

This study showed two main types of pelvises in Sudan, anthropoid and gynaecoid while the android, and platypelloid were rare. The anthropoid pelvis is common in the North of Sudan especially among the Shaygia and other Arabic tribes in the different regions of Sudan. The gynaecoid pelvis is common in all parts of the Sudan with slight variation from one region to

another. The study showed that there were significant variations in the morphological appearances of the female pelvis in different regions of Sudan. The study showed that most of young females have small diameter pelvis, due to incomplete growth, development and ossification because the pelvis has not yet matured fully at age <19 year, and this may change as consequence of physiologic events, during puberty. marry at early ages which leads to problems during labor because the small pelvic size leads to obstructed labor [verbal communication].

REFERENCES

- 1- Holy Quran, Surah Al-murslet. 77/20-23.
- 2- Holy Quran, surah, Al-muminin. 23/12-13.
- 3- Albar M.A. Creation of human being between medicine and Quran. 10th edition, Saudi Publishing and Distributing House. Jeddah, 1995; P.57:58-59.
- 4- Chung K.W. Gross anatomy 3rd edition, William and Wilkins. Baltimore Maryland. 1996; P.205.
- 5- El- Mowafi D. Obstetric Simplified 3rd edition Elmansura Egypt. 2004; P.227:229-231.
- 6- Bell G.A. Basic radiographic positioning and anatomy. Bailliere Tindall London. Philadelphia 1986; P.133
- 7- Thomas H. The role of nutrition in pelvic variation. Am. J. Obstet. Gynaecol. London. 1947; 54:62-73.
- 8- Chesney DN, Muriel O. X-ray equipment for student and radiographer 3rd edition New Delhi India, 2001; P.209
- 9- Seeram E. Computed tomography CT. 2nd edition W.B. Saunders company, 2001; P.22:23-24
- 10 Brook CW. Practice MRI. 3rd edition, Wiley Blackwell 2008; P.5:7-9.
- 11 Moore K.L Clinical Oriented Anatomy 4th edition 1999; P.337
- 12 Peter and Roger, Gray's Anatomy, 36 edition, Great Britain 1980; P. 378:386-387. 39 edition 2005; P.383:384-385-424-429.
- 13 Gosling JA, Harris PF, Whitmore I, Willan PL. Human Anatomy, 4th edition, Mosby; 2002:P.142:146.
- 14 Putz R, Pabst R. Sobotta Atlas of Human Anatomy 12th edition, Williams & Wilkins; 1997;P.265:266-269.
- 15 Glenda J. Bryan E, David R. Skeletal anatomy, 3rd edition, Churchill Livingstone .2000;P.169:172.
- 16 Snell R.S. Clinical Anatomy for student. 5th edition USA 1992; P. 278:279.
- 17 Pamella R Lippincotts illustrated Reviews, Biochemistry 2nd edition United State of America .1994; P.303:319.
- 18 Roderik N M, Keith W Muir's Text book of Pathology. 13th edition India 1992; P.960.
- 19 Nield LS, Mahajan P, Johi A, Kamat D. Rickets: not a disease of the past. American Family Physician. 2006; 74: 619-626.
- 20 Sukkar MY, Munshid HA, Ardawi MSM. Concise Human. Physiology 1st edition, 25 John street, London.P.149:153.
- 21 Walter JB, Israel MS. General Pathology 6th edition, Churchill Livingstone, 1987; P.494:495.
- 22 Davidson SS Davidson's Principles and Practice of Medicine .17th edition, Churchill Livingstone.1995;P.65:669.
- 23 David S, Radiology and Imaging: 17th edition, Churchill Livingstone 2003; P. 285.
- 24 Rubin E, John L. Pathology Lppincott, New York 3rd edition 1999;P. 1352.
- 25 Jones L.Fundamental of Obstetrics and Gynecology Volume 1 4th edition, Faber and Faber. 1986; P.350:352
- 26 .Institute of Medicine, Food and Nutrition Board. Dietary Reference Intakes: Calcium, Phosphorus, Magnesium, Vitamin D and Fluoride. National Academy Press, Washington.DC, 1999; P. 292.
- 27 .Deluca HF, Zierold C. Mechanisms and functions of vitamin D. Nutr.1998; 54:56.
- 28 .Terri L, Fauber E. Radiographic imaging and exposure. 3rd edition, 2009; P.2:5-6.
- 29 Wiley J. Radiation Detection and Measurement 3rd edition, 2000: P.1:3-9.
- 30 Hill DR. Principle of diagnostic x-ray apparatus 1st edition 1997;
- 30 Thomas H, Foote WR, Friedman I. The clinical significance of pelvic variation. Am. J. Obstet. Gynaecol. 1939; P. 38: 634-642.
- 31 Lister A.M. Pelvic type and measurements, American college of obstetrician and gynaecologists. 1960; P.85:89-90.
- 32 Caldwell WE., and Moly HL. Anatomical variation in the female pelvis and their effect on labor with a suggested classification. Am.J. Obstet. Gynaecol. 1933; P. 426: 479.
- 33 .Singh D. Adaptive significance on female physical attractiveness: role of waist- to- hip ratio. Journal of personality and social psychology. 1993 [a]; P. 65: 293-307.
- 34 Pawlowski, B, Grabarczyk M. Center of body mass and the evolution of female body shape. American Journal of Human Biology 2003; P.15: 144- 150.
- 35 Bjomtorp, P. Adipose tissue distribution and function. International Journal of Obestity. 1991; P.15: 67-81.
- 36 Singh D. Body shape and women attractiveness. The critical role of waist- to hip ratio. Human nature. 1993 [b]; P. 4: 321-397.
- 37 Michael L. Contracted pelvis in Nigeria, Queen Elizabeth hospital east Nigeria. International journal of obstetric and gynecology. Volume70 1986; P.487:494.
- 38 Bukar M. Pelvic types as seen in tropical setting. Nigerian Journal of Medicine. 2010. P. 19 .