

High Resolution Computed Tomography Patterns of Diffuse Parenchymal Lung Diseases with Clinical and Pathological Correlation

Reshu Sharma¹, Sunit Chand², Sarvinder Singh³

¹Graded Specialist, Department of Radiodiagnosis, INHS Asvini, Mumbai, Maharashtra, India, ²Classified Specialist, Department of Radiodiagnosis, Base Hospital, Delhi, India, ³Senior Advisor, Department of Respiratory Medicine, Base Hospital, Delhi, India.

Abstract

Background: Aim: To assess the radiological patterns of DPLDs and their correlation with clinical and histopathological findings and to evaluate the role of HRCT in DPLDs. **Subjects and Methods:** 42 patients were included from amongst the patients with a strong clinical suspicion of diffuse parenchymal lung disease. All the patients underwent clinical assessment, pulmonary function tests, conventional chest radiography, high resolution computed tomography and histopathological examination and the data was recorded on the proforma after informed consent. The patients were scanned using SIEMEN'S SOMATOM SENSATION 16 Slice Spiral CT Machine. **Results:** The most commonly identified diffuse parenchymal lung diseases were Idiopathic pulmonary fibrosis and Miliary tuberculosis, each comprising 19.1 % of the total number of cases. The next most common group was of patients with Sarcoidosis, comprising of 16.7 % of the total cases. The most common abnormalities seen on spirometry are reduced FVC (44.7% patients had FVC value ranging between 61% to 80 %) and reduced TLC values (52.6% patients had TLC between 61% to 80%). The %FEV1/FVC is however maintained between 81% to 100% in 57.9% of total number of cases. DLco could not be performed in four patients because of very low FVC. **Conclusion:** High resolution computed tomography is an invaluable tool in the diagnosis and characterisation of diffuse parenchymal lung diseases in an appropriate clinical setting.

Keywords: Diffuse parenchymal lung diseases, High resolution computed tomography, pulmonary function tests.

Corresponding Author: Dr. Reshu Sharma, Graded Specialist, Department of Radiodiagnosis, INHS Asvini, Mumbai, Maharashtra, India.

Received: October 2018

Accepted: December 2018

Introduction

Diffuse parenchymal lung disease (DPLD) is a heterogeneous group of disorders of the lower respiratory tract characterized by inflammation and derangement of the interstitium and functional alveolar unit.^[1] The disease involves interstitium, epithelium, endothelium, mesenchymal cells, alveolar structures and small airways. Most of the interstitial lung diseases begin with inflammation.^[2] The lung is affected due to inflammation of walls of the air sacs and scarring (or fibrosis) in the interstitium. The inflammation may affect different parts of the lung which heal or lead to permanent scarring of the lung tissue. Thus, the entire pulmonary parenchyma is involved and the level of disability depends on the amount of scarring.^[3]

Radiological imaging plays an important role in the evaluation of the diffuse parenchymal lung diseases.^[4] Patient with suspected diffuse parenchymal lung disease usually undergo chest radiography as the initial imaging investigation.^[5,6] In most cases, this is abnormal and sometimes enables us to reach a specific diagnosis in conjunction with the clinical and laboratory findings. However, the pattern of chest radiograph is not specific in most patients. In some patients, the chest radiograph may be

normal.^[7,8]

High resolution computed tomography (HRCT) scanning is currently the most accurate non-invasive modality for evaluating the lung parenchyma. Unlike chest radiography, HRCT scans provide cross sectional images and the extent of disease is therefore much more readily appreciated than on the chest radiograph.^[9,10] A combination of clinical and HRCT information enables a correct diagnosis to be made in up to 80% of patients with DPLD. In the appropriate clinical setting, lung biopsy samples may not be required when the appearance of the HRCT scan is characteristic.^[11,12] This study assessed the radiological patterns of DPLDs and their correlation with clinical and histopathological findings and to evaluate the role of HRCT in DPLDs.

Subjects and Methods

After approval from the Hospital ethics committee, prospective observational study was conducted in the Department of Radiodiagnosis, Base Hospital, Delhi Cantt-10 in association with Department of Respiratory Medicine and Department of Pathology. 42 patients were included in the study and random sampling was done from amongst the patients with a strong clinical suspicion of diffuse

parenchymal lung disease.

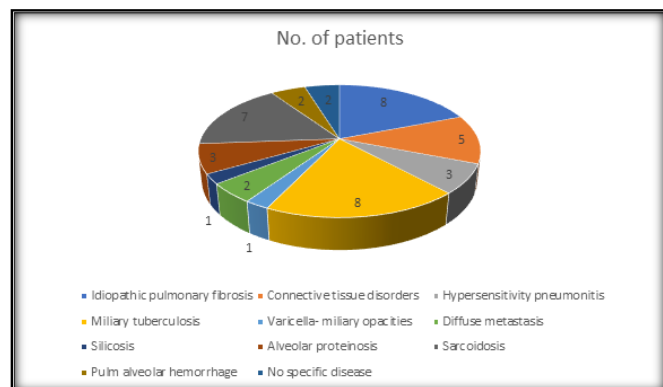
All the patients underwent clinical assessment, pulmonary function tests, conventional chest radiography, high resolution computed tomography and histopathological examination and the data was recorded on the proforma after informed consent. The patients were scanned using SIEMEN'S SOMATOM SENSATION 16 Slice Spiral CT Machine. Non-enhanced high resolution sequential axial scans of the chest with 1 mm collimation at a scan interval of 1 to 1.5 mm in full inspiration were obtained in each patient. The images were reconstructed using a high spatial frequency or bone algorithm. Images were evaluated in both mediastinum and lung window settings [Figure 1,2,3,4,5].

Observations were recorded in tabular form and results were compared. Statistical testing was conducted with the statistical package for the social science system version SPSS 17.0. Continuous variables are presented as mean ± SD, and categorical variables are presented as absolute numbers and percentage. The comparison of normally distributed continuous variables between the groups was performed using Student's t test. Nominal categorical data between the groups were compared using Chi-squared test or Fisher's exact test as appropriate. Sensitivity, specificity, PPV and NPV was calculated to analyze the diagnostic accuracy of Radiography, HRCT with the HPE as gold standard. For all statistical tests, p value less than 0.05 was taken to indicate a significant difference.

Results

Table 1: Age-wise distribution of cases

Age Group (Years)	No of male patients	Percentage of total male patients	No. of female patients	Percentage of total female patients
11-20	3	11.5%	0	0%
21-30	4	15.4%	0	0%
31-40	6	23.1%	3	18.8%
41-50	3	11.5%	5	31.3%
51-60	3	11.5%	2	12.5%
61-70	5	19.2%	3	18.8%
% 71-80	2	7.7%	3	18.8%
Total	26	100%	16	100%



Graph 1: Distribution of cases

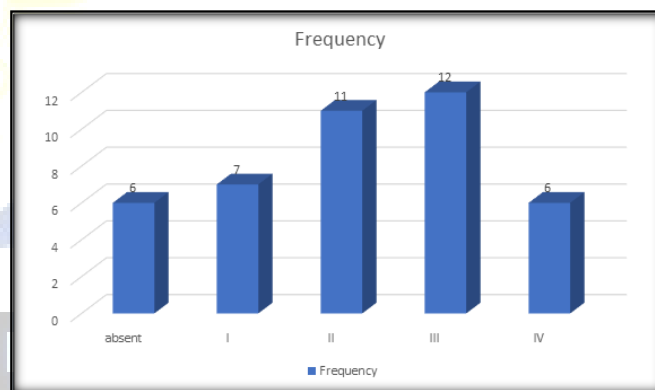
The most commonly identified diffuse parenchymal lung diseases were Idiopathic pulmonary fibrosis and Miliary tuberculosis, each comprising 19.1 % of the total number of

cases. The next most common group was of patients with Sarcoidosis, comprising of 16.7 % of the total cases. The difference was significant (P< 0.05) [Graph 1].

In the present study, 23.1% of total male patients belonged to the age group 31-40 years. Approximately 1/5th of total male patients, being 19.2 %, are in the age group 61-70 years. Of the female patients, 31.3% patients belong to the age group 41-50 years. Bulk of the female patients are between ages 31 to 50 making approximately 50% of total female patients [Table 1].

Table 2: Clinical symptoms present in the patients

Clinical symptom	Frequency	Percent
Dyspnea	36	85.7%
Cough – dry	31	73.8%
-productive	10	23.8%
Fever	15	35.7%
Chest pain	8	19.1%
Malaise	30	71.4%
Joint pain	4	9.5%
Hemoptysis	5	11.9%
Weight loss	5	11.9%
Occupational exposure	2	4.7%
Smoking history	13	30.9%



Graph 2: Grades of dyspnea

Dyspnea grade was absent in 6, Grade I in 7, grade II in 11, grade III in 12 and grade IV in 6 cases [Graph 2].

Table 3: Result of pulmonary function test

Pulmonary Function Tests	Frequency	Percent	
Forced Vital capacity	>80%	15	39.5%
	61-80%	17	44.7%
	41-60%	6	15.8%
	<40%	0	0%
% FEV1/FVC	>101%	14	36.8%
	81-100%	22	57.9%
	61-80%	2	5.3%
TLC	>80%	13	34.2%
	61-80%	20	52.6%
	41-60%	5	13.2%
Dlco	>80%	5	13.2%
	61-80%	21	55.3%
	41-60%	10	26.3%
	<40%	2	5.3%

Dyspnea was the most common presenting symptom in the patients and was present in 85.7% patients. Dry cough in

73.8%, 66.7% had dyspnea was associated with dry cough. Fever in 35.7% of total patients. Hemoptysis and weight loss in 11.9 % patients, each, and were seen in the patients of miliary tuberculosis, lung malignancies, both primary and secondary and in pulmonary hemorrhage. Chest pain in 19.1% and was mostly pleuritic in nature. Joint pains in 9.5%, Malaise in 71.4% patients and was found in patients with IPF, HP, sarcoidosis and tuberculosis [Table 2].

The most common abnormalities seen on spirometry are reduced FVC (44.7% patients had FVC value ranging between 61% to 80 %) and reduced TLC values (52.6% patients had TLC between 61% to 80%). The %FEV1/FVC is however maintained between 81% to 100% in 57.9% of

total number of cases. DLco could not be performed in four patients because of very low FVC [Table 3].

Table IV Result of 6- Min SPO2 walk test

Walk Test	SPO ²	Frequency	Percent
Pre-walk	>95%	26	61.9%
	<95%	12	28.5%
Post-walk	>95%	11	26.2%
	<95%	27	64.3%

The Post-walk SPO2 dropped to <95% in 64.3% of total patients in this study [Table 4].

Table 5: Correlation between Grades of Dyspnea and Histopathology

Dyspnea- grades	HPE Negative		HPE Positive		P Value
	Frequency	%	Frequency	%	
absent	0	0.0%	5	15.2%	0.513
I	0	0.0%	6	18.2%	
II	2	66.7%	8	24.2%	
III	1	33.3%	9	27.3%	
IV	0	0.0%	5	15.2%	
Total	3	100%	33	100%	

Table 6: Correlation between Radiographic Diagnosis and Histopathology

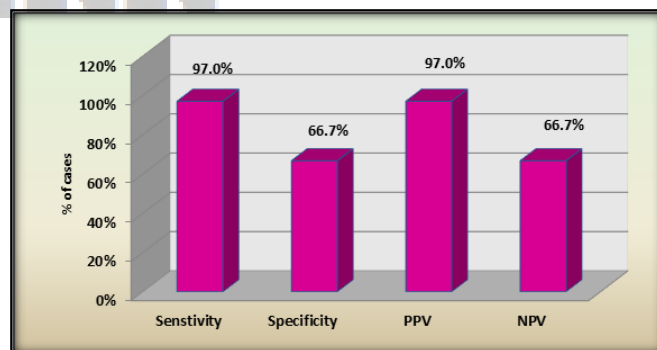
Diagnosis radiograph on	HPE Negative		HPE Positive		P Value
	Frequency	%	Frequency	%	
Negative	2	66.7%	13	39.4%	0.559
Positive	1	33.3%	20	60.6%	
Total	3	100%	33	100%	

Histopathological examination was performed in 36 patients who presented with dyspnea. Out of these, 33 patients with dyspnea had a positive finding of DPLD in histopathological examination, making 91.7% HPE positivity rate in patients with dyspnea. Maximum number of these had grade II and III dyspnea consisting of total 51.5% of HPE positive patients. The correlation between the grades of dyspnea and histopathological findings was not found to be significant [Table 5].

Approximately 60.6% cases had both positive findings of DPLD on radiography as well as histopathology. However, there were 13 cases (39.4%) in which the radiographs were normal, but the disease was confirmed after histopathological examination. 2 patients in whom the radiograph was normal, also had a negative histopathological examination and a final specific diagnosis could not be made in these patients. However, HPE was not confirmatory in one case who had abnormal radiograph of the chest. The correlation between histopathology and chest radiography was not found to be significant. (p value >0.05) [Table 6].

Table 7: Correlation between Diagnosis based on HRCT Chest and HPE

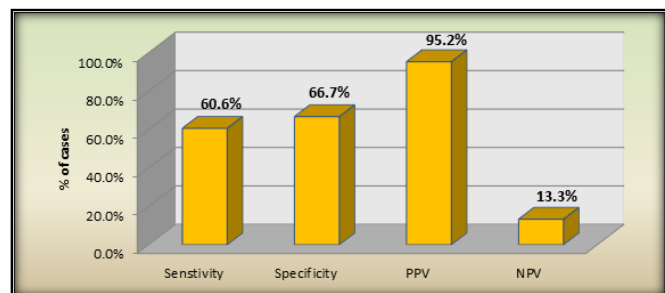
Diagnosis on HRCT	HPE Negative		HPE Positive	
	Frequency	%	Frequency	%
Negative	2	66.7%	1	3.0%
Positive	1	33.3%	32	97.0%
Total	3	100%	33	100%



Graph IV Evaluation of HRCT Chest in detection of DPLD

The sensitivity of chest radiography for detection of diffuse parenchymal lung disease was found to be 60.6% and specificity, 66.7%. The positive predictive value of chest radiography was found to be 95.2%, with a low negative predictive value of 13.3%. Chest radiography was used as the initial tool for screening the patients with suspicion of having diffuse parenchymal lung disease. The high positive predictive value of 95.2% and specificity of 66.7% was found [Graph 3].

In the present study, significant correlation was found between the diagnosis based on high resolution computed



Graph 3: Evaluation of Chest Radiography in DPLD

tomography and histopathological diagnosis with a p value of 0.014 (<0.05). Confirmatory diagnosis was made in 97% patients based on HRCT findings which was also confirmed on histopathological examination. In 33.3% patients, diagnosis of DPLD was made on HRCT, but was not confirmed on histopathological examination. On the contrary, only 3% of patients with normal HRCT chest had a positive diagnosis of DPLD on histopathology [Table 7].

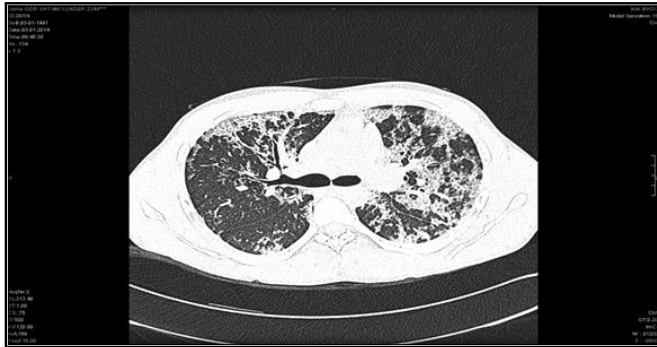

Figure 1: Axial HRCT chest in lung window setting shows patchy as well as confluent areas of ground glass with interlobular septal thickening giving a typical 'crazy paving' appearance suggestive of pulmonary alveolar proteinosis.

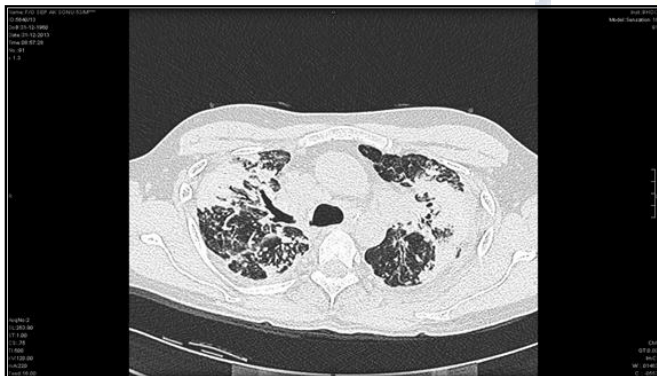

Figure 2: HRCT images show extensive nodular opacities in upper and middle lobes with conglomerate nodules, pleural thickening, fibrosis and architectural distortion suggestive of silicosis

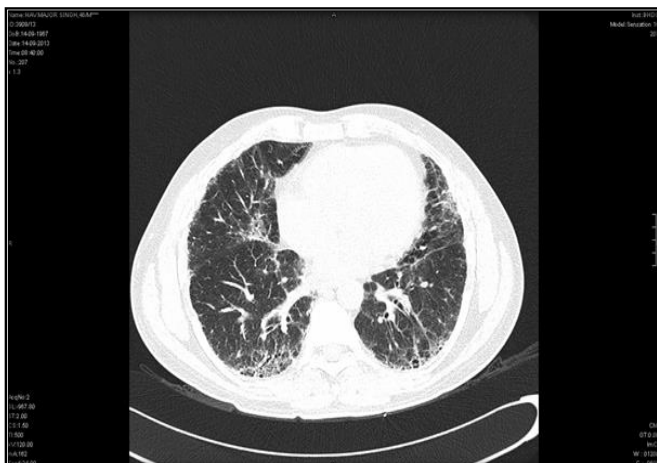

Figure 3: HRCT image shows subpleural areas of honeycombing and fibrotic opacities suggestive of IPF

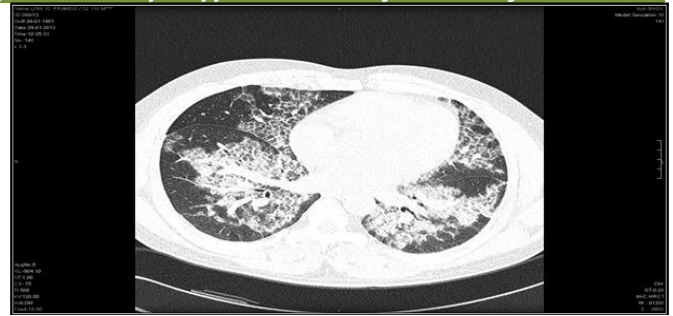

Figure 4: Axial HRCT chest image in lung window setting shows typical 'crazy paving' appearance suggestive of pulmonary alveolar proteinosis

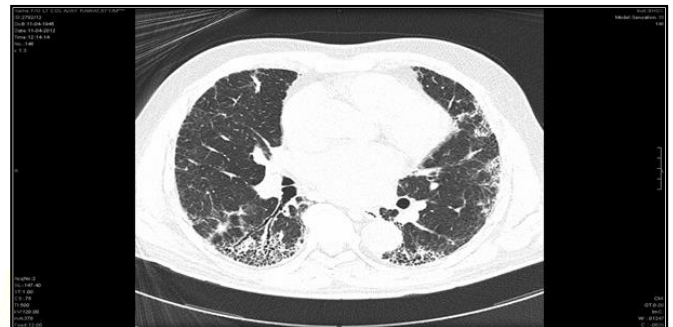

Figure 5: Subpleural areas of honeycombing with basal and peripheral predominance along with patchy areas of ground glass suggestive of idiopathic pulmonary fibrosis

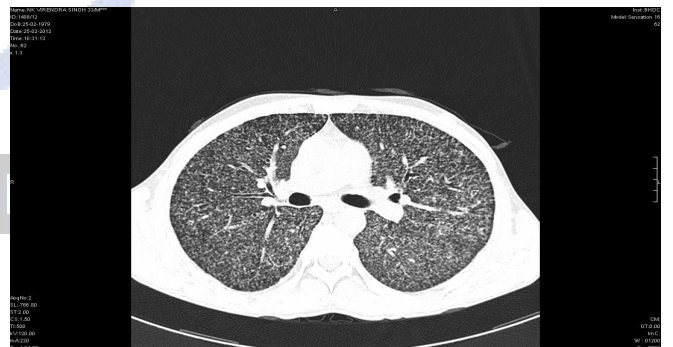


Figure 6: Extensive nodular opacities with random uniform distribution in both lung fields in a case of military tuberculosis

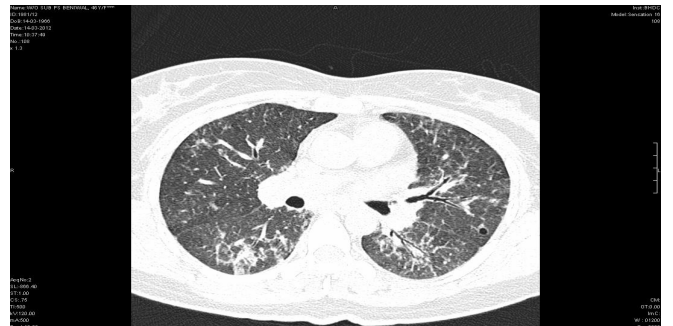


Figure 7. Peribronchovascular and subpleural tiny nodular opacities with patchy areas of ground glass suggestive of sarcoidosis.

In the present study, the sensitivity of HRCT for detection of diffuse parenchymal lung disease was found to be 97%

and specificity, 66.7%. The positive predictive value of HRCT was found to be 97%, with negative predictive value of 66.7%. In the present study, HRCT was found to have a high sensitivity and positive predictive value of 97%. The specificity and negative predictive value was found to be 66.7% [Graph 4].

Discussion

The present study was done to evaluate the clinico-radiological profile of diffuse parenchymal lung diseases using high-resolution computed tomography in our hospital set up. Forty-two patients with suspected clinical diagnosis of DPLD and referred for thoracic CT were included in the study.

The most common diffuse parenchymal lung diseases encountered in our study group were idiopathic pulmonary fibrosis (IPF) and miliary tuberculosis, each accounting for 19.1% of cases. Sarcoidosis also formed a major group of total 7 cases constituting 16.7% of cases.

The mean age of the patients in our study was 47.5 years with male preponderance (61.9%). Most of the patients presented in the 4th and 5th decades of life. Dyspnea was the main presenting complaint in 85.7% of our study group. 54.8% of our patients had either grade II or grade III dyspnea at the time of presentation whereas 14.3% presented with grade IV dyspnea.

35.7% of our patients had fever at the time of presentation. It was the predominant symptom in all the cases of miliary tuberculosis and 3 cases of sarcoidosis (42.8%). 19.1% of our patients had chest pain at presentation. The other constitutional symptoms of malaise (71.4%) and joint pains (9.5%) were more frequently found in patients with connective tissue disorders and sarcoidosis. Various authors have tried to establish the relationship between a history of smoking and diffuse lung diseases. Ryu et al described four lung disorders linked to smoking – desquamative interstitial pneumonia, respiratory bronchiolitis-associated lung disease, pulmonary langerhan cell histiocytosis and idiopathic pulmonary fibrosis.^[13]

The most common abnormalities seen on spirometry were reduced FVC (44.7% patients had FVC value ranging between 61% to 80%) and reduced TLC values (52.6% patients had TLC between 61% to 80%). The %FEV1/FVC is however maintained between 81% to 100% in 57.9% of total number of cases. The Post-walk SPO2 dropped to <95% in 64.3% patients in this study.

In this study, DLCo was found as the most sensitive indicator of diffuse parenchymal lung disease with a mean value of 68.64%. The mean value of DLco in patients with IPF was 60.3% and in patients with sarcoidosis was 70%. The mean value of FVC was 76.8% and that of TLC was 79.7% in the present study. Koegh et al,^[14] in their series reported the mean value of FVC as 66%, TLC 63.2% and DLCo 59%.

Chest radiography was used as the initial tool for screening the patients with suspicion of having diffuse parenchymal lung disease. Approximately 57.1% patients had positive findings suggestive of DPLD on chest radiography.

However, there was strikingly high percentage of patients, approximately 42.9% of total number of patients, who were strongly suspected to have been suffering from DPLD, but had normal chest radiograph on initial radiographic assessment. The sensitivity of chest radiography for detection of diffuse parenchymal lung disease was found to be 60.6% and specificity, 66.7%. The positive predictive value of chest radiography was found to be 95.2%, with a low negative predictive value of 13.3%.

All the patients underwent High Resolution Computed Tomographic examination of Chest. Out of total 42 patients, 39 patients were detected to have the disease and final diagnosis could be made in approximately 92.9% patients. In the present study, significant correlation was found between the diagnosis based on high resolution computed tomography and histopathological diagnosis with a p value of 0.014 (<0.05). Confirmatory diagnosis was made in 97% patients based on HRCT findings which was also confirmed on histopathological examination. In 33.3% patients, diagnosis of DPLD was made on HRCT, but was not confirmed on histopathological examination. On the contrary, only 3% of patients with normal HRCT chest had a positive diagnosis of DPLD on histopathology.

Histopathological examination was performed in 36 patients who presented with dyspnea. Out of these, 33 patients with dyspnea had a positive finding of DPLD in histopathological examination, making 91.7% HPE positivity rate in patients with dyspnea.

Conclusion

Diffuse parenchymal lung diseases commonly occur in middle age group, the presenting complaint being unremitting dyspnea of long duration in most cases. HRCT is very sensitive tool for detection of diffuse parenchymal lung disease with a high positive predictive value. The present study concludes that high resolution computed tomography is an invaluable tool in the diagnosis and characterisation of diffuse parenchymal lung diseases in an appropriate clinical setting.

References

1. Anthony A. Gal, MD1 and Gerald W. Staton, Jr, MD2. Current Concepts in the Classification of Interstitial Lung Disease. In: Am J Clin Pathol 2005;123(Suppl 1):S67-S81.
2. Aryeh Fischer, Sterling G. West, Jeffrey J. Swigris, Kevin K. Brown, Roland M. du Bois. Connective Tissue Disease- Associated Interstitial Lung Disease: A Call for Clarification. In: Chest. 2010;138(2):251-256.
3. Heard BE. Pathology of interstitial lung diseases with particular reference to terminology, classification and trephine lung biopsy. In: Chest. 1976;69:252.
4. Schwartz DA, Van Fossen DS, Davis CS, Helmers RA, Dayton CS, Burmeister LF, et al. Determinants of progression in IPF. In: Am J Respir Crit Care Med. 1994 Feb;149:444-9.
5. Gharaee-Kermani M, Gyetko MR, Hu B, Phan SH. New insights into the pathogenesis and treatment of idiopathic pulmonary fibrosis: a potential role for stem cells in the lung parenchyma and implications for therapy. In: Pharm Res. 2007 May;24(5):819-41.
6. Hashimoto N, Jin H, Liu T, Chensue SW, Phan SH. Bone marrow-derived progenitor cells in pulmonary fibrosis. In: J Clin Invest. 2004;113:243-252.

Sharma et al; High Resolution Computed Tomography Patterns of Diffuse Parenchymal Lung Diseases

- Eric B Meltzer and Paul W Noble. Idiopathic pulmonary fibrosis. In: Orphanet J Rare Dis. 2008; 3: 8.
- Hartman TE, Primack SL, Hansell DM, Muller NL. End-stage lung disease: CT findings in 61 patients. In: Radiology. 1993;189:681-86.
- Crystal RG, Fulmer JD, Roberts WC: Idiopathic pulmonary fibrosis: Clinical, Histologic, Radiographic, Physiologic and scintigraphic aspects. In: Ann Intern Med.1976;85:769-88.
- Colby TV, Carrington CB. Lymphoreticular tumors and infiltrates of the lung. In. Pathol Ann. 1983;18:27-70
- Soler P, Morean A, Besset F. Cigarette smoking induced changes in the number and differentiated state of pulmonary Langerhan's cells. In: Am Rev Respir diseases. 1989;139:1112-17.
- Kanematsu T, Masanori Kitaichi, Koichi Nishimura, Sonoko Nagai and Takateru izumi. Clubbing of the fingers and smooth-muscle proliferation in fibrotic changes in the lung in patients with idiopathic pulmonary fibrosis. In: Chest 1994;105 (2) Feb :339-42.
- J.H. Ryu, T.V. Colby, T.E. Hartman and R. Vassallo. Smoking related interstitial lung diseases: A concise review. In: Eur Respr Journal.2001;17:122-32.
- Koegh BA, Crystal RG. Clinical significance of pulmonary function tests in interstitial lung disease. In: Chest. 1980 Dec; 78 (6):856-65.

Copyright: © the author(s), publisher. Asian Journal of Medical Radiological Research is an Official Publication of “Society for Health Care & Research Development”. It is an open-access article distributed under the terms of the Creative Commons Attribution Non-Commercial License, which permits unrestricted non-commercial use, distribution, and reproduction in any medium, provided the original work is properly cited.

How to cite this article: Sharma R, Chand S, Singh S. High Resolution Computed Tomography Patterns of Diffuse Parenchymal Lung Diseases with Clinical and Pathological Correlation. Asian J. Med. Res. 2018;6(2):39-44.
DOI: [dx.doi.org/10.21276/ajmrr.2018.6.2.11](https://doi.org/10.21276/ajmrr.2018.6.2.11)

Source of Support: Nil, **Conflict of Interest:** None declared.

