

## A Study of the Relationship between USG and MRCP Findings in Biliary and Pancreatic Pathologies

Rajender Kumar<sup>1</sup>

<sup>1</sup>Assistant Professor, Department of Radiology, World College of Medical Sciences Research and Hospital, Jhajjar Haryana, India.

### Abstract

**Introduction:** The most common type of hepato-biliary pathology is obstructive jaundice. The aim of this study was to assess the diagnostic accuracy of two non-invasive modalities, ultrasound (USG) and magnetic resonance cholangiopancreatography (MRCP). Cases were investigated further. ERCP, surgical findings, and histopathology correlation all contributed to the diagnosis. **Subjects and Methods:** A total of 45 patients, 23 male and 22 female, ranging in age from 5 to 74 years, came with epigastric pain, decreased appetite, nausea, vomiting, fever with chills, and yellow skin and sclera. Ultrasound was performed on the patients, followed by MRCP. This study comprised patients of all ages, genders, and professions who had USG and MRCP and had strong clinical and lab evidence of biliary blockage. **Results:** In the study population, the accuracy of diagnosis of USG versus MRCP results in biliary and pancreatic diseases. In 31 (68.9%) cases, the reason of biliary blockage was benign, while in 14 cases, the cause was malignant (31.1%). Choledocholithiasis (26.9%) was the most prevalent benign obstruction, while periampullary carcinoma was the most common malignant obstruction (42.9%). **Conclusion:** In pancreaticobiliary diseases, MRCP is a better noninvasive approach than ultrasound. MRCP is a non-invasive, radiation-free method of evaluating the pancreaticobiliary tree. Multiplanar imaging and 3D reproduction are both possible with MRCP. Ultrasound is a non-invasive, non-radioactive technique.

**Key Words:** Pancreatic duct, Malignant, Benign, USG & MRCP.

### INTRODUCTION

Obstructive jaundice is the most severe and persistent kind of hepatobiliary illness. It can cause problems with analysis and the board, particularly intrahepatic cholestasis. As a result, it is critical to determine the presence, nature, and location of block prior to surgery, because a poorly chosen helpful technique can be dangerous. Ultrasound is used as the underlying technology to confirm or disprove channel block, and it does so with at least 90% accuracy.<sup>[1,2]</sup> However, USG is subject to the administrator and has a limit in patients with obesity and a large amount of internal gas. Computed tomography (CT) is a reliable method for interpreting damage and gaining a better understanding of the full extent of pancreatic pathology. MRCP has put a cap on the amount of CT that can be used.<sup>[3,4]</sup> MRCP technologies have advanced to the point that they may produce high-resolution images of the biliary tree in a short amount of time while being non-invasive and requiring no contrast material injection. The results were compared to other imaging modalities (US, CT scan, and regular radiographs obtained during PTC or ERCP) and it was concluded that MR cholangiopancreatography has the ability to provide noninvasive imaging of the biliary tree in patients with obstructive jaundice. However, method improvements are expected to overcome the limited spatial goal and low signal to commotion ratio.<sup>[5]</sup> The purpose of this study was to assess the diagnostic accuracy of two non-invasive modalities, ultrasound (USG) and magnetic resonance cholangiopancreatography (MRCP). Cases were investigated further. ERCP, surgical

findings, and histopathology correlation all contributed to the diagnosis.

### MATERIALS AND METHODS

From April, 2016 to May 2017, the current study was carried out in the Department of Radiology, World College of Medical Sciences Research and Hospital, Jhajjar Haryana, India. A total of 45 patients, 23 male and 22 female, ranging in age from 5 to 74 years, came with epigastric pain, decreased appetite, nausea, vomiting, fever with chills, and yellow skin and sclera. Ultrasound was performed on the patients, followed by MRCP. This study comprised patients of all ages, genders, and professions who had USG and MRCP and had strong clinical and lab evidence of biliary blockage. The patient signed a written informed consent form. The institutional ethical committee gave its approval to the research. The researchers used a Philips Affiniti 70 ultrasound machine with a 3.5-5 MHz curvilinear probe. In the investigation of biliary obstructive disease, ultrasound has long been regarded the method of choice. Ultrasound is non-invasive, easily accessible, quick, simple, and inexpensive. It has a high level of sensitivity, specificity, and consistency. However, USG is operator-dependent and has limitations in obese and gaseous distended patients. MRCP examinations were performed based on a standardised methodology. A non-invasive cross-sectional MRI imaging approach for the biliary system is magnetic resonance cholangiopancreatography (MRCP). MRCP produces high-resolution pictures of the biliary tract. The underlying idea of MRCP is that bodily fluids have a high signal intensity (i.e., they seem bright) on strongly T2-weighted magnetic resonance sequences, whereas background tissues have a low signal intensity (i.e., they appear dark) (i.e., they appear dark). This approach is a non-invasive imaging technique that is very sensitive and specific for the diagnosis of biliary diseases when

#### Address for correspondence\*

Dr. Rajender Kumar,

Assistant Professor,

Department of Radiology,

World College of Medical Sciences Research and Hospital,

Jhajjar Haryana, India

Email: drrajenderchauhan@gmail.com

used in conjunction with MR images of the abdomen. It generates high-quality cross-sectional images of the biliary system as well as projection images of the biliary tree that resemble those acquired by invasive radiography procedures like endoscopic retrograde cholangiopancreatography (ERCP) and percutaneous transhepatic cholangiography (PTC). The information gathered was coded and entered into a Microsoft Excel 2010 spreadsheet. The statistic equations were used to determine the diagnostic accuracy.

## RESULTS

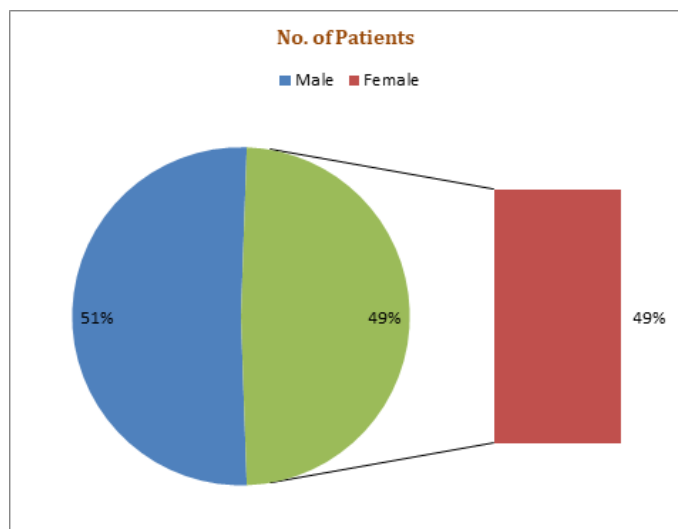


Figure 1: Shows the sex distribution.

**Table 1: Distribution Cases as per USG and MRCP diagnosis**

Causes	USGN=45(%)	MRCPN=45(%)
<b>Malignant</b>		
Periampullary Ca	4(57.1%)	6(42.9%)
Pancreatic Ca	3(42.9%)	4(28.6%)
Klatskintumor	0(0.0%)	4(28.6%)
<b>Benign</b>		
Benign stricture	0(0.0%)	6(23.1%)
Choledocholithiasis	5(25.0%)	7(26.9%)
Choledochal cyst	4 (20.0%)	5(19.2%)
Pancreatic pseudocyst	2(10.0%)	2(7.7%)
Benign mass	2(10.0%)	2(10.0%)
Physiological dilatation of the CBD	6(30.0%)	5(19.2%)
Others	1(5.0%)	1(3.8%)
Inconclusive	18(40.0%)	3(6.7%)
Total	45(100.0%)	45(100.0)

There were 45 patients in all, with 23 (51.1%) being male and 22 (48.9%) being female in [Figure 1]. Half of the patients were between the ages of 49 and 74. In the study population, the accuracy of diagnosis of USG versus MRCP results in biliary and pancreatic diseases is shown in [Table 1]. In 31 (68.9%) cases, the reason of biliary blockage was benign, while in 14 cases, the cause was malignant (31.1 percent). Choledocholithiasis (26.9%) was the most prevalent benign obstruction, while periampullary carcinoma was the most common malignant obstruction (42.9 percent). Pancreatic

pseudocyst, a benign growth, and a Klatskintumour were the least common causes. On ultrasound, eighteen instances were inconclusive, whereas three MRCP cases were falsely positive for cancer. MRCP was 92.2 percent accurate in determining the aetiology. The accuracy of USG was 55.4 percent. With a positive predictive value of 92.6 percent and a negative predictive value of 44.2 percent, the overall sensitivity and specificity were 86.4 percent and 64.2 percent, respectively.

## DISCUSSION

In terms of patient consideration and the executives, diagnosing patients with suspected biliary or pancreatic disorders in the early stages is critical. Information on the benefits and downsides of each technique is expected to be used to determine the best course of treatment for patients with these illnesses. To assess an occurrence of obstructive jaundice, a thorough understanding of biliary life structures and pathology is required. Our investigation consists of 45 patients. In all of the patients, USG and MRCP were performed. Correct upper quadrant and epigastric pain, tingling, yellowish staining of skin and sclera, queasiness, regurgitation, torment in midsection (limited or diffuse), and fever with chills were the most typical indications patients reported for biliary diseases. The youngest patient in our evaluation was 2 years old, while the oldest was 74 years old. Adults aged 49 to 74 years old had the highest number of patients, while those aged less than 10 years old had the lowest number. Our findings are consistent with those of Singh APK et al in 2015, who observed that the majority of the cases were in the 51-60 year age range.<sup>[5]</sup> Male predominance was observed in our investigation. Our findings are consistent with those of Sutar et al. (2015), who reported that biliary obstructive illnesses are more prevalent in men than in women.<sup>[6]</sup> In our analysis, the most common cause of obstructive jaundice was benign in 68.9% of patients. Choledocholithiasis is the most prevalent benign cause (31.1 percent). Pancreatic pseudocyst and benign mass were the least common causes. Periampullary carcinoma was the most prevalent malignant aetiology, while Klatskintumour was the least common. There were four cases of CBD dilatation on USG and MRCP, two of which were post-cholecystectomy and one of which showed physiological dilatation on USG and MRCP. On MRCP, periampullary Ca was the most common malignant aetiology of obstructive jaundice, while cholangiocarcinoma was the least common. On USG, periampullary Ca was shown to be the most prevalent malignant cause of obstructive jaundice, while choledocholithiasis was found to be the most common benign cause. In 40.0 percent of cases, ultrasound was inconclusive. CBD calculi were seen on MRCP imaging of benign lesions in four individuals, while USG imaging revealed the same in five patients. CBD calculi were detected with 100% accuracy using MRCP. The MRCP revealed calculus in CBD as a signal void. My findings are consistent with those of Munir et al. in 2004 and Bhatt C et al. in 2005, who reported that MRCP was 100 percent accurate in identifying CBD calculus.<sup>[7]</sup> In all seven cases, MRCP revealed the benign nature of the stricture with near-perfect accuracy. None of the strictures were diagnosed by USG. Our findings are consistent with those of Bhatt et al and Safa Al-Obaidi et al in 2007, who demonstrated that MRCP

was 100 percent accurate in detecting benign CBD strictures.<sup>[8,9]</sup> MRCP was 100 percent accurate in diagnosing all five cases of choledochal cysts, whereas USG was accurate in four of the five cases. Our findings are in line with those of Bhatt et al and Singh et al, who found that MRCP was 100 percent accurate in diagnosing choledochal cysts in 2015. MRCP was performed on them, and they were found to be benign. Periapillary growth was found in 6 of the 14 instances. MRCP detected periapillary growth in six of the seven, which was confirmed by histology. On MRCP, one patient was diagnosed with periapillary growth, however histopathology revealed that it was benign. One instance was found to have a retroperitoneal mass. Periapillary carcinoma was shown to be the cause of the nodal mass squeezing the CBD. Only four out of seven instances were found to have periapillary carcinoma on USG. Our findings are consistent with those of Kushwah et al. The accuracy of MRCP and USG in diagnosing periapillary growth was found to be 98 percent in their study. MRCP correctly detected three cases of pancreatic cancer (100 percent). An MRCP revealed a distal CBD stricture in one patient, which was later diagnosed as pancreatic cancer on histology. USG diagnosed only one of the three instances. On MRCP, one of the cases was misdiagnosed as pancreatic cancer, but histopathological correlation revealed no malignancy. In 2016, Diwanji et colleagues used MRCP to correctly detect pancreatic cancer (100 percent).<sup>[10]</sup> In a 2003 control study, Zhong et al discovered that USG and MRCP were 63 percent and 90 percent accurate in identifying pancreatic head cancer, respectively.<sup>[11]</sup> In the case of biliary blockage, USG is the first line of defence, whereas MRCP provides a more accurate diagnosis with fewer false positives. In lower CBD blockages, USG has intrinsic downsides and limits that affect diagnostic accuracy. When it comes to detecting CBD and pancreatic duct diseases, MRCP is far more accurate, and it aids in the decision-making process. It directs the surgeon performing the ERCP, reducing the number of "negative" ERCPs.<sup>[12]</sup> In patients with suspected biliary blockage, MRCP has demonstrated similar results to ERCP. MRCP is the best diagnostic technique in patients who cannot undergo an endoscopic procedure (prior biliary enteric anastomosis, previous partial gastrectomy, etc.).<sup>[13]</sup> which is comparable to the findings of Bhatt C et,<sup>[14]</sup> al investigation. Using 100 patients, Upadhyaya V et al,<sup>[15]</sup> did another study on MR cholangiopancreatography, which indicated improved results in recognising the reason of obstruction and was second only to ERCP in determining the level of biliary obstruction. In this study, MRCP had the highest accuracy of 92.2 percent in diagnosing hepatobiliary and pancreatic diseases, while USG had 55.4 percent accuracy. With a positive predictive value of 92.6 percent and a negative predictive value of 44.2 percent, the total sensitivity and specificity were 86.4 percent and 64.2 percent, respectively.

## CONCLUSION

These findings imply that in pancreaticobiliary diseases, MRCP is a better noninvasive approach than ultrasound. MRCP is a non-invasive, radiation-free method of evaluating the pancreaticobiliary tree. Multiplanar imaging and 3D reproduction are both possible with MRCP. Ultrasound is a non-invasive, non-radioactive technique. It is less expensive, more easily available, and takes less time.

Because of its symptomatic precision, MRCP may be able to replace or limit the usage of invasive techniques as analytic ERCP. By taking tissue samples, endoscopic retrograde cholangiopancreatography (ERCP) aids in the portrayal of the injury.

## REFERENCES

1. Bhargava SK, Usha T, Bhatt S, Kumari R, Bhargava S. Imaging in obstructive jaundice: A review with our experience. *JIMSA*. 2013;26:12-4.
2. Siva Prasad A, Sandeep J. Ultrasound and magnetic resonance cholangio-pancreatography correlation in biliary disorders. *MRIMS*. 2015;3(2).
3. Singh A, Mann HS, Thukral CL, Singh NR. Diagnostic Accuracy of MRCP as Compared to Ultrasound/CT in Patients with Obstructive Jaundice. *Journal of Clinical and Diagnostic Research*. 2014;8:103-107.
4. Kim JH, Kim MJ, Park SI, Chung JJ, Song SY, Yoo HS, Lee JT. Using kinematic MR cholangiopancreatography to evaluate biliary dilatation. *American J Roentgenol*. 2002;178(4):909-14.
5. Kushwah AP, Jain S, Agarwal R, Tomar SP. Biliary tract obstructive diseases: a comparative evaluation by ultrasonography and magnetic resonance cholangiopancreatography (magnetic resonance imaging). *Int J Sci Study*. 2015;3(4):149-53.
6. SuthaR M, PuRohit S, BhaRgaV V, Goyal P. Role of MRCP in differentiation of benign and malignant causes of biliary obstruction. *JCDR*. 2015 Nov;9(11):TC08.
7. Munir K, Bari V, Yaqoob J, Khan DB, Usman MU. The role of magnetic resonance cholangiopancreatography (MRCP) in obstructive jaundice. *J Pak Med Assoc*. 2004;54(3):128-32.
8. Bhatt C, Shah PS, Prajapati HJ, Modi J. Comparison of diagnostic accuracy between USG and MRCP in biliary and pancreatic pathology. *Indian J Radiol Imaging*. 2005;15(2):177.
9. Al-Obaidi S, Al-Hilli MR, Fadhel AA. The role of ultrasound and magnetic resonance imaging in the diagnosis of obstructive jaundice. *Iraqi Postgrad Med J*. 2007;6(1):7-17.
10. Diwanji N, Dibbad RB, Sastri M, Desai E. The study of role of magnetic resonance cholangiopancreatography (MRCP) in pancreato-biliary disorders. *Int J Med Sci Public Health*. 2016;5(12):2635-40.
11. Zhong L, Yao QY, Li L, Xu JR. Imaging diagnosis of pancreato-biliary diseases: a control study. *World J Gastroenterol*. 2003;9(12):2824.
12. Hazem ZA. Acute Biliary Pancreatitis: Diagnosis and Treatment. *Saudi J Gastroenterol*. 2009;15:147-155.
13. Adamek HE, Albert J, Breer H, Weitz M, Schilling D, Riemann JF. Pancreatic cancer detection with magnetic resonance cholangiopancreatography and endoscopic retrograde cholangiopancreatography: a prospective controlled study. *Lancet*. 2000;356(9225):190-3.

14. Bhatt C, Shah PS, Prajapati HJ, Modi J et al. Comparison of Diagnostic Accuracy between USG and MRCP in Biliary and Pancreatic Pathology. *Ind J RadiolImag.* 2005; 15:177-181.
15. Upadhyaya V, Upadhyaya DN, Ansari MA, Shukla VK. Comparative assessment of imaging modalities in biliary obstruction. *Ind J RadiolImag.* 2006;16:577-582.