

Role of High Resolution Computed Tomography in Characterization of Interstitial Lung Disease in Rural Tertiary Care Centre

Y. Ravi Kumar¹, P Jenikar², M. Sanjeev Kumar³

¹Consultant Radiologist, Department of Radio-diagnosis, Apollo Hospitals, Visakhapatnam, Andhra Pradesh, India, ²Assistant Professor, Department of Radio-diagnosis, Shri Sathya Sai Medical College and Research Institute, Ammapettai, Chengalpattu, Tamilnadu, India, ³Assistant Professor, Department of Radio Diagnosis, PES Institute of Medical Sciences and Research, Kuppam, Andhra Pradesh, India.

Abstract

Background: The Interstitial lung disease (ILD) are a group of diffuse parenchymal lung diseases that share many features but are sufficiently different from one another to be designated as separate disease entities. HRCT (High Resolution Computed Tomography) is particularly helpful in and diagnosing and characterizing these entities. **Subjects and Methods:** Data for the study collected from patients clinically suspected to have interstitial lung disease. Sample size: 31 patients. Study period: 2yrs. Study design: Prospective and Observational study. Inclusion criteria: Suspected cases of diffuse parenchymal lung disease by clinical history, physical examination, radiographic findings and appropriate laboratory investigations. Cases of all age groups irrespective of sex. Exclusion criteria: Known cases of lung malignancies and previously treated cases of diffuse parenchymal lung disease are excluded from the study. **Results:** In a period of 2yrs study, 31 patients were diagnosed as ILDs on HRCT chest imaging. Among 31 cases most of them were IPF/UIP (35%), followed by AIP (16%). Honey combing is predominantly confined to UIP/IPF (100%), Traction bronchiectasis is predominantly seen in UIP/IPF (68%), Ground glass opacity is mostly seen in NSIP (23%) followed by AIP. Reticular opacities are predominantly seen in UIP/IPF (45%) followed by NSIP (18%). Consolidation is predominantly seen in HP (30%) and COP (30%). Septal thickening is predominantly seen in UIP/IPF (45%) followed by NSIP (18%). **Conclusion:** HRCT is the most sensitive tool for non-invasive imaging of the lung parenchyma in patients with suspected ILD.

Keywords: HRCT, ILDs, UIP, NSIP, Silicosis.

Corresponding Author: P Jenikar, Assistant Professor, Department of Radio-diagnosis, Shri Sathya Sai Medical College and Research Institute, Ammapettai, Chengalpattu, Tamilnadu, India.
E-mail: drjenikar@gmail.com

Received: 04 June 2021

Revised: 16 August 2021

Accepted: 29 August 2021

Published: 24 December 2021

Introduction

The Interstitial lung disease (ILD) are a group of diffuse parenchymal lung diseases that share many features but are sufficiently different from one another to be designated as separate disease entities. HRCT (High Resolution Computed Tomography) is particularly helpful in characterizing and diagnosing these entities.

Conventional computed tomography uses thick sections resulting in a reduction of the ability to resolve small structures due to volume averaging.

High resolution computed tomography (HRCT) uses thin collimation, provides anatomical details similar to that available from gross pathological specimens and also allows reconstruction of images.

Advances in HRCT scanning have allowed an accurate diagnosis obviating the need for surgical biopsy in many patients. Furthermore, HRCT scanning may aid in determining prognosis and identifying disease progression.^[1]

Aims and Objectives

To evaluate the role of high resolution computed tomography in interstitial lung disease.

To characterize and classify various ILD according to their HRCT appearance.

Subjects and Methods

Source of data: Data for the study collected from patients referred to the department of Radio Diagnosis, PESIMSR, Kuppam, clinically suspecting ILD.

Study design: Prospective and Observational study.

Sample size: 31 Patients.

Period of Study: 2 years.

Equipment- GE Bright Speed Elite 16 Slice CT Scanner.

Permission from the Institutional ethical committee was obtained prior to the study and informed consent of study objects was taken before HRCT chest was done.

HRCT chest protocol:

Slice thickness: 1.25 mm

Reconstruction slice thickness: 0.625mm

Scan time: 0.8 second.

KVp: 120-140.

mAs: 100-200

Collimation: 1.5-3 mm

Matrix size: 512x512

FOV: 35 cm

Reconstruction algorithm: High spatial frequency (Bone algorithm).

Window: Lung window

Position: Usually supine, but prone scans were obtained wherever needed.

Level of respiration: Suspended full inspiration. When air trapping was suspected, expiratory images were also taken.

Superior extent: Lung apices.

Inferior extent: Domes of diaphragm.

Inclusion criteria

Suspected cases of diffuse parenchymal lung disease by clinical history, physical examination, radiographic findings and appropriate laboratory investigations.

Cases of all age groups irrespective of sex.

Exclusion criteria

Known cases of lung malignancies and previously treated cases of diffuse parenchymal lung disease are excluded from the study.

Patients who are pregnant or lactating at the time of study.

Patients who are unwilling to give informed consent.

Results

In our study group which included total number of 31 patients the results were as follows.

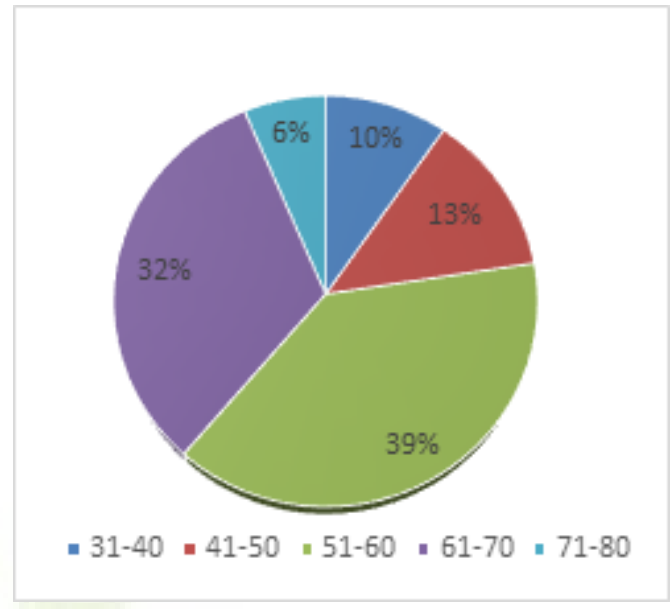


Chart 1: Age distribution of patients with ILDs

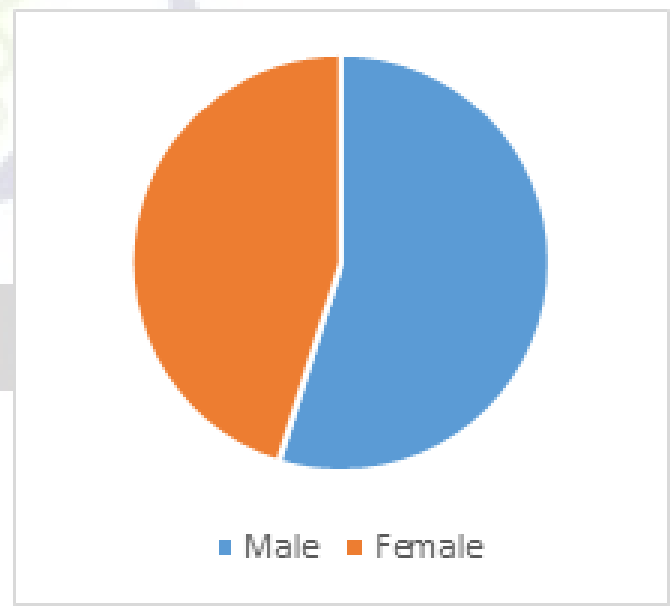


Chart 2: Gender distribution of patients with ILD

Discussion

In our study, total number of patients who were diagnosed based on HRCT findings as interstitial lung diseases were 31.

Out of 31 patients in our study, most of the patients were of 51-60yrs age group (38.7%), followed by 61-70yrs (32.2%), 41-50yrs (12.9%), 31-40yrs (9.6%) and 71-80yrs (6.4%).

Table 1: Lobar distribution of ILDs

ILD	UL	ML/LINGULAR LOBE	LL	DIFFUSE
UIP/IPF	0	5 (55.5%)	10 (55.5%)	1 (12.5%)
NSIP	0	1 (11.1%)	4 (22.2%)	0
AIP	1 (16.6%)	1 (11.1%)	0	4 (50%)
HP	1 (16.6%)	0	1 (5.5%)	2 (25%)
COP	1 (16.6%)	1 (11.1%)	3 (16.6%)	0
SILICOSIS	3 (50%)	1 (11.1%)	0	1 (12.5%)
Total	6	9	18	8

ILD-Interstitial lung disease. UL-upper lobe, ML-middle lobe, LL-lower lobe.

Table 2: HRCT findings in the ILDs among study group

	UIP/IPF	NSIP	AIP	HP	COP	Silicosis	Total
HC	11(100%)	0	0	0	0	0	11
TB	11(68.7%)	2(2.5%)	0	1(6.25%)	1(6.2%)	1(6.2%)	16
GG	2(11.7%)	4(23.5%)	4(23.5%)	3(17.6%)	3(17.6%)	1(5.8%)	17
NO	1(12.5%)	0	0	2(25%)	0	5(62.5%)	8
RO	10(45.5%)	4(18.1%)	2(9%)	1(4.5%)	1(4.5%)	4(18.1%)	22
CON	2(20%)	0	3(30%)	0	3(30%)	2(20%)	10
ST	10(45.5%)	4(18.1%)	2(9%)	1(4.5%)	1(4.5%)	4(18.1%)	22
LN	6(28.5%)	1(4.7%)	4(19%)	2(9.5%)	3(14.2%)	5(23.8%)	21

HC: Honey Combing, TB: Traction bronchiectasis, GG: Ground glassing, NO: Nodular opacities, RO: Reticular opacities, CON: Consolidation, ST: Septal thickening, LN: Lymphadenopathy.

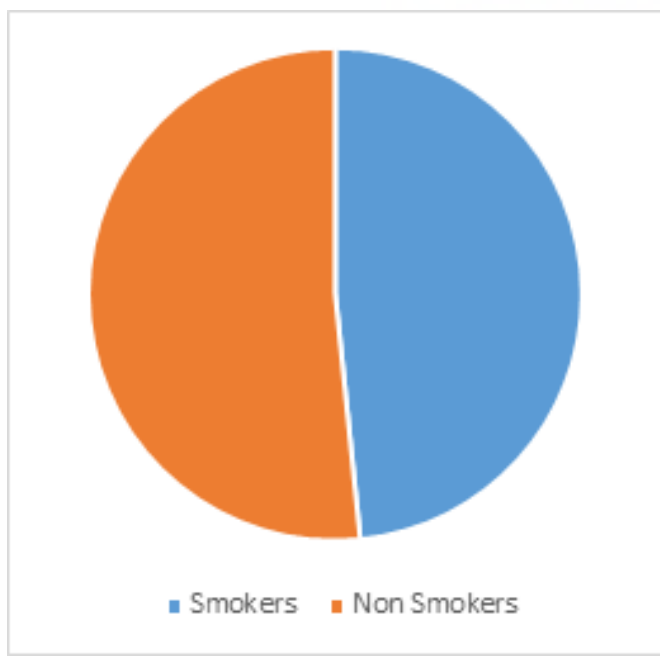


Chart 3: Tobacco smokers & non-smokers

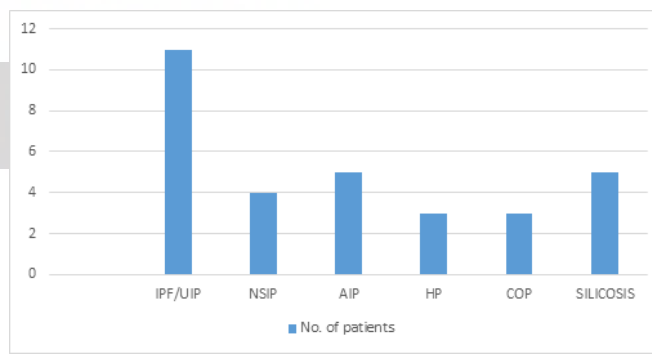


Chart 4: Distribution of ILD [IPF/UIP (Idiopathic Pulmonary Fibrosis/Usual Interstitial Pneumonia), NSIP (Non Specific Interstitial Pneumonia), AIP (Acute Interstitial Pneumonia), HP (Hypersensitivity Pneumonia), COP (Cryptogenic Organising Pneumonia)].

Patients were males (54.8%) and 14 patients were females (45.16%)

Patients (48.3% were tobacco smokers and 16 patients (51.61%) were non tobacco smokers

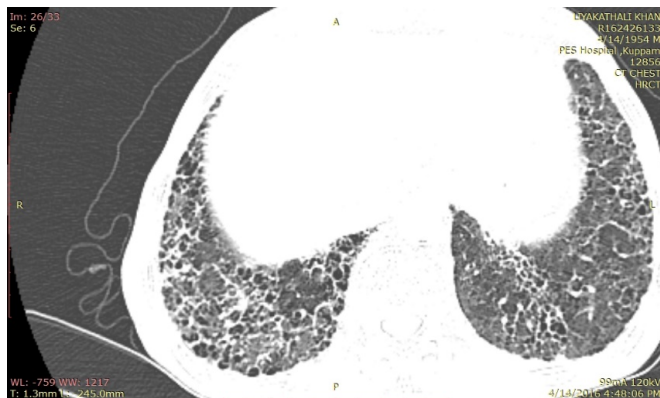


Figure 1: A case of UIP. Axial section HRCT lung image showing honey combing and traction bronchiectasis involving bilateral lower lobes.

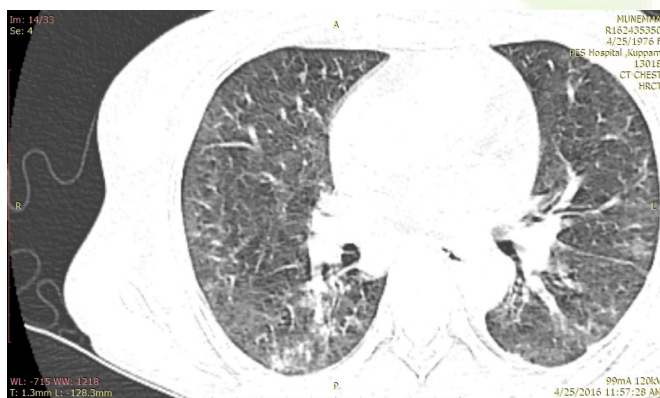


Figure 2: A case of NSIP. Axial section HRCT lung image showing patchy areas of ground glass opacities with mild interlobular septal thickening involving periphery of bilateral lungs with areas of subpleural sparing.

predominance was mostly seen in UIP/IPF (55.5%) followed by NSIP (22.2%), COP (16.6%) and HP (5.5%). Diffuse involvement of lung was mostly seen in AIP (50%) followed by HP (25%), UIP/IPF (12.5%) and Silicosis (12.5%).

Honey combing is confined to UIP/IPF (100%). Traction bronchiectasis is predominantly seen in UIP/IPF (68%), Ground glass opacity is mostly seen in NSIP (23%) followed by AIP, HP and COP. Reticular opacities are predominantly seen in UIP/IPF (45%) followed by NSIP (18%) and Silicosis (18%). Consolidation is predominantly seen in HP (30%) and COP (30%). Septal thickening is predominantly seen in UIP/IPF (45%) followed by NSIP (18%) and Silicosis (18%). Lymphadenopathy is predominantly seen in UIP (28%) followed by Silicosis (23%) and AIP (19%).

Most of the results in our study were correlating with previous studies (Meraj Rentia et.al, Bhawna Satija et.al, Baskaran Sundaram et.al, Brett Elicker, Collins C D, Orens J B, Arun A, Athol Wells, Ramakrishna Narra et al). [2-15]

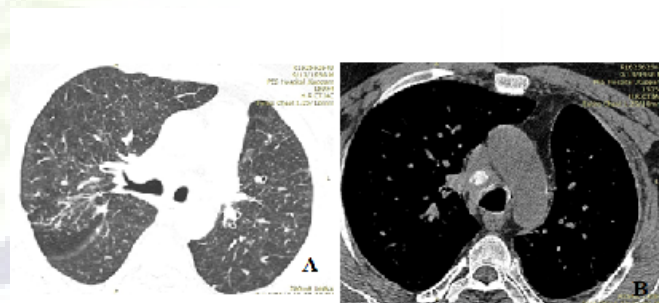


Figure 3: (A,B) A case of silicosis. Axial section HRCT images in lung window and mediastinal window showing centrilobular and subpleural ground glass nodules with fine inter-lobular septal thickening and calcified mediastinal lymph nodes.

In our study, 20 patients were diagnosed as idiopathic interstitial lung disease (64.5%) and 11 patients were diagnosed as non-idiopathic interstitial lung disease where the cause of interstitial lung disease was known, out of which 5 patients were diagnosed as silicosis, 3 patients as hypersensitive pneumonitis, 1 patient was a diagnosed case of scleroderma and 2 patients were suffering from rheumatoid arthritis.

Most of them were IPF/UIP (35%), followed by AIP (16%), Silicosis (16%), NSIP (12%), HP (9%) and COP (9%).

In our study, out of 31 patients of interstitial lung disease, upper lobe predominance involvement was mostly seen in silicosis (50%), followed by AIP (16.65), HP (16.6%) and COP (16.65). Middle lobe/ Lingular predominance was seen in UIP/IPF (55.5%), followed by NSIP (11.1%), AIP (11.1%), COP (11.1%) and Silicosis (11.1%). Lower lobe

Conclusion

ILD is a broad category of diseases that may present with different but overlapping findings on HRCT. The different HRCT findings and the location of these findings in the lung often enable a specific diagnosis of ILD to be made in a given patient obviating the need for lung biopsy.

HRCT is a non-invasive imaging modality for evaluation of lung parenchyma. The high spatial resolution makes HRCT superior to other imaging modalities.

Hence any case with suspected interstitial lung disease should always be subjected to HRCT to reach the final diagnosis.

References

1. Diette GB, Scatariage JC, Haponik EF. Do high resolution CT findings of interstitial pneumonitis obviate lung biopsy? Views of pulmonologists. *Respiration*. 2005;72(2):134–141. Available from: <https://doi.org/10.1159/000084043>.
2. Rentia M, Singla H, Malpani D, Vaishnav T, Jhala P. Radiological Analysis of Interstitial Lung Diseases. *IAIM*. 2015;2(6):69–76.
3. Satija B, Kumar S, Ojha UC, Gothi D. Spectrum of high-resolution computed tomography imaging in occupational lung disease. *Indian J Radiol Imaging*. 2013;23(4):287–296. Available from: <https://doi.org/10.4103/0971-3026.125564>.
4. Sundaram B, Gross BH, Martinez FJ, Oh E, Müller NL, Schipper M, et al. Accuracy of High-Resolution CT in the Diagnosis of Diffuse Lung Disease: Effect of Predominance and Distribution of Findings. *AJR Am J Roentgenol*. 2008;191(4):1032–1039. Available from: <https://doi.org/10.2214/ajr.07.3177>.
5. Elicker B, de Castro Pereira CA, Webb R, Leslie KO. High-resolution computed tomography patterns of diffuse interstitial lung disease with clinical and pathological correlation. *J Bras Pneumol*. 2008;34(9):715–744. Available from: <https://doi.org/10.1590/s1806-37132008000900013>.
6. Collins CD, Wells AU, Hansell D. Observer variation in pattern type and extent of disease in fibrosing alveolitis on thin section computed tomography and chest radiography. *Clin Radiol*. 1994;49(4):236–240. Available from: [https://doi.org/10.1016/s0009-9260\(05\)81847-1](https://doi.org/10.1016/s0009-9260(05)81847-1).
7. Orens JB, Kazerooni EA. The sensitivity of high-resolution CT in detecting idiopathic pulmonary fibrosis proved by open lung biopsy. A prospective study. *Chest*. 1995;108(1):109–115. Available from: <https://doi.org/10.1378/chest.108.1.109>.
8. Gaesler EA, Carrington C. Open biopsy for chronic diffuse infiltrative lung disease: clinical, roentgenographic, and physiological correlations in 502 patients. *Ann thorac surg*. 1980;30(5):411–426. Available from: [https://doi.org/10.1016/s0003-4975\(10\)61291-x](https://doi.org/10.1016/s0003-4975(10)61291-x).
9. Pingile BK, Kolan R, Vadlamudi S, Nagrale HR. Role of high resolution computed tomography in evaluation of diffuse lung diseases. *Int J Res Med Sci*. 2016;4(4):1099–1106. Available from: <https://dx.doi.org/10.18203/2320-6012.ijrms20160790>.
10. Verschakelen JA. The role of high-resolution computed tomography in the work-up of interstitial lung disease. *Curr Opin Pulm Med*. 2010;16(5):503–510. Available from: <https://doi.org/10.1097/mcp.0b013e32833cc997>.
11. Wells A. Clinical usefulness of high resolution computed tomography in cryptogenic fibrosing alveolitis. *Thorax*. 1998;53(12):1080–1087. Available from: <https://doi.org/10.1136/thx.53.12.1080>.
12. Meyer KC, Verschakelen. Diagnosis and management of interstitial lung disease. *Transl Respir Med*. 2014;2:4. Available from: <https://dx.doi.org/10.1186/2213-0802-2-4>.
13. Ferguson EC, Berkowitz EA. Lung CT: Part 2, The interstitial pneumonias—clinical, histologic, and CT manifestations. *AJR Am J Roentgenol*. 2012;199(4):464–476. Available from: <https://doi.org/10.2214/ajr.10.7309>.
14. Gupta A, Mathur R, Shyojiram, R P, Meena R, et al. Role of High Resolution Computed Tomography in Evaluation of Diffuse Parenchymal Lung Diseases. *RUHS J Health Sci*. 2017;2(1):16–23.
15. Narra R. Etiological Classification and HRCT Features of Diffuse Interstitial Lung Disease at Katuri Tertiary Referral Center. *Int J Res Med Appl Sci*. 2014;5(1):41–46.

Copyright: © the author(s), 2021. It is an open-access article distributed under the terms of the Creative Commons Attribution License (CC BY 4.0), which permits authors to retain ownership of the copyright for their content, and allow anyone to download, reuse, reprint, modify, distribute and/or copy the content as long as the original authors and source are cited.

How to cite this article: Kumar YR, Jenikar P, Kumar MS. Role of High Resolution Computed Tomography in Characterization of Interstitial Lung Disease in Rural Tertiary Care Centre. *Asian J. Med. Radiol. Res*. 2021;9(2):43-47.

DOI: dx.doi.org/10.47009/ajmrr.2021.9.2.10

Source of Support: Nil, **Conflict of Interest:** None declared.