

Basics of Tunneled Dialysis Catheter Placement for Haemodialysis - Single Centre Experience

Sabarinath Eada¹, Uma Maheswara Reddy V², Saripudi SVN Manikanta Vijay¹, Yugandhar Samireddypalle³, Pavithira Annamalai⁴, K S Amitha Vikrama⁵

¹Post Graduate, Department of Radiology, Narayana Medical College, Nellore, Andhra Pradesh, India, ²Associate Professor, Department of Radiology, Narayana Medical College, Nellore, Andhra Pradesh, India, ³Senior resident, Interventional Radiologist, Department of Radiology, Narayana Medical College, Nellore, Andhra Pradesh, India, ⁴Junior Resident, Department of General Medicine, Mandya Institute of Medical Sciences, Bangalore, Karnataka, India, ⁵Head, Department of Radiology, Apollo hospitals, Bangalore, Karnataka, India.

Abstract

Background: The incidence of end stage renal disease is on the rise and most of these patients are undergoing dialysis either through tunneled/non tunneled dialysis catheters or through arteriovenous fistulas/grafts. The tunneled dialysis catheters act as bridge dialysis devices during maturation period of arteriovenous fistulas/grafts and also serve as the last option for end stage renal disease patients who have exhausted all the other dialysis accesses. The aim and objective is to review the basic key concepts of internal Jugular, External Jugular and Subclavian tunneled venous catheter placement, techniques utilized, complications encountered, issues of suboptimal functioning and their management. **Subjects and Methods:** This was a prospective observational study done in department of Radio diagnosis, Narayana medical college, Nellore. About 54 cases were performed in our institution from December 2018 to Mar 2020 (including three pediatric patients). The age range of these patients is 10 to 75 years. **Results:** Out of 54 cases, one case had failed, as the guide wire didn't pass across the brachiocephalic vein. Venogram revealed high grade stenosis of right brachiocephalic vein. There were major complications in two cases, minor complications in five cases with delayed complications in two cases. **Conclusion:** Tunneled catheters play a key role in serving as bridging devices during maturation of AVF/AVG or as the last option in chronic kidney disease patients in whom all other options have exhausted. Intervention radiologist should have good experience and an overall knowledge of the issues involved in placement of tunneled dialysis catheters, knowledge about the complications, technical issues of suboptimal functioning, for optimal catheter placement and also for improving catheter function.

Keywords: Arterio-Venous fistula, Arterio-Venous graft, Tunneled dialysis catheter, Right internal jugular vein

Corresponding Author: Yugandhar Samireddypalle, Senior resident, Interventional Radiologist, Department of Radiology, Narayana Medical College, Nellore, Andhra Pradesh, India.

E-mail: yugu.samireddypalle@gmail.com

Received: 12 May 2020

Revised: 08 June 2020

Accepted: 19 June 2020

Published: 05 July 2020

Introduction

The incidence of end stage renal disease is on the rise and most of these patients are undergoing hemodialysis mainly through four types of vascular access:

Arterio-Venous fistulas (AVF), Arterio-Venous grafts(AVG), Tunneled dialysis catheters (TDC), Non-Tunneled central vein catheters.

The tunneled dialysis catheters act as bridge dialysis devices during maturation period of arteriovenous fistulas/grafts and also serve as the last option for end stage renal disease patients who have exhausted all the other dialysis accesses.

Aim and Objective

To review the basic key concepts of internal Jugular, External Jugular and Subclavian tunneled venous catheter placement, techniques utilized, complications encountered issues of suboptimal functioning and their management.

Subjects and Methods

- About 54 cases were performed in our institution from December 2018 to Mar 2020 (including three pediatric patients). The age range of these patients is 10 to 75 years
- All these cases were done either in angiography suite or in the fluoroscopy room.

- Portable ultrasound machine was used for obtaining venous access.

Inclusion criteria

All patients with chronic renal parenchymal disease requiring bridge hemodialysis.

Exclusion criteria

Coagulopathy with INR > 2 and platelet count < 70,000/micro L

Patients who have not undergone dialysis for more than 2 days.

Patients with fever / sepsis.

Tunneled dialysis catheter placement is the positioning of a double lumen dialysis catheter from the surface of the skin across a major vein to reach SVC-RA junction. The tube is placed along a subcutaneous tunnel created under the skin to help keep it secure. The cuff at the distal end of the catheter causes fibrosis across the tunnel and prevents bacteria at the exit site to spread along the catheter.^[1] Hence, they have advantage over temporary non tunneled central venous catheters, which tend to get infected early, just like any other catheter.

Pre- Procedure evaluation

Thorough physical examination is conducted to look for dilated neck and chest veins/collaterals. If present, then a proper venogram is done under fluoroscopy to map the central veins and to exclude central vein stenosis/occlusion.

The access sites were assessed on the previous day using ultrasound. Bilateral Internal Jugular veins were assessed. The internal Jugular vein contralateral to the fistula limb was preferred to prevent future risk of limb swelling secondary to central vein occlusions.

Right internal jugular vein (RIJV) is the preferred vascular access site for tunneled-cuffed central venous catheters according to The National Kidney Foundation Dialysis Outcomes Quality Initiative (NKF-KDOQI).

Other accessible options are the left internal jugular vein (LIJV), the external jugular veins, the femoral veins, the subclavian veins (SCV), transhepatic accesses, and translumbar accesses.^[2]

The Right IJV is preferred over the Left IJV because

1. The Right IJV provides a short and straight route into the right atrium in contrast to the perpendicular route of the left-sided access.^[3,4]
2. Since the left arm is the predominant vascular access site for AVFs in right-handed people, placing a catheter in the contralateral RIJV reduces the risk of thrombosis in the left-sided venous drainage system, which could be harmful to functioning of the graft.^[5]

3. Other advantages of Right IJV access include minimal chance of damage to the thoracic duct, which is anatomically located on the left side.^[5]

However, access site is decided on individual basis, depending upon various factors like, the limb containing AVF/AVG, Previous placements of temporary dialysis catheters, patency of the access vein in USG.

Internal Jugular vein, external jugular vein, Subclavian vein contralateral to fistula limb and ipsilateral veins were assessed and utilized in descending order of preference.

We assess the renal parameters, body weight, serum electrolytes of the patients as part of pre-procedure workup. If there is interval increase in fluid weight more than 1kg/day in the last few days or abnormal serum electrolyte levels, we prefer to perform interval dialysis through temporary catheters and then electively insert TDC.

In dialysis dependent patients, we routinely perform dialysis a day prior to the procedure as it reduces procedure related complications.

Procedure

Under aseptic precautions and ultrasound guidance, using 18G puncture needle, the internal jugular vein is punctured at lower most point of Sedillot's triangle. (between two heads of sternocleidomastoid and clavicle)

We puncture the anterolateral wall of IJV under USG guidance in transverse view. This step is important as it reduces the chances of catheter kink at IJV entry site. [Figure 1]

In cases where there is complete IJV occlusion, direct puncture at the internal jugular – Subclavian junction is done at obtuse angle, after confirming its patency on doppler. [Figure 2]

If IJV is thrombosed and EJV is prominent, the EJV is punctured as low and as close to IJV as possible at obtuse angle. For subclavian vein, puncture is done just lateral to the sterno-clavicular joint at obtuse angle.

After securing access, 035 stiff guide wire is placed across the puncture needle, up to the right atrium. Serial dilatation is done up to 14 French dilator and a 16F strip sheath is placed. Using a metal tunneler - catheter combination, a tunnel is created starting from the midclavicular line, about 3cm above the nipple and extending upto the venotomy site. Then, the catheter is pushed across into the strip sheath and after confirming its tip in RA-SVC junction, the strip sheath is peeled off. The final position is confirmed with X ray or fluoroscopy. Once in place, the catheter will be secured with stitches.

While inserting the catheter into the peel away sheath, the sheath may get kinked resulting in increased resistance. This can be avoided by obtuse angled puncture, especially in subclavian vein and puncturing the anterolateral wall of

internal jugular vein as discussed above.

Tip should be placed preferably in right atrium or at cavoatrial junction.

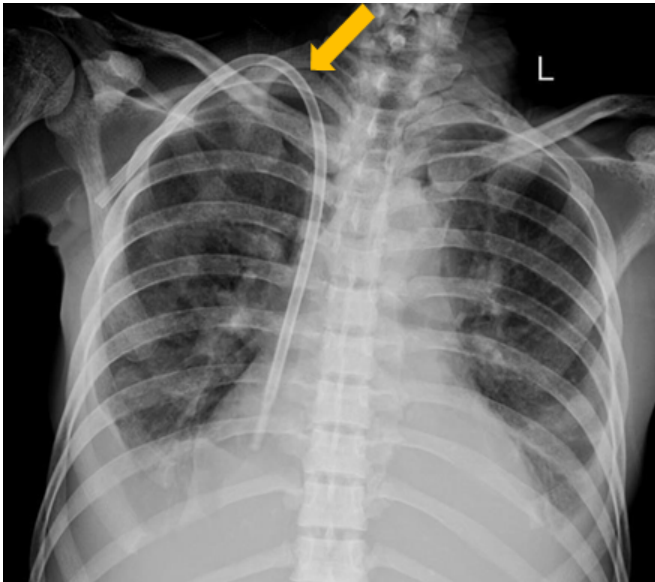


Figure 1: Right IJVpermcatheter - placed with its tip in the right atrium. Care should be taken to prevent Kink at the venotomy site (arrow).

Note the mild tortuosity at the region of brachiocephalic vein(arrow). No acute kink noted. There was optimal flow from both limbs.

Post- Procedure follow-up

Free flow of blood from both lumens is checked with forceful aspiration, followed by heparin lock to prevent thrombus formation. The patient is followed up till his first successful dialysis through the catheter.

Possible Complications

The expected complications in the literature are

- Infection
- Scarring and narrowing of the central vein—venous stenosis
- Excessive bleeding at venotomy site/tunnel exit site.
- Allergic reaction (to the contrast material/local anaesthesia)
- Irregular heart rhythm(if guidewire is placed too deep in right ventricle)
- Rarely, air can enter the upper chest during catheter insertion causing a pneumothorax(especially with older catheter sets which do not have hemostatic valve to the strip sheath)
- Inadvertent puncture of pericardium leading to pneumopericardium.

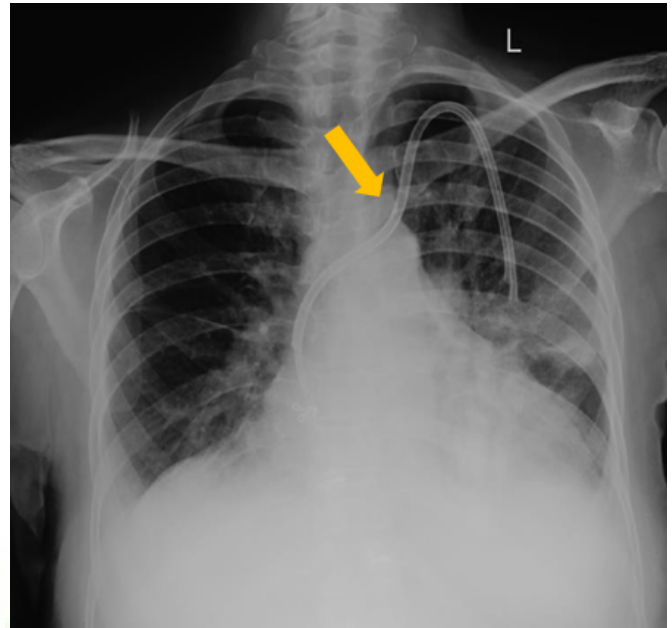


Figure 2: Left IJVpermcatheter. In this case, the both IJVs were thrombosed and USG guided puncture was done at the IJV-SCV junction, after confirming patency on Doppler.

Results

Out of 54 cases, one case had failed, as the guide wire didn't pass across the brachiocephalic vein. Venogram revealed high grade stenosis of right brachiocephalic vein. The patient was put on femoral temporary catheter and advised venoplasty.

There were major complications in two cases, minor complications in five cases with delayed complications in two cases.

Major Complications

In our experience, out of 54 tunneled dialysis catheters, we faced dreadful complications in two cases.

One case was 62 yr old male, who collapsed immediately post procedure. USG revealed massive hemopericardium causing cardiac tamponade. The condition was recognized immediately and pericardiocentesis was done. However, the patient expired within 3 hours post procedure.

Another case was 23yr old female, who developed angioedema of face and neck. She was immediately intubated, admitted in ICU and medically managed successfully.

Minor Complications

Minor complications like prolonged bleeding at venotomy site was seen in four cases, which was managed by head up position, local tamponade by pressure bandage, purse string sutures, and initial few sessions of heparin free dialysis.

Desmopressin also can be administered, if there is suspicion of uremic bleeding. [6]

One case required removal of TDC within one week of insertion due to infection and fever. Temporary catheter was inserted for dialysis, blood culture was done and appropriate antibiotics were given. New tunneled dialysis catheter was inserted after couple of weeks.

Delayed Complications

In two cases, the contralateral AVF failed to mature and new AVF was placed on the limb ipsilateral to the TDC. These patients developed severe limb edema as AVF matured. The catheter was removed and venogram revealed stenosis of ipsilateral brachiocephalic vein. Venoplasty was done at a later date.

Suboptimal function /occlusion of catheter

In seven cases, Flow rates were suboptimal.

Immediate post procedure

This was noticed in two cases and occurs due to kink at the venotomy site, which happens when vein is punctured anteriorly or at acute angle instead of anterolateral/obtuse angled puncture. [Figure 3]

This is managed by blunt dissection of soft tissues underneath the catheter kink and removal of fibrotic bands, if any.

After few weeks/months

This was seen in five cases and can occur due to the catheter tip abutting to SVC wall or formation of organised thrombus / fibrin sheath deposition at the tip of catheter.

Wiring can be tried with 035 teflon wire to clear the tip of both limbs, followed by thrombolytic solution lock -5000 to 40000 IU/ml urokinase for upto 6 hours. [7]

Rotating the catheter by 180 degrees over the wire so as to remove the wall apposition.

Finally, if everything fails, snaring of the fibrin sheath at the catheter tip can be done from femoral side, using a snare device.

Discussion

Tunneled dialysis catheters act as bridge hemodialysis devices till the maturation of AVF/AVG and also as a last resort for patients who have exhausted all other options. Their main advantage being painless dialysis access, immediate usage after insertion and relatively long term use. [6]

The right internal jugular vein is ideal for patients who never had dialysis prior. If there is thrombus in right IJV, then left IJV will be chosen. If both IJV are thrombosed, then External Jugular, Subclavian or femoral veins are chosen in decreasing order of preference. [8]

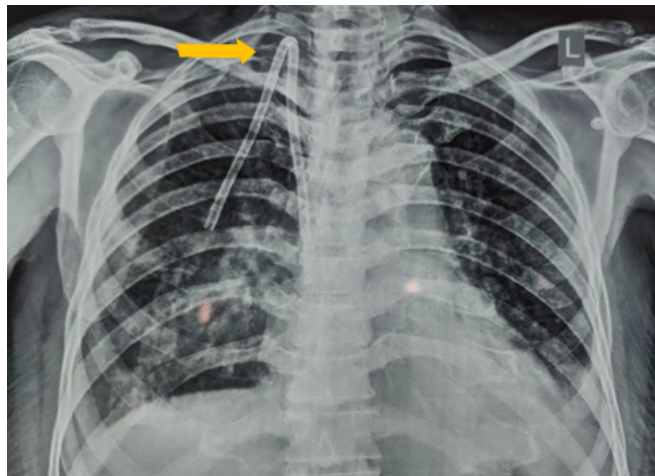


Figure 3: Radiographic image showing kink at IJV entry site (arrow). This kink was removed by blunt dissection of underlying soft tissues, and optimal function was restored.

Zeki et.al has demonstrated that complications of vascular puncture are less when USG guidance was used. [8]

Bagul et.al advised the use of tunneled catheters as medium term temporary dialysis catheter because of its delayed complications like central venous stenosis and high rates of delayed catheter dysfunction. [7]

Wang K et.al experience in paediatric permcatheters was reviewed, which advises handling of catheters only during dialysis sessions, with regular cleaning of catheter exit site with povidone iodine solution and heparin lock after each dialysis session. This will reduce delayed complications like exit site infection and catheter thrombosis. [9]

Ervo et.al has suggested anticoagulation in all patients having tunneled catheter. They observed that most of the long term complication of catheter dysfunction was secondary to fibrin sheath formation. [10]

Ash et.al discussed the self-centering SVC catheter, which reduces the probability of fibrin sheath formation at tip of catheter. [1]

In our institute, we have placed 54 tunneled dialysis catheters, including 3 paediatric cases. We observed good short term and medium term patency rates.

We had dreadful complications in two cases. One case developed angioedema of face and neck which was successfully managed.

One case expired due to pneumopericardium. Few case reports of cardiac tamponade are described in literature. [11,12] We try to negotiate the guidewire into the IVC, as a confirmation that we are completely intravascular and not in pericardium. Then

we proceed with track dilatation. This step prevents such major life threatening complication.

Minor complications like Catheter-related bloodstream infection (CRBSI) was seen in one patient, which mandated catheter removal. Bleeding at venotomy site/ tunnel exit site was managed conservatively.

Central venous stenosis was seen as a delayed complication in two cases, in which catheter was placed in alternate access site and venoplasty of stenotic vein was attempted.

Suboptimal function of catheter was observed in 7 cases and were managed as discussed above. If all measures fail and a fibrin sheath is strongly suspected at the tip of catheter, then we don't do stripping of fibrin sheath, due to cost constraints. We either suggest replacement of catheter over wire, or a new catheter at different venous access site.

One case completely failed, as the guide wire couldn't be negotiated.

Venogram revealed central venous stenosis. The patient was advised fistuloplasty, but he was lost to follow up.

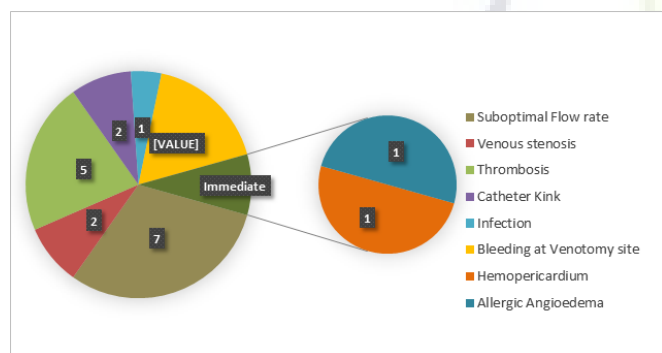


Figure 4: Complications on Insertion of Tunneled Dialysis Catheter.

Conclusion

Tunneled catheters play a key role in serving as bridging devices during maturation of AVF/AVG or as the last option in chronic kidney disease patients in whom all other options have exhausted.

Intervention radiologist should have good experience and an overall knowledge of the issues involved in placement of tunneled dialysis catheters, knowledge about the complications, technical issues of suboptimal functioning, for optimal catheter placement and also for improving catheter function. Regular surveillance is required for long term optimal function of these catheters.

References

- Ash SR. Advances in Tunneled Central Venous Catheters for Dialysis: Design and Performance. *Semin Dial.* 2008;21(6):504–515. Available from: <https://dx.doi.org/10.1111/j.1525-139x.2008.00494.x>.
- Pereira K, Osiason A, Salsamendi J. Vascular Access for Placement of Tunneled Dialysis Catheters for Hemodialysis: A Systematic Approach and Clinical Practice Algorithm. *J Clin Imaging Sci.* 2015;5:31–36. Available from: <https://dx.doi.org/10.4103/2156-7514.157858>.
- Siegel JB. Tunneled Dialysis Catheters: Pearls and Pitfalls. *J Vasc Interv Radiol.* 2008;11:181–185. Available from: <https://dx.doi.org/10.1053/j.tvir.2008.09.005>.
- Yevzlin AS, Chan M, Gimelli G. How I Do It: Preferential Use of the Right External Jugular Vein for Tunneled Catheter Placement. *Semin Dial.* 2008;21(2):183–185. Available from: <https://dx.doi.org/10.1111/j.1525-139x.2007.00415.x>.
- Sulek CA, Blas ML, Lobato EB. A randomized study of left versus right internal jugular vein cannulation in adults. *J Clin Anesth.* 2000;12(2):142–145. Available from: [https://dx.doi.org/10.1016/s0952-8180\(00\)00129-x](https://dx.doi.org/10.1016/s0952-8180(00)00129-x).
- Clark E, Kappel J, MacRae J, Dipchand C, Hiremath S, Kiai M, et al. Practical Aspects of Nontunneled and Tunneled Hemodialysis Catheters. *Can J Kidney Health Dis.* 2016;3:2054358116669128. Available from: <https://dx.doi.org/10.1177/2054358116669128>.
- Bagul A, Brook NR, Kaushik M, Nicholson ML. Tunnelled Catheters for the Haemodialysis Patient. *Eur J Vasc Endovasc Surg.* 2007;33(1):105–112. Available from: <https://dx.doi.org/10.1016/j.ejvs.2006.08.004>.
- Aydin Z, Gursu M, Uzun S, Karadag S, Tatli E, Sumnu A, et al. Placement of Hemodialysis Catheters with a Technical, Functional, and Anatomical Viewpoint. *Int J Nephrol.* 2012;2012:1–5. Available from: <https://dx.doi.org/10.1155/2012/302826>.
- Wang K, Wang P, Liang XH, Yuan FF, Liu ZS. Cuffed-tunneled hemodialysis catheter survival and complications in pediatric patients: a single-center data analysis in China. *Int J Clin Exp Med.* 2015;8(6):9765–9765.
- Ervo R, Cavatorta F, Zollo A. Implantation of Permanent Jugular Catheters in Patients on Regular Dialysis Treatment: Ten Years' Experience. *J Vasc Access.* 2001;2(2):68–72. Available from: <https://dx.doi.org/10.1177/112972980100200209>.
- Aiken G, Porteous L, Tracy M, Richardson V. Cardiac tamponade from a fine silastic central venous catheter in a premature infant. *J Paediatr Child Health.* 1992;28(4):325–327. Available from: <https://dx.doi.org/10.1111/j.1440-1754.1992.tb02679.x>.
- Azevedo AC, de Lima IF, Brito V, Centen MJ, Fernandes A. Cardiac tamponade: a rare complication of central venous catheter—a clinical case report. *Rev Bras Anesthesiol.* 2018;68(1):104–112. Available from: <https://doi.org/10.1016/j.bjane.2015.04.005>.

Copyright: © the author(s), 2020. It is an open-access article distributed under the terms of the Creative Commons Attribution License (CC BY 4.0), which permits authors to retain ownership of the copyright for their content, and allow anyone to download, reuse, reprint, modify, distribute and/or copy the content as long as the original authors and source are cited.

How to cite this article: Eada S, Reddy V UM, Vijay SSVNPM, Samireddypalle Y, Annamalai P, Vikrama KSA. Basics of Tunneled Dialysis Catheter Placement for Haemodialysis – Single Centre Experience. Asian J. Med. Radiol. Res. 2020;8(1): 144-149.

DOI: [dx.doi.org/10.47009/ajmrr.2020.8.1.26](https://doi.org/10.47009/ajmrr.2020.8.1.26)

Source of Support: Nil, **Conflict of Interest:** None declared.

