

# Role of Multi Detector Computed Tomography Cervicocerebral Angiography in Evaluation of Patients with Stroke

Balaji Varaprasad Mallula<sup>1</sup>, Jithender Reddy Chintala<sup>2</sup>, Srinadh Boppana<sup>3</sup>, S. Annapurna<sup>4</sup>

<sup>1</sup>Associate Professor, Department of Radiology, KAMSRC, L.B Nagar, Hyderabad, Telangana, India, <sup>2</sup>Consultant Radiologist, CITY Diagnostics, Hyderabad, Telangana, India, <sup>3</sup>Consultant Radiologist, Kamineni Hospitals, L.B Nagar, Hyderabad, Telangana, India, <sup>4</sup>Associate Professor, Department of Radiology, KAMSRC, L.B Nagar, Hyderabad, Telangana, India.

## Abstract

**Background:** Stroke is the second single most common cause of death in the world causing approximately 6.7 million deaths each year. It has a greater disability impact on an individual than any other chronic disease. The aim of the study is to review the value of CTA in detection and evaluation of non-traumatic cervicocerebral vascular disease (stroke). **Subjects & Methods:** A prospective observational study conducted in the Department of Radiodiagnosis, Kamineni Hospitals, L.B. Nagar, Hyderabad over 60 patients during April 2016 to May 2017. **Results:** Out of 60 patients, 35(58.3%) patients had ischemic stroke, 25(41.6%) had hemorrhagic stroke. Overall stroke was seen mostly in the age group of 61-70 (28.3%) years, with a Male to female ratio of 3:2. **Conclusion:** Hypertension was the most common risk factor associated with this disease, followed by diabetes. CTA helps in accurate diagnosis, risk stratification and planning management protocols.

**Keywords:** Cerebrovascular Accident, Hypertension, MDCT, Cervicocerebral Angiography.

**Corresponding Author:** S. Annapurna, Associate Professor, Department of Radiology, KAMSRC, L.B Nagar, Hyderabad, Telangana, India.

E-mail: [purnasrirambhat@gmail.com](mailto:purnasrirambhat@gmail.com)

Received: 26 November 2019

Revised: 30 December 2019

Accepted: 17 January 2020

Published: 05 July 2020

## Introduction

Stroke is an acute neurological injury caused either by the occlusion or rupture of cerebral blood vessels. Broadly classified into two types, ischemic and hemorrhagic. Ischemia due to thrombosis or embolism constitutes about 85% and hemorrhage due to intra cerebral or subarachnoid bleed constitutes the rest.<sup>[1,2]</sup> Stroke is one of the leading causes of death and disability in developing countries like India, with an estimated prevalence ranging from 44 to 843 per 100,000 population.<sup>[3]</sup> The estimated age-adjusted prevalence rate in India for stroke ranges between 84/100,000 and 262/100,000 in rural and between 334/100,000 and 424/100,000 in urban areas.<sup>[4]</sup>

A number of clinical tests have been developed over the years for initial triage of patients presenting with symptoms of stroke. But they lacked the sensitivity and specificity of an imaging examination, nor could accurately differentiate ischemic and hemorrhagic stroke. Therefore, the initial step in the management of a suspected stroke patient is an imaging examination starting with a non-enhanced computed tomography (NECT), often used to quickly exclude

the presence of haemorrhage, look for ischemia, helps exclude stroke mimics, mapping of arterial calcification and localization of the anatomy of interest.

Imaging the cervicocerebral vasculature, the origin of all stroke pathology, is an essential part of Stroke protocol and follows the native NECT. A single bolus of contrast agent is sufficient to achieve both angiography and perfusion images, thus improves diagnostic precision, providing insight into the source of dysfunction and may lead to accurate management towards intervention.<sup>[5]</sup> Thus Multi detector computed tomography (MDCT) Cervicocerebral angiography forms an important tool for diagnosis and prognostication of patients presenting with stroke. Computed tomography angiography (CTA) using latest generation of multislice scanners permits rapid and comprehensive assessment of the cervicocerebral vasculature, thus becoming a valuable tool in stroke patients.<sup>[6]</sup> The main role of CTA is to reveal the status of large cervical and intra cranial arteries and thereby help define etiopathogenesis of the disease, thus very useful in providing guidance for further intervention.<sup>[7]</sup> CTA is the most common first-line diagnostic modality for vascular imaging in the setting of acute stroke.<sup>[8]</sup> The diagnostic accuracy of

CTA in Stroke patients reported at present is far superior to the previously published studies. Purpose of this study is to review the diagnostic performance of CTA in evaluation of cervicocerebral vascular pathologies as a non-invasive imaging modality in patients presenting with stroke.

### Aims and Objectives

#### Aim

To review the value of CTA in detection and evaluation of non-traumatic cervicocerebral vascular disease (stroke).

#### Objectives

To analyse the findings of cervicocerebral vascular diseases on 128 slice multi detector computed tomography angiography (MDCTA).

To determine the morphology and imaging patterns of various vascular lesions.

To provide information that could accurately determine the choice of management.

### Subjects and Methods

In this cross sectional study, 90 subjects were included. Among them, 45 were type 2 diabetes mellitus patients with duration of 5 years or more, with diabetic complications are included as cases and 45 age and sex matched healthy controls, who attended the Department of Medicine and Radio-diagnosis, Akash Institute of Medical Sciences & Research Centre, Devanahalli. This prospective observational study done in the Department of Radiodiagnosis, Kamineni Hospitals, L.B. Nagar, Hyderabad during the period of April 2016 to May 2017 over 60 patients.

#### Inclusion criteria

All Clinically suspected and prior diagnosed cases of stroke on initial screening imaging modalities, which were further referred to the department of radio-diagnosis for CT angiography. All age groups are included. Both sexes are included.

#### Exclusion criteria

Patients with h/o trauma. Any person with abnormal renal function tests. Known severe allergy to intravenous contrast agents.

### Results

In our study, a total of 60 patients with diagnosis of cerebrovascular accident (CVA) were studied.

Out of 60 patients, 35(58.3%) patients had ischemic stroke, 25(41.6%) had hemorrhagic stroke.

Out of 60 patients in our study, 24 (40%) patients had atherosclerotic disease, 18 (30%) had aneurysms, 8(13.3%)

**Table 1: showing age distribution**

Age(Years)	No Of Patients	Percentage(%)
0-10	0	0%
11-20	2	3.3%
21-30	1	1.6%
31-40	7	11.6%
41-50	14	23.0%
51-60	15	25.0%
61-70	17	28.3%
71-80	5	8.3%
81-90	0	0%
91-100	0	0%

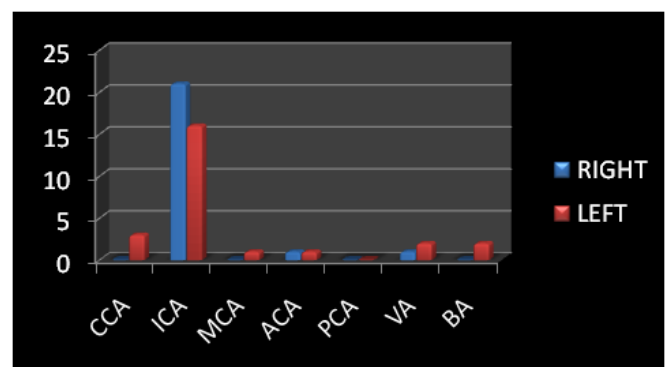
**Table 2: showing sex distribution in stroke.**

	Male	Female
Stroke	36	24
Ischaemic	25	10
Hemorrhagic	10	15
Aneurysm	06	12
Avm	01	00

**Table 3: Distribution of risk factors in stroke**

Risk Factor	Stroke	Ischemic	Hemorrha	Aneurysm
Diabetes	22	17	05	04
Hypertensi	27	22	05	04
Both	18	16	02	01

had thrombosis, 1 (1.66%) had AVM, no obvious demonstrable etiological cause was found in 9 patients.



**Figure 1: Showing distribution of various sites of occlusion**

Most common sub segment involved among ICA was both proximal cervical ICA and Cavernous portion, involved in 11 each. In 6 patients entire ICA is occluded.

Among 48 segments involved in ischemic stroke, 39 segments had atheromatous disease, of which fibro fatty plaque were seen in 32 (82%) segments and fibro calcific plaque in 7(18%) segments.

Out of 48 stenotic arterial segments, 14(29%) showed mild stenosis, 8(16.6%) showed moderate stenosis and 26 (54%) showed severe stenosis.

Total number of patients with imaging findings of aneurysm were 18. Total no of aneurysms encountered in 18 patients were 23. Total no of patients with single aneurysm were 14(77.8%) and with multiple (>1) were 4(22.2%).

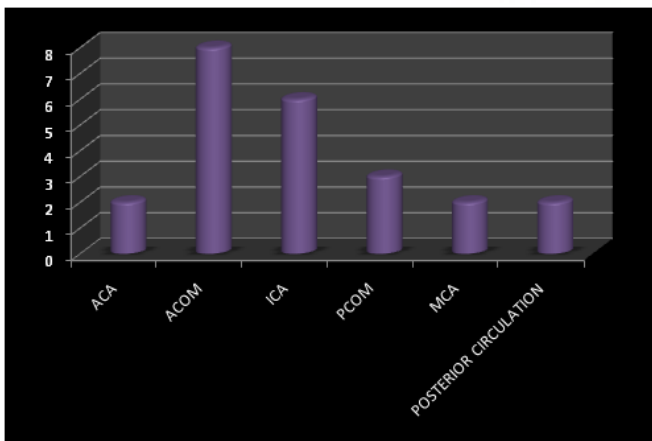


Figure 2: Showing distribution of aneurysms based on site

Among 23 aneurysms detected in 18 patients on CTA:-

Aneurysms were saccular in 11 (47.8%) patients, non-spherical in 7(30.4%) and irregular in 5 (21.7%). aneurysms with size<7mm were seen in 13 (56.5%) and >7mm in 10(43.5%) aneurysms. Largest of the aneurysm measures 29X22 mm (Giant aneurysm>25mm). Bifurcation type of parent configuration is seen in 12(52%) and side wall configuration type in 11(48%). narrow neck were seen in 19 (90.4%) and wide neck were seen in 2(9.5%).aspect ratio >1.3were seen in 17 (80.9%) and with <1.3 in 4 (19.04%) aneurysms.

Among 25 cases of hemorrhagic stroke, only 1 patient was diagnosed to have Arteriovenous malformation (AVM).

## Discussion

Cerebrovascular accident (CVA) is a significant cause of morbidity and a poor prognostic factor amongst the elderly.

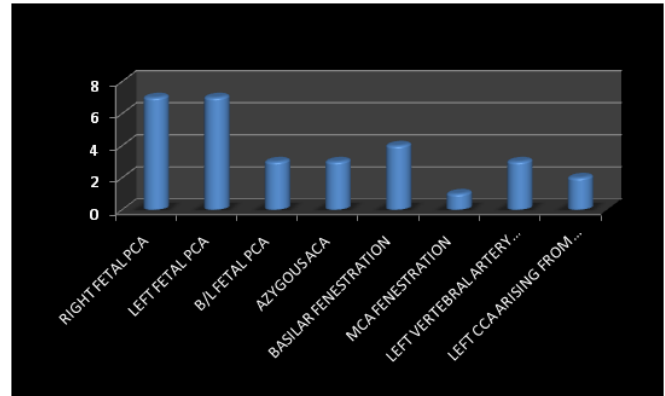


Figure 3: Bar diagram showing distribution of various anatomical variants

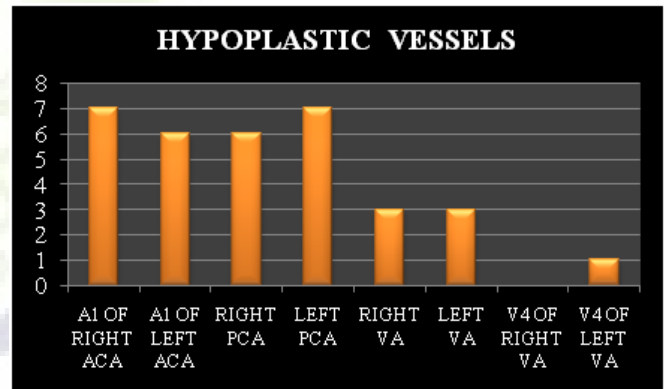


Figure 4: Bar diagram showing distribution of hypoplastic vessels

MDCT cervicocerebral angiography as a new diagnostic modality is likely to add to the diagnostic accuracy of CT in vascular disease with enhanced spatial and temporal resolution.

Aim of CTA in stroke patients is to delineate the cause of underlying vascular pathology, morphological evaluation for risk stratification and for planning appropriate treatment regime.

**Out of 60 patients included in our study:-**

35(58.3%) patients had ischemic stroke, 25(41.6%) had hemorrhagic stroke. Ischemic stroke is more common, representing approximately 85 % of all stroke cases, and has a much lower 30-day mortality rate at approximately 12 %.<sup>[9]</sup> Although the incidence of Hemorrhagic stroke is low, it is associated with significant morbidity and mortality. Up to 38 % of patients that experience hemorrhagic stroke will die within 30 days.<sup>[10]</sup>

stroke was seen most commonly in the age group of 61-70 years (28.3%). The second most common age group was 51-60 years (25%), followed by 41-50 years (23%) age group. Most common age group with diagnosis of ischemic stroke in our study were in the age group of 61-70 and among hemorrhagic stroke were 41-50 years. This shows that the incidence of overall stroke increases with increasing age. Age is the single most important risk factor for stroke. Brown RD et al and Wolf PA et al in their respective studies concluded that the risk of having a stroke doubles every decade after the age of 55. [11,12] Dalal PM et al and sridharan SE et al in their study on stroke patients in Mumbai and Trivandrum in 2008 and 2009 respectively concluded that the mean age of patients with stroke was 66 and 67 years respectively. [13,14]

36 (60%) patients were males and 24 (40%) were females. This shows that male sex itself is an independent (non modifiable) risk factor for stroke. Townsend, N. et al concluded that men are at a 25% higher risk of having a stroke and at a younger age compared to women. [15] Dalal PM et al in Mumbai, stated that men had a higher stroke incidence rate than did women. [13]

Out of 35 patients with ischemic stroke, Male to female ratio is 5:2. Out of 25 patients with hemorrhagic stroke, Male to female ratio is 2:3. Out of 18 patients with aneurysms, Male to female ratio is 1:2. J.L. Chasonand W.M. Hindman study concluded that the Unruptured intracranial aneurysms are more common in women with a 1:3 ratio of men to women. [16] Similar predominance is seen in our study.

Out of 60 patients with stroke, 22 (36%) patients were diabetic, 27 (45%) were hypertensive. 18(30%) patients had both risk factors. Out of 35 patients with ischemic stroke, 17(48.5%) patients were diabetic and 22(62.8%) were hypertensive. 16(45%) patients had both. Out of 25 patients with hemorrhagic stroke, 5 (20%) patients were diabetic and 5(20%) were hypertensive. 2 (8%) patients had both. Thus, Hypertension is most common modifiable risk factor associated with stroke in my study. Which is similar to many studies as stated below. Strong K, et al study concluded that hypertension causes 54% of stroke in low-income and middle-income countries, [17] followed by hypercholesterolemia (15%) and tobacco smoking (12%). Jeyaraj Durai Pandian study on stroke epidemiology and stroke care services in India stated that, hypertension was the most important risk factor associated with stroke. [4]

Out of 18 patients with aneurysms, 4(22%) patients were diabetic and 4(22%) were hypertensive. 1 (5%) patient had both risk factors. Greving JP et al in their pooled analysis of six prospective cohort studies on predictors of aneurysm rupture concluded that patients with hypertension are at higher risk of rupture. [18] Thus, considering Hypertension alone, 5 patients with aneurysm in our study are at higher risk of rupture.

Out of 60 patients in our study, 24 (40%) patients had atherosclerotic disease, 18 (30%) patients had aneurysms, 8 (13.3%) patient had thrombosis, 1(1.66%) patient had AVM, no obvious demonstrable etiological cause was found in 9 patients. Thus, Atherosclerosis is most common cause of stroke overall. Wong KS, Li H study stated that intra cranial atherosclerotic disease (ICAD) is a much more important cause of stroke in Asia, where it can account for 33% to 67% of stroke cases. [19]

Out of total 48 occluded arterial segments, ICA (77%) is the most commonly involved, followed by CCA (6.2%) and VA (6.2%). Thus ICA is the most common segment involved over all. Most common sub segment involved among ICA in our study was both proximal cervical ICA and Cavernous portion, involved in 11 each. According to Dragajichici, proximal 2 cm of ICA origin and intracranially, the carotid siphon (cavernous portion) are the most common sites of occlusion among ICA. Similar observations were seen in our study.

Among 48 segments involved in ischemic stroke, 39 segments had atheromatous disease, of which fibro fatty plaque were seen in 32 (82%) segments and fibro calcific plaque in 7(18%) segments. Thus, soft plaques are more commonly encountered.

CTA is a reliable tool to diagnose extracranial large artery disease. [20] In a large retrospective study, the presence of intraluminal thrombus detected on CTA was found to be highly predictive of the symptomatic side in carotid disease when compared to a smooth plaque surface or extensive calcification, thus suggesting certain plaque characteristics that could predict an unstable plaque with a tendency for recurrent thromboemboli. [21] Thus, determining plaque type is important for patient triage.

Out of 48 stenotic arterial segments, 14(29%) showed mild stenosis, 8(16.6%) showed moderate stenosis and 26 (54%) showed severe stenosis. Most common segment involved in severe stenosis is ICA. In both NASCET and ECST, it has been established that carotid endarterectomy is more effective than medical therapy in reducing stroke risk in symptomatic patients with severe (70%–99%) carotid artery stenosis. Carotid endarterectomy may also be beneficial for asymptomatic patients with carotid artery stenosis of less than 60%. [22] Thus, classification of grades of stenosis helps in risk stratification and planning appropriate treatment regime.

Among 23 aneurysms encountered in 18 patients in our study, total no of patients with single aneurysm were 14(77.8%) and with multiple (>1) were 4(22.2%). According to Takahashi S, [23] Multiple aneurysms constitutes 15-30% overall. Similar prevalence is seen in our study. D.O. Wiebers, [24] stated that patients with multiple aneurysms are at higher risk of rupture. 91.3% of aneurysms were located in anterior circulation and 8.69% in posterior circulation. Overall, Acom (34.7%) is the most commonly involved site. According to Takahshi S, [23]

Approximately 90% of aneurysms arise from the anterior circulation. Similar observations were seen in our study.

In Prospective Cohort Study by Morita et al,<sup>[25]</sup> concluded that, Aneurysm located in anterior and posterior communicating arteries are at greater risk of rupture. In our study 11(47.8%) aneurysms were seen in these sites.

Among 23 aneurysms detected in 18 patients on CTA, aneurysms were saccular in 11 (47.8%) patients, non-spherical in 7(30.4%) and irregular in 5 (21.7%). According to Takayashi S,<sup>[23]</sup> Saccular cerebral aneurysms (berry aneurysms) accounts for vast majority of intracranial aneurysms. Similar distribution is noted in our study.

Aneurysm shape was categorized by de Rooji NK et al,<sup>[26]</sup> into spherical, non-spherical, and irregularly shaped. Daan Backes, MD et al,<sup>[27]</sup> study concluded that irregular shaped aneurysms and aspect ratio  $>1.3$  are associated with aneurysm rupture independent of aneurysm size and location, and independent of patient characteristics. Thus, 5(21.7%) aneurysms in our study are at higher risk of rupture considering shape of aneurysm alone.

Aneurysms with size  $<7$ mm is seen in 13 (56.5%) aneurysms and  $>7$ mm in size in 10 (43.5%) aneurysms. According to D.O. Wiebers,<sup>[24]</sup> size and location are the two important factors predicting risk of rupture. A.Morita et al,<sup>[25]</sup> in a Japanese cohort study stated that, the risk of rupture increased with size for aneurysms measuring 7mm or larger. Thus considering size alone, 13 (56.5%) aneurysms in our study are at higher risk of rupture.

Among 23 aneurysms detected in 18 patients on CTA, bifurcation type of parent artery configuration is seen in 12(52%) aneurysms and side wall type of configuration in 11(48%). Bifurcation type, are at higher risk of rupture compared to sidewall type.

Among 21 aneurysms, aneurysms with narrow neck are seen in 18 (78.2%) and with wide neck are seen in 5 (21.8%). According to J. Thornton et al,<sup>[2]</sup> study on detachable coiling for intracranial aneurysms in 2001, Neck width, along with dome to neck ratio is an important predictor for identifying ideal candidates for use of coiling alone for aneurysms with Narrow neck (width $<4$ mm) and adjunct techniques (balloon inflation or stent placement) for aneurysms with wide neck (width $>4$ mm). These adjunct techniques prevent coil migration in wide neck aneurysm in to parent artery, therefore reduce the risk of thromboembolism. Thus, neck width is an important factor determining the choice of technique to be employed in the management of aneurysms.

Among 21 aneurysms aspect ratio  $>1.3$  were seen in 17 (80.9%) and with  $<1.3$  in 4 (19.04%). Daan Backes, MD et al,<sup>[27]</sup> study concluded that irregular shaped aneurysms and aspect ratio  $>1.3$  are associated with aneurysm rupture independent of aneurysm size and location, and independent

of patient characteristics. Considering aspect ratio alone, 17(80.9%) aneurysms among 21 are at higher risk of rupture in our study.

Norman Ajiboye et al,<sup>[28]</sup> Based on patient age, aneurysm characteristics, associated risks and benefits of intervention formulated an approach for the management of un ruptured aneurysm. Following his protocol, 6 aneurysms require conservative management and 17 requires either coiling or clipping in our study.

Among 60 cases included in the study, right foetal PCA is seen in 7 patients, left foetal PCA in 7 patients, bilateral foetal PCA in 3 patients, azygous A2 in 3 patients, basilar fenestration in 4 patients, M1 (MCA) fenestration in 1 patient, left vertebral artery arising directly from arch of aorta in 3 patients and left CCA arising from innominate artery in 2 patients. Most common anatomical variant in cervicocerebral vasculature encountered in our study are both right foetal PCA and Left foetal PCA seen in 7 patients each. It is estimated that lack of knowledge of anatomical variants is the cause of about 10% of medical errors. Sanders WP, Sorek PA, Mehta BA study observed an association between fenestration and aneurysm formation.<sup>[29]</sup> Simon J. Dimmick, B Pthy, Kenneth C. Faulder review stated that the knowledge of the presence and clinical relevance of normal variants such as fenestrations, duplications, and persistent foetal arteries plays a crucial role in the diagnosis and management of acute stroke and subarachnoid hemorrhage and may aid in surgical planning.<sup>[15]</sup> Fenestration has a risk of aneurysm formation. Thus careful evaluation and reporting is required. Azygous ACA is an important normal variant because, thromboembolism in this variant leads to infarct in bilateral ACA territories. As seen in one of our study population. Out of 33 hypoplastic segments, Most commonly encountered hypoplastic segments were A1 segment of right ACA and Left PCA.

Among 25 cases with hemorrhagic stroke, only 1 patient is diagnosed to have Arteriovenous malformation (AVM). Spetzler-Martin Scale is used to estimate the risk of surgical resection of an AVM with higher grades being associated with greater surgical morbidity and mortality.

A meta-analysis comprising 2425 patients treated between 1990 and 2000 showed a surgical mortality of 3.3% and a permanent postoperative morbidity of 8.6%, with an increasing morbidity-mortality rate associated with an increasing Spetzler-Martin grade.<sup>[30]</sup>

Following Spetzler-Martin grading scale for AVM's, our patient scores 2 points for size (medium), 1 point for eloquent site (language) and 1 point for pattern of venous drainage. According to this scale, our patient is at greater risk of surgical morbidity and mortality.

Thus, CTA as an imaging modality in a patient with cerebral AVM's is immensely helpful in preoperative work up, patient management and assessing surgical morbidity and mortality.

Characteristic	Number of points assigned
<b>Size of AVM</b>	
Small (<3 cm)	1 point
Medium (3–6 cm)	2 points
Large (>6 cm)	3 points
<b>Location</b>	
Noneloquent site	0 points
Eloquent site*	1 point
<b>Pattern of venous drainage</b>	
Superficial only	0 points
Deep component	1 point

\*Sensorimotor, language, visual cortex, hypothalamus, thalamus, internal capsule, brain stem, cerebellar peduncles, or cerebellar nuclei.

Figure 5: Showing Spetzler-Martin grading scale for AVM's

## Conclusion

Hypertension was the most common risk factor associated with this disease, followed by diabetes. CTA helps in accurate diagnosis, risk stratification and planning management protocols.

## References

- Krishnamurthi RV, Feigin VL, Forouzanfar MH, Mensah GA, Connor M, Bennett DA. Global and regional burden of first-ever ischaemic and haemorrhagic stroke during 1990-2010: findings from the Global Burden of Disease Study. *The Lancet Global health*. 2010;1(5):259–81. Available from: [https://doi.org/10.1016/S2214-109X\(13\)70089-5](https://doi.org/10.1016/S2214-109X(13)70089-5).
- Thornton J, Dovey Z, Alazzaz A, Misra M, Aletich VA, Debrun GM, et al. Surgery following endovascular coiling of intracranial aneurysms. *Surg Neurol*. 2000;54(5):352–360. Available from: [https://dx.doi.org/10.1016/s0090-3019\(00\)00337-2](https://dx.doi.org/10.1016/s0090-3019(00)00337-2).
- Prasad K, Vibha D, Meenakshi. Cerebrovascular disease in South Asia – Part I: A burning problem. *JRSM Cardiovascular Dis*. 2012;1(7):1–7. Available from: <https://dx.doi.org/10.1258/cvd.2012.012025>.
- Pandian JD, Sudhan P. Stroke Epidemiology and Stroke Care Services in India. *J Stroke*. 2013;15(3):128–128. Available from: <https://dx.doi.org/10.5853/jos.2013.15.3.128>.
- Hunter G, Hamberg LM, Lev MH, Gonzales RG. Computed Tomography Angiography and Perfusion Imaging of Acute Stroke. *Cerebral Blood Flow*. 2002;p. 165–178. Available from: [http://dx.doi.org/10.1007/978-3-642-56036-1\\_12](http://dx.doi.org/10.1007/978-3-642-56036-1_12).
- Schuknecht B. Latest techniques in head and neck CT angiography. *Neuroradiology*. 2004;46(S2):208–213. Available from: <https://dx.doi.org/10.1007/s00234-004-1334-8>.
- Ikedo T, Nakamura K, Sano N, Nagata M, Okada Y, Kawakami T, et al. Extracranial internal carotid artery dissection caused by compression from a giant osteophyte due to atlantoaxial osteoarthritis: case report. *J Neurosurg Spine*. 2017;27(4):410–414. Available from: <https://dx.doi.org/10.3171/2017.1.spine161047>.
- Schellinger PD. The Evolving Role of Advanced MR Imaging as a Management Tool for Adult Ischemic Stroke: A Western-European Perspective. *Neuroimaging Clin N Am*. 2005;15(2):245–258. Available from: <http://dx.doi.org/10.1016/j.nic.2005.06.003>.
- Lloyd-Jones D, Adams R, Carnethon M, Simone GD, Ferguson TB, Flegal K, et al. Heart disease and stroke statistics–2009 update: a report from the American Heart Association Statistics Committee and Stroke Statistics Subcommittee. *Circulation*. 2009;119(3):21–181. Available from: <https://doi.org/10.1161/circulationaha.108.191261>.
- Rosamond WD, Folsom AR, Chambless LE, Wang CH, McGovern PG, Howard G, et al. Stroke incidence and survival among middle-aged adults: 9-year follow-up of the Atherosclerosis Risk in Communities (ARIC) cohort. *Stroke*. 1999;30(4):736–779. Available from: <https://doi.org/10.1161/01.str.30.4.736>.
- Brown RD, Whisnant JP, Sicks JD, O'fallon WM, Wiebers DO. Stroke incidence, prevalence, and survival: secular trends in Rochester, Minnesota, through 1989. *Stroke*. 1996;27(3):373–380.
- Wolf PA, D'Agostino RB, O'Neal MA, Sytkowski P, Kase CS, Belanger AJ, et al. Secular trends in stroke incidence and mortality. The Framingham Study. *Stroke*. 1992;23(11):1551–1555. Available from: <https://dx.doi.org/10.1161/01.str.23.11.1551>.
- Dalal PM, Malik S, Bhattacharjee M, Trivedi ND, Vairale J, Bhat P, et al. Population-Based Stroke Survey in Mumbai, India: Incidence and 28-Day Case Fatality. *Neuroepidemiology*. 2008;31(4):254–261. Available from: <https://dx.doi.org/10.1159/000165364>.
- Sridharan SE, Unnikrishnan JP, Sukumaran S, Sylaja PN, Nayak SD, Sarma PS, et al. Incidence, Types, Risk Factors, and Outcome of Stroke in a Developing Country. *Stroke*. 2009;40(4):1212–1218. Available from: <https://dx.doi.org/10.1161/strokeaha.108.531293>.
- Townsend N, Wickramasinghe K, Bhatnagar P, Smolina KN, Leal M, Luengo-Fernandez J, et al. Coronary heart disease statistics. *British Heart Foundation 2012* 208 p;p. 1–1.
- Chason JL, Hindman WM. Berry Aneurysms of the Circle of Willis: Results of a Planned Autopsy Study. *Neurology*. 1958;8(1):41–41. Available from: <https://dx.doi.org/10.1212/wnl.8.1.41>.
- Strong K, Mathers C, Bonita R. Preventing stroke: saving lives around the world. *Lancet Neurol*. 2007;6(2):182–187. Available from: [https://dx.doi.org/10.1016/s1474-4422\(07\)70031-5](https://dx.doi.org/10.1016/s1474-4422(07)70031-5).
- Greving JP, Wermer MJH, Brown RD, Morita A, Juvella S, Yonekura M, et al. Development of the PHASES score for prediction of risk of rupture of intracranial aneurysms: a pooled analysis of six prospective cohort studies. *Lancet Neurol*.

- 2014;13(1):59–66. Available from: [https://dx.doi.org/10.1016/s1474-4422\(13\)70263-1](https://dx.doi.org/10.1016/s1474-4422(13)70263-1).
19. Wong KS, Li H. Long-term mortality and recurrent stroke risk among Chinese stroke patients with predominant intracranial atherosclerosis. *Stroke*. 2003;34(10):2361–2367.
  20. Menon BK, Kochar P, Ah-Seng A, Almekhlafi MA, Modi J, Wong JH, et al. Initial experience with a self-expanding retrievable stent for recanalization of large vessel occlusions in acute ischemic stroke. *Neuroradiology*. 2012;54(2):147–154. Available from: <https://dx.doi.org/10.1007/s00234-010-0835-x>.
  21. Eesa M, Hill MD, Al-Khathaami A, Al-Zawahmah M, Sharma P, Menon BK, et al. Role of CT Angiographic Plaque Morphologic Characteristics in Addition to Stenosis in Predicting the Symptomatic Side in Carotid Artery Disease. *Am J Neuro-radiol*. 2010;31(7):1254–1260. Available from: <https://dx.doi.org/10.3174/ajnr.a2078>.
  22. Ota H, Takase K, Rikimaru H, Tsuboi M, Yamada T, Sato A, et al. Quantitative Vascular Measurements in Arterial Occlusive Disease. *RadioGraphics*. 2005;25(5):1141–1158. Available from: <https://dx.doi.org/10.1148/rg.255055014>.
  23. Neurovascular Imaging: MRI & Microangiography. vol. 515; .
  24. Wiebers DO. Unruptured intracranial aneurysms: natural history, clinical outcome, and risks of surgical and endovascular treatment. *Lancet*. 2003;362(9378):103–110. Available from: [https://dx.doi.org/10.1016/s0140-6736\(03\)13860-3](https://dx.doi.org/10.1016/s0140-6736(03)13860-3).
  25. Morita A, Kirino T, Hashi K, Aoki N, Fukuhara S, Hashimoto N. The natural course of unruptured cerebral aneurysms in a Japanese cohort. *N Engl J Med*. 2012;366(26):2474–82.
  26. Rooij NK, Velthuis BK, Algra A, Rinkel GJE. Configuration of the circle of Willis, direction of flow, and shape of the aneurysm as risk factors for rupture of intracranial aneurysms. *J Neurol*. 2009;256(1):45–50. Available from: <https://dx.doi.org/10.1007/s00415-009-0028-x>.
  27. Backes D, Vergouwen MDI, Velthuis BK, van der Schaaf IC, Bor ASE, Algra A, et al. Difference in Aneurysm Characteristics Between Ruptured and Unruptured Aneurysms in Patients With Multiple Intracranial Aneurysms. *Stroke*. 2014;45(5):1299–1303. Available from: <https://dx.doi.org/10.1161/strokeaha.113.004421>.
  28. Ajiboye N, Chalouhi N, Starke RM, Zanaty M, Bell R. Unruptured Cerebral Aneurysms: Evaluation and Management. *Sci World J*. 2015;2015:1–10. Available from: <https://dx.doi.org/10.1155/2015/954954>.
  29. Anderson GB, Ashforth R, Steinke DE, Ferdinandy R, Findlay JM. CT Angiography for the Detection and Characterization of Carotid Artery Bifurcation Disease. *Stroke*. 2000;31(9):2168–2174. Available from: <https://doi.org/10.1161/01.STR.31.9.2168>.
  30. Castel JP, Kantor G. Postoperative morbidity and mortality after microsurgical exclusion of cerebral arteriovenous malformations. Current data and analysis of recent literature. *Neurochirurgie*. 2001;47(2-3):369–83.

**Copyright:** © the author(s), 2020. It is an open-access article distributed under the terms of the Creative Commons Attribution License (CC BY 4.0), which permits authors to retain ownership of the copyright for their content, and allow anyone to download, reuse, reprint, modify, distribute and/or copy the content as long as the original authors and source are cited.

**How to cite this article:** Mallula BV, Chintala JR, Boppana S, Annapurna S. Role of Multi Detector Computed Tomography Cervicocerebral Angiography in Evaluation of Patients with Stroke. *Asian J. Med. Radiol. Res*. 2020;8(1):93-99.

DOI: [dx.doi.org/10.47009/ajmrr.2020.8.1.17](https://dx.doi.org/10.47009/ajmrr.2020.8.1.17)

**Source of Support:** Nil, **Conflict of Interest:** None declared.