

# Fractional Carbon Dioxide Laser Technique Versus Derma Roller Therapy in Patients with Post-Acne Scars

Mayank Kaushik

Assistant Professor, Department of Dermatology, GS Medical College & Hospital, Pilkhuwa, Hapur, Uttar Pradesh, India.

## Abstract

**Background:** Acne vulgaris is a common skin disease presenting as non-inflammatory lesions, inflammatory lesions and varying degrees of scarring, affecting mostly the face but also the back and chest. The present study compared fractional carbon dioxide (CO<sub>2</sub>) laser technique (FCLT) versus derma roller therapy (DT) in patients with post-acne scars. **Subjects and Methods:** 56 patients with post-acne scars of both genders were classified into 2 groups of 28 each. Group I patients were treated with derma roller therapy and the other group was treated with fractional CO<sub>2</sub> laser every 4 weeks over a period of 24 weeks. An objective and subjective baseline assessment was done for each patient using global acne scarring classification. **Results:** Response was satisfactory seen in 7 in group I and 2 in group II, good in 8 and 10, very good in 10 and 12 and excellent in 3 and 4 in group I and II respectively. The mean objective score at baseline in group I was 29.5 and at follow up was 16.5 and in group II at baseline was 29.8 and at follow up was 15.2. The difference was significant ( $P < 0.05$ ). **Conclusion:** Both the modalities were found to be equally efficacious in management of post acne scars.

**Keywords:** Acne, fractional CO<sub>2</sub> laser, Scars.

**Corresponding Author:** Mayank Kaushik, Assistant Professor, Department of Dermatology, GS Medical College & Hospital, Pilkhuwa, Hapur, Uttar Pradesh, India.

Received: 25 June 2021

Revised: 09 August 2021

Accepted: 24 August 2021

Published: 21 September 2021

## Introduction

Acne vulgaris is a common skin disease presenting as non-inflammatory lesions, inflammatory lesions and varying degrees of scarring, affecting mostly the face but also the back and chest. Acne leads to significant morbidity that is associated with residual scarring and psychological disturbances such as poor self-image, depression, and anxiety, which leads to a negative impact on quality of life.<sup>[1]</sup> The pathogenesis of acne scars involves injury to the skin which initiates a chain of events leading to wound healing. The wound healing process progresses through 3 stages inflammation, granulation tissue formation, and matrix remodeling.<sup>[2]</sup>

Post-acne scarring is one of the most common causes of disfiguring scars over the face. Studies have shown that nearly 80% of patients with acne have some scarring and 50% have clinically relevant scarring. Acne scarring is commonly seen in adolescence and young adults causing marked psychological distress. Dermatology life quality index (DLQI) in these patients is significantly lower than in patients without scars.<sup>[3]</sup>

Various methods such as chemical peels, microdermabrasion, lasers - non-ablative, ablative lasers, fractional photo ther-

molysis (FP), techniques - punch excision, pin point irradiation technique, radio-frequency (RF), punch elevation, punch replacement grafting, tissue augmenting agents, micro-needling, subcision, combined therapy, stem cell therapy, IPL are widely used.<sup>[4]</sup>

The improvement in appearance of acne scars following fractional CO<sub>2</sub> laser is due to the combination of processes of healing that initiates new collagen deposition after ablation and collagen remodeling initiated by the zone of coagulation surrounding the ablated area. CO<sub>2</sub> lasers produce significant improvement at the cost of long recovery times and post-inflammatory hyperpigmentation. Micro needling fractional radiofrequency (MFR) is a recent procedure for managing scars and not lead to damage the epidermis.<sup>[5]</sup> The present study compared fractional carbon dioxide (CO<sub>2</sub>) laser technique (FCLT) versus derma roller therapy (DT) in patients with post-acne scars.

## Subjects and Methods

This study consisted of 56 patients with post-acne scars of both genders. They were enrolled with their written consent.

All those patients who had acne scars under the groupings of a score >3 points on global acne scarring classification scale were included.

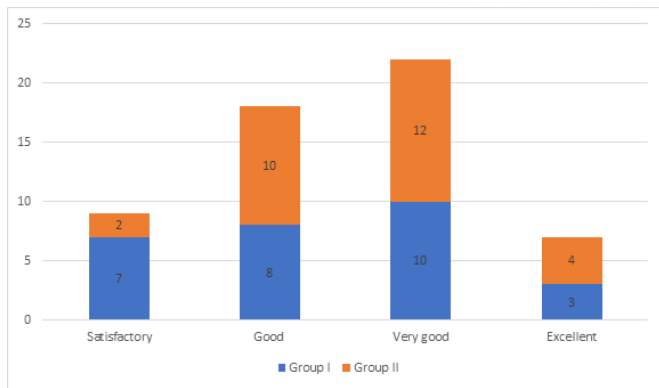
Data related to them were recorded in case proforma. Patients were classified into 2 groups of 28 each. Group I patients were treated with derma roller therapy and the other group was treated with fractional CO2 laser every 4 weeks over a period of 24 weeks. An objective and subjective baseline assessment was done for each patient using global acne scarring classification. All findings were recorded and compared statistically using Mann Whitney U test. P value less than 0.05 was considered significant.

**Results**

**Table 1: Objective assessment of patients**

Response	Group I	Group II	P value
Satisfactory	7	2	0.01
Good	8	10	
Very good	10	12	
Excellent	3	4	

[Table 1, Figure 1] shows that response was satisfactory seen in 7 in group I and 2 in group II, good in 8 and 10, very good in 10 and 12 and excellent in 3 and 4 in group I and II respectively. The difference was significant (P< 0.05).



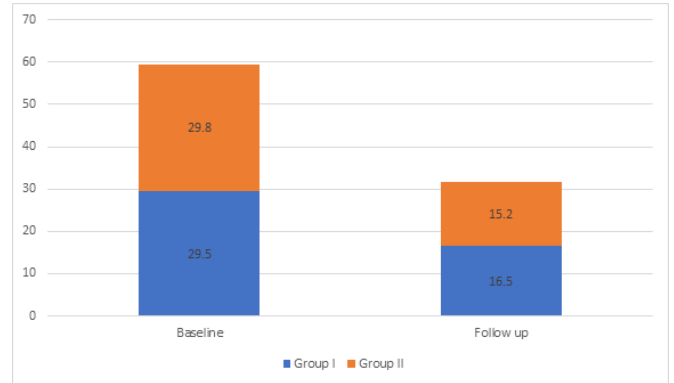
**Figure 1: Objective assessment of patients**

**Table 2: Comparison of objective score in both groups**

Duration	Group I	Group II	P value
Baseline	29.5	29.8	0.041
Follow up	16.5	15.2	

[Table 2, Figure 2] shows that mean objective score at baseline in group I was 29.5 and at follow up was 16.5 and in group II

at baseline was 29.8 and at follow up was 15.2. The difference was significant (P< 0.05).



**Figure 2: Comparison of objective score in both groups**

**Discussion**

Acne vulgaris is the most inflammatory illness of pilosebaceous part occur in young persons and teenager which cause multiple troubling and hard to treat scars. It is a common condition with prevalence as high as 80% among adolescents and persists to adulthood. Scarring can be a complication of untreated acne due to skin injury through the mechanism of heals of skin. Two kinds found according to decrease or increase of collagen: atrophic plus hypertrophic. Atrophic one occur due to decrease of collagen post inflammatory acne.<sup>[6]</sup> There are three types-ice pick, rolling and boxcar. Scarring occur after acne is considered worrying difficulty. Severe scarring is associated with psychological distress, particularly in young adults, and often results in decreased self-confidence and diminished quality of life.<sup>[7]</sup>

Various treatment modalities are used for acne scars including not invasive and invasive procedures, non-invasive: (biochemical peels, retinoid topically, microdermabrasion) and small invasive: (lasers, small needle radiofrequency apparatus) and invasive: (surgery for acne scar, laser for ablation), each technique with benefits and difficulties.<sup>[8]</sup> Treatment of acne scarring is a common indication for ablative lasers, more improvement is seen after CO2 laser than other techniques. The fractional devices, both ablative and non-ablative, have been used for traditionally.<sup>[9]</sup> The present study compared fractional carbon dioxide (CO2) laser technique (FCLT) versus derma roller therapy (DT) in patients with post-acne scars.

In present study, response was satisfactory seen in 7 in group I and 2 in group II, good in 8 and 10, very good in 10 and 12 and excellent in 3 and 4 in group I and II respectively. Abel et al,<sup>[10]</sup> enrolled a total of 200 patients of post acne scars. The patients

were randomly allocated into two groups of 100 patients each in which one group was treated with derma roller therapy and the other group was treated with fractional CO<sub>2</sub> laser every 4 weeks over a period of 24 weeks each. In the derma roller group, 89 patients completed the treatment with 11 drop out cases. The percentage reduction in the mean objective scores was found to be 37.63%. In the fractional CO<sub>2</sub> laser group, 93 patients completed the treatment with 7 drop out cases. The percentage reduction in mean objective scores was found to be 41.22%.

We observed that mean objective score at baseline in group I was 29.5 and at follow up was 16.5 and in group II at baseline was 29.8 and at follow up was 15.2. Pooja et al,<sup>[11]</sup> evaluated the efficacy and adverse effects of fractional CO<sub>2</sub> laser, microneedling, and platelet-rich plasma (PRP) in post-acne scarring. Sixty clinically diagnosed cases of post-acne scarring of both sexes were enrolled and divided into three groups of 20 patients each. The severity of scarring was graded as per the qualitative and quantitative grading system proposed by Goodman and Baron. Group A, B, and C patients were treated with fractional CO<sub>2</sub> laser, microneedling, and PRP, respectively, at monthly intervals for four sessions. Improve in quantitative and qualitative grades of scars and adverse effects were noted at each session and 1 month after the final sitting. At the end of four sessions, based on mean percentage of improvement in quantitative grade, the efficacy of fractional CO<sub>2</sub> laser is significantly greater than that of PRP ( $P = 0.00$ ), while CO<sub>2</sub> laser and microneedling did not show significant difference ( $P = 0.106$ ). Based on qualitative scores, fractional CO<sub>2</sub> laser group showed statistically higher therapeutic efficacy compared to microneedling and PRP. No significant adverse effects were encountered in any groups.

Al-Sultany et al,<sup>[12]</sup> in their study a total of 42 patients of atrophic facial acne scar with an age range between 20-48 years (average 36 years), and Fitzpatrick skin type II-V were taken. The 42 patients were randomly divided into two groups each involved 21 patients (15 females and 6 males); group A included those patients who were offered fractional CO<sub>2</sub> laser, and group B included patients who were offered micro needling radiofrequency. The therapeutic sessions were applied once monthly for four months for both groups. Both groups statistically matched regarding age, gender, severity of acne scars and Fitzpatrick skin type. Goodman and Baron Gauge besides Quartile classifying gauge measured the efficacy of fractional CO<sub>2</sub> laser compared to that of micro needling radiofrequency. Regarding the estimation of improvement after the full period of treatment for each modality of therapy using Goodman and Baron scale exposed that, both groups of patients displayed statistically significant percentage of improvement.

## Conclusion

Authors found that both the modalities were found to be equally efficacious in management of post acne scars.

## References

1. Cowin AJ, Brosnan MP, Holmes TM, Ferguson M. Endogenous inflammatory response to dermal wound healing in the fetal and adult mouse. *Dev Dyn*. 1998;212(3):385–393. Available from: [https://doi.org/10.1002/\(sici\)1097-0177\(199807\)212:3%3C385::aid-aja6%3E3.0.co;2-d](https://doi.org/10.1002/(sici)1097-0177(199807)212:3%3C385::aid-aja6%3E3.0.co;2-d).
2. Goodman G. Post acne scarring: a review. *J Cosmet Laser Ther*. 2003;5(2):77–95. Available from: <https://doi.org/10.1080/14764170310001258>.
3. Sadick NS, Palmisano L. Case study involving use of injectable poly-L-lactic acid (PLLA) for acne scars. *J Dermatolog Treat*. 2009;20(5):302–307. Available from: <https://doi.org/10.1080/09546630902817879>.
4. Kravvas G, Niaiimi AF. A systematic review of treatments for acne scarring. Part 1: Non-energy-based techniques. *Scars Burn Heal*. 2017;3:2059513117695312. Available from: <https://doi.org/10.1177/2059513117695312>.
5. Gozali MV, Zhou B. Effective treatments of atrophic acne scars. *J Clin Aesthet Dermatol*. 2015;8(5):33–40.
6. Goodman GJ, Baron JA. Postacne scarring: a qualitative global scarring grading system. *Dermatol Surg*. 2006;32(12):1458–1466. Available from: <https://doi.org/10.1111/j.1524-4725.2006.32354.x>.
7. Stem R. The prevalence of acne on the basis of physical examination. *J Am Acad Dermatol*. 1992;26(6):931–935. Available from: [https://doi.org/10.1016/0190-9622\(92\)70135-3](https://doi.org/10.1016/0190-9622(92)70135-3).
8. Reich A, Jasiuk B, Samotij D, Tracinska A, Trybucka K, Szepletowski JC. Acne vulgaris: what teenagers think about it. *Dermatol Nurs*. 2007;19(1):49–54.
9. Adityan B, Thappa DM. Profile of acne vulgaris: a hospital-based study from South India. *Indian J Dermatol Venereol Leprol*. 2009;75(3):272–278. Available from: <https://doi.org/10.4103/0378-6323.51244>.
10. Abel F, Herakal K, Shetty N. A comparative study of efficacy of resurfacing with fractional carbon dioxide laser versus derma roller in the treatment of post acne scars. *Int J Res Dermatol*. 2020;6(5):616–621. Available from: <http://dx.doi.org/10.18203/issn.2455-4529.IntJResDermatol20203074>.
11. Pooja T, Gopal KV, Rao TN, Devi BG, Kumar SA. A randomized study to evaluate the efficacy fractional CO<sub>2</sub> laser, microneedling and platelet rich plasma in post-acne scarring. *Indian Dermatol Online J*. 2020;11(3):349–354. Available from: [https://dx.doi.org/10.4103/idoj.IDOJ\\_370\\_19](https://dx.doi.org/10.4103/idoj.IDOJ_370_19).
12. Ha AS. A comparative study of the efficacy of fractional CO<sub>2</sub> laser versus micro needling fractional radiofrequency in the management of atrophic acne scars among Iraqi patients. *Ann Trop Med Public Health*. 2020;23(18):231–239. Available from: <http://dx.doi.org/10.36295/ASRO.2020.231816>.

**Copyright:** © the author(s), 2021. It is an open-access article distributed under the terms of the Creative Commons Attribution License (CC BY 4.0), which permits authors to retain ownership of the copyright for their content, and allow anyone to download, reuse, reprint, modify, distribute and/or copy the content as long as the original authors and source are cited.

**How to cite this article:** Kaushik M. Fractional Carbon Dioxide Laser Technique Versus Derma Roller Therapy in Patients with Post-Acne Scars. Asian J. Med. Res. 2021;10(3):1-4.

DOI: [dx.doi.org/10.47009/ajmr.2021.10.3.DT1](https://doi.org/10.47009/ajmr.2021.10.3.DT1)

**Source of Support:** Nil, **Conflict of Interest:** None declared.

