

## Ocular Manifestations of Type 1 Diabetes Mellitus- A Case Control Study

Ashish Jain<sup>1\*</sup>, Priyanka Jain<sup>2</sup>, Rajesh Ranjan<sup>3</sup>

<sup>1</sup>Assistant Professor, Department of Ophthalmology, Rama Medical College, Hapur, Uttar Pradesh, India.

<sup>2</sup>Assistant Professor, Department of Pediatrics, Rama Medical College, Hapur, Uttar Pradesh, India.

<sup>3</sup>Associate Professor, Department of Community Medicine, Rama Medical College, Hapur, Uttar Pradesh, India.

### Abstract

**Introduction:** To assess ocular manifestations of type 1 diabetes mellitus.

**Methods:** 62 type I diabetes patients of either gender and equal number of healthy controls were taken in the study. Tear film break- up time (BUT), Schirmer test and BUT was performed.

**Results:** There were 30 males and 32 females in group I and 34 males and 28 females in group II. The mean age in group I was 10.2 years and in group II was 11.1 years. Duration of diabetes was 8.4 years in group I. Schirmer test value in group I was 14.2 and in group II was 21.5. IOP was 16.5 mm Hg in group I and 14.1 mm Hg in group II. Tear break- up time (BUT) was 13.7 seconds in group I and 12.4 seconds in group II. Central corneal thickness was 532.7  $\mu\text{m}$  in group I and 560.3  $\mu\text{m}$  in group II. Total macular volume (TMV) was 6.52 mm<sup>3</sup> in group I and 7.02 mm<sup>3</sup> in group II. Central retinal thickness (CRT) was 158.2  $\mu\text{m}$  in group I and 190.4  $\mu\text{m}$  in group II. A significant difference was observed ( $P < 0.05$ ).

**Conclusion:** Pediatric patients with type I diabetes are at high risk of diabetic retinopathy. Type 1 DM patients exhibited significantly reduced Schirmer test, increased IOP and decreased retinal thickness.

**Key Words:** Diabetes mellitus, Schirmer test, Tear break- up time.

### INTRODUCTION

Diabetes mellitus (DM) as a systemic disease, has several well- known microvascular complications such as diabetic retinopathy (DR), neuropathy, and nephropathy. Diabetes- related autonomic neuropathy can involve ocular structures including lacrimal gland, cornea, and retina.<sup>[1]</sup>

Clinical consequences of the disease included two major classes, small vessel and large vessels disorders.<sup>[2]</sup> Peripheral nerves involvement, damage to kidney and damage to retina are the small vessel disease consequences.<sup>[3]</sup> Large vessel complications are mainly attributable to accelerated atherosclerosis with eventual increase in the risk of ischemic heart disease and cerebrovascular accidents.<sup>[4]</sup> A number of consequences have been seen in the eye such as eye surface disorders, damage to retina, raised intra-ocular pressure and opacity of lens. Eye consequences in association with hyperglycemia are common health issues among community, therefore, efforts must be spent to highlights the prevalence, the pathology and the approach to treat these consequences.<sup>[5]</sup> The prevalence of DR in young children is low (varies from 10% to 35%), depending on the different studies but the risk of developing microvascular complications may increase during the teenage years. The detection of these microvascular complications needs careful examination of an anterior and posterior segment of the eye through a purposeful screening program.<sup>[6]</sup>

Mechanistically, the changes in the microvasculature result in increased vascular permeability and ischemia.

The most profound effects of these alterations are seen in the cornea and retina of the eye.<sup>[7]</sup> Once the eye has been exposed to hyperglycemia long-term, the basement membrane has accumulated enough toxic end products to lead to cell death, opacity, and eventually vision impairment.<sup>[8]</sup> Considering this, the present study was attempted with the aim to assess ocular manifestations of type 1 diabetes mellitus.

### MATERIALS AND METHODS

A total of 62 type I diabetes patients in age ranged 8-15 years of either gender and equal number of healthy control subjects were part of the study. All agreed to participate in the study with their written consent. Approval was sorted from ethical review and research clearance committee.

After recording demographic characteristics of each participant, all patients underwent ophthalmic and physical examination. A 5 ml venous blood samples were taken to measure glycosylated hemoglobin (HbA1c) levels. Visual acuity was measured using an ETDRS chart. IOP was measured by noncontact tonometer. Diabetic retinopathy (DR) was characterized as the presence of leaking blood vessels, retinal swelling, such as macular edema, pale, fatty deposits on the retina (exudates), damaged nerve tissue (cotton- wool spots) and any changes in the blood vessels (neovascularization). Tear film break- up time (BUT) and the Schirmer test was performed for dry eyes determination. BUT was evaluated by measuring the time interval between a complete blinking and the formation of dry spots in a fluorescein stained tear film and that of 10 seconds (s) or less was considered abnormal. Results were studied with appropriate statistical test where p value below 0.05 was considered significant.

### Address for correspondence\*

**Dr. Ashish Jain**

Assistant Professor,  
Department of Ophthalmology,  
Rama Medical College,  
Hapur, Uttar Pradesh, India.

## RESULTS

There were 30 males and 32 females in group I and 34 males and 28 females in group II. The mean age in group I was 10.2 years and in group II was 11.1 years. Duration of diabetes was 8.4 years in group I. A non- significant difference was observed ( $P > 0.05$ ) [Table 1].

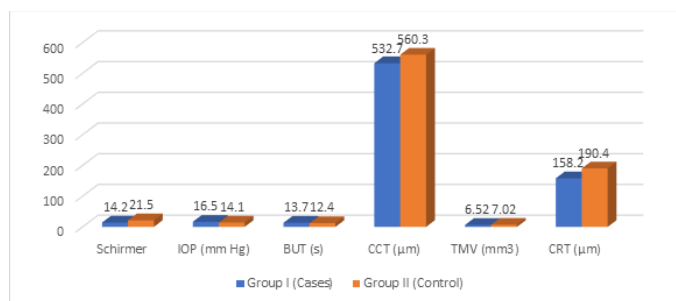
**Table 1: Patient characteristics**

Characteristics	Group I (Cases)	Group II (Control)	P value
Male	30	34	>0.05
Female	32	28	
Mean age (years)	10.2	11.1	>0.05
Duration of diabetes (years)	8.4	-	>0.05

**Table 2: Comparison of parameters in both groups**

Parameters	Group I (Cases)	Group II (Control)	P value
Schirmer	14.2	21.5	>0.05
IOP (mm Hg)	16.5	14.1	<0.05
BUT (s)	13.7	12.4	>0.05
CCT ( $\mu\text{m}$ )	532.7	560.3	>0.05
TMV ( $\text{mm}^3$ )	6.52	7.02	>0.05
CRT ( $\mu\text{m}$ )	158.2	190.4	<0.05

Schirmer test value in group I was 14.2 and in group II was 21.5. IOP was 16.5 mm Hg in group I and 14.1 mm Hg in group II. Tear break- up time (BUT) was 13.7 seconds in group I and 12.4 seconds in group II. Central corneal thickness was 532.7  $\mu\text{m}$  in group I and 560.3  $\mu\text{m}$  in group II. Total macular volume (TMV) was 6.52  $\text{mm}^3$  in group I and 7.02  $\text{mm}^3$  in group II. Central retinal thickness (CRT) was 158.2  $\mu\text{m}$  in group I and 190.4  $\mu\text{m}$  in group II. A significant difference was observed ( $P < 0.05$ ) [Table 2, Figure 1].



## DISCUSSION

Diabetic Retinopathy (DR) is a progressive blinding disease that affects 4.2 million people worldwide, making it a leading cause of blindness; and, this number is expected to continue to increase.<sup>[9]</sup> DR can be divided into two types, non-proliferative DR (NPDR) and proliferative DR (PDR).<sup>[10]</sup> NPDR can be further divided into three stages before progressing to PDR. An important difference between NPDR and PDR is that vision is not compromised with NDPR, whereas PDR is vision threatening.<sup>[11]</sup> While NPDR almost always progresses to PDR, the progression can be delayed with tight blood glucose control. In patients with diabetes, lacrimation might be impaired by autonomic neuropathy and damage to the microvasculature of the lacrimal gland.<sup>[12]</sup> Furthermore, there are studies suggesting that Type 2 DM is commonly associated with thicker corneas and increased intraocular pressure (IOP). There is evidence suggesting that neuronal changes have an important role in the development of DR in patients with Type

2 DM.<sup>[13]</sup> The present study was attempted with the aim to assess ocular manifestations of type 1 diabetes mellitus.

Our study showed that there were 30 males and 32 females in group I and 34 males and 28 females in group II. The mean age in group I was 10.2 years and in group II was 11.1 years. Duration of diabetes was 8.4 years in group I. Akil et al,<sup>[14]</sup> investigated the diabetes- related ocular changes according to the glycosylated hemoglobin (HbA1c) level and duration of diabetes in children and compare the results with nondiabetic healthy children. Forty- two children with Type 1 DM, 42 healthy gender- and age- matched children as controls were enrolled. Type 1 DM group exhibited significantly reduced Schirmer test, increased IOP and decreased retinal thickness relative to the age- matched control group ( $P < 0.05$ ) but no statistically significant difference was found for the BUT ( $P = 0.182$ ) and for the CCT ( $P = 0.495$ ). The correlations between the age, duration, HbA1c and IOP, BUT, Schirmer test, TMV, CRT measurements did not reach statistical significance.

Our study showed that Schirmer test value in group I was 14.2 and in group II was 21.5. IOP was 16.5 mm Hg in group I and 14.1 mm Hg in group II. Tear break- up time (BUT) was 13.7 seconds in group I and 12.4 seconds in group II. Waheed et al,<sup>[15]</sup> assessed the ocular manifestation in patient with type 1 diabetes mellitus in comparison with non-diabetic children. Assessment visual acuity in patients with type 1 diabetes mellitus and control subjects revealed that 58 (77.3 %) of patients had normal visual acuity and that 59 (78.7 %) of control subjects had normal visual acuity. Abnormal visual acuity was identified in 17 (22.7 %) of patients and in 16 (21.3 %) of control subjects and the difference was statistically insignificant ( $P = 0.844$ ). Abnormal Schirmer's test with dry eye was seen in 11 (14.7 %) of patients and in 3 (4.0 %) of control subjects ( $P = 0.025$ ). Abnormal findings upon fundoscopic examination were identified in 2 (2.7 %) of patients in comparison with none of control subjects. Intraocular pressure (IOP) was abnormally high in 8 (10.7 %) of patients in comparison with 1 (1.3 %) of control subjects; the difference was significant. Visual field defect was identified in 2 (2.7%) of patients in comparison with 1 (1.3 %) of control subjects with non- significant difference.

Our results demonstrated that central corneal thickness was 532.7  $\mu\text{m}$  in group I and 560.3  $\mu\text{m}$  in group II. Total macular volume (TMV) was 6.52  $\text{mm}^3$  in group I and 7.02  $\text{mm}^3$  in group II. Central retinal thickness (CRT) was 158.2  $\mu\text{m}$  in group I and 190.4  $\mu\text{m}$  in group II. Binder et al reported that sicca symptoms affected some Type 1 diabetic patients only during the hyperglycemic phases. They concluded that this could result from high extracellular fluid osmolarity disturbing tear production, rather than represent a chronic complication of diabetes.

Goebbels found neither a significant decrease in the amount of aqueous tear flow nor an impaired tear BUT among insulin- treated diabetic patients.<sup>[16]</sup> They reported that Schirmer test readings were significantly decreased, and there were more signs of conjunctival metaplasia.

## CONCLUSION

Pediatric patients with type I diabetes are at high risk of diabetic retinopathy. Type 1 DM patients exhibited significantly reduced Schirmer test, increased IOP and decreased retinal thickness.

**REFERENCES**

1. Klein BE, Klein R, Jensen SC. Open- angle glaucoma and older- onset diabetes. The Beaver Dam Eye Study. *Ophthalmology* 1994;101:1173- 7.
2. Mitchell P, Smith W, Chey T, Healey PR. Open- angle glaucoma and diabetes: The Blue Mountains eye study, Australia. *Ophthalmology* 1997;104:712- 8.
3. Barber AJ. A new view of diabetic retinopathy: A neurodegenerative disease of the eye. *Prog Neuropsychopharmacol Biol Psychiatry* 2003;27:283- 90.
4. A protocol for screening for diabetic retinopathy in Europe. Retinopathy Working Party. *Diabet Med* 1991;8:263- 7.
5. American Academy of Pediatrics. Screening for retinopathy in the pediatric patient with type 1 diabetes mellitus. *Pediatrics* 1998;101:313- 4.
6. Kaiserman I, Kaiserman N, Nakar S, Vinker S. Dry eye in diabetic patients. *Am J Ophthalmol* 2005;139:498- 503.
7. Falck AA, Käär ML, Laatikainen LT. Prevalence and risk factors of retinopathy in children with diabetes. A population- based study on Finnish children. *Acta Ophthalmol (Copenh)* 1993;71:801- 9.
8. Maguire A, Chan A, Cusumano J, Hing S, Craig M, Silink M, et al. The case for biennial retinopathy screening in children and adolescents. *Diabetes Care* 2005;28:509- 13.
9. The Diabetes Control and Complications Trial Research Group. Effect of intensive diabetes treatment on the development and progression of long- term complications in adolescents with insulin- dependent diabetes mellitus: Diabetes control and complications trial. *J Pediatr* 1994;125:177- 88.
10. Bonney M, Hing SJ, Fung AT, Stephens MM, Fairchild JM, Donaghue KC, et al. Development and progression of diabetic retinopathy: Adolescents at risk. *Diabet Med* 1995;12:967- 73.
11. Mohsin F, Craig ME, Cusumano J, Chan AK, Hing S, Lee JW, et al. Discordant trends in microvascular complications in adolescents with type 1 diabetes from 1990 to 2002. *Diabetes Care* 2005;28:1974- 80.
12. Hee MR, Puliafito CA, Duker JS, Reichel E, Coker JG, Wilkins JR, et al. Topography of diabetic macular edema with optical coherence tomography. *Ophthalmology* 1998;105:360- 70.
13. Binder A, Maddison PJ, Skinner P, Kurtz A, Isenberg DA. Sjögren's syndrome: Association with type- 1 diabetes mellitus. *Br J Rheumatol* 1989;28:518- 20.
14. Akil H, Buluş AD, Andiran N, Alp MN. Ocular manifestations of Type 1 diabetes mellitus in pediatric population. *Indian J Ophthalmol* 2016;64:654-8.
15. Waheed MR, Al-Hajjiah N. Ocular Complications in Children with Type 1 Diabetes Mellitus in Al-Diwaniyah Province: Case Control Study. *Annals of the Romanian Society for Cell Biology*. 2021 Apr 9:1468-75.
16. Goebbels M. Tear secretion and tear film function in insulin dependent diabetics. *Br J Ophthalmol* 2000;84:19- 21.