

Status of Immediate Versus Delayed Loading of Dental Implants in a Tertiary Care Teaching Hospital

Somnath Chakraborty^{1B}

Assistant Professor, Department of Dentistry, Gouri Devi Institute of Medical Sciences & Hospital, Rajbandh, Durgapur, West Bengal, India.

Abstract

Background: A proven solution for rehabilitation of partial or entire edentulism is dental implants and the survival charge of implant supported restorations is relatively high. Due to this fact an increasing number of human beings are choosing dental implants for rehabilitation. For single tooth gaps, implants serve as a treasured replacement alternative as proven by way of huge quantity of studies. **Subjects and Methods:** Total of forty six (46) patients reporting for the replacement of single missing tooth. Patients between age of 19-53 years have been enrolled within the study. **Results:** The mean bone levels on mesial and distal side amongst Group 1 subjects at 6 months were 0.74 ± 0.24 and 0.66 ± 0.23 respectively. The mean bone levels on mesial and distal side amongst Group 1 subjects at 12 months were 1.12 ± 0.33 and 1.03 ± 0.34 respectively. The mean bone levels on mesial and distal side amongst Group 2 subjects at 6 months were 0.77 ± 0.19 and 0.71 ± 0.52 respectively. The mean bone levels on mesial and distal side amongst Group 2 subjects at 12 months were 1.15 ± 0.14 and 1.13 ± 0.32 respectively. **Conclusion:** Comparison instant and not on time loading of the implants. Immediate loading established a surprisingly successful scientific outcome at the end of one year. But the survival rate of the implant that have been loaded immediately turned into inferior to those loaded by using conventional approach.

Keywords: Dental Implant, Loading & Outcome.

Corresponding Author: Somnath Chakraborty, Assistant Professor, Department of Dentistry, Gouri Devi Institute of Medical Sciences & Hospital, Rajbandh, Durgapur, West Bengal, India.

E-mail: rup_raman@yahoo.com

Received: 02 March 2020

Revised: 01 April 2020

Accepted: 12 April 2020

Published: 10 July 2020

Introduction

Publications describing the management of patient's edentulous maxillae mandible by immediate loading rehabilitation suggest an efficacious treatment protocol.^[1] However, long-term and controlled studies are lacking and further research is needed to demonstrate the effectiveness of such procedures.^[2] A proven solution for rehabilitation of partial or entire edentulism is dental implants and the survival charge of implant supported restorations is relatively high.^[3] Due to this fact an increasing number of human beings are choosing dental implants for rehabilitation. For single tooth gaps, implants serve as a treasured replacement alternative as proven by way of huge quantity of studies.^[4,5] In these days's implantology an increasing number of generic idea is that of on the spot loading for single enamel replacements. It implies to setting the prosthetic restorative material within 48 to 72 hours of implant placement.^[6] Various advantages supplied through this technique consist of higher beauty, functional and psychologic outcome for the patient. According to a Cochrane

systematic review of RCTs to examine implant loading timing, quick loading of mandibular implants in predetermined regions can be as effective as conventional implants at some point during the healing period.^[7] While a number of the studies have proven no vast difference in failure rates when instant loading and behind schedule loading had been compared, but few different studies recommend that implant disasters were drastically greater in instances wherein immediate loading was achieved compared to conventional loaded dental implants. The aim of the study was to evaluate the bone loss and the soft tissue situation of the conventionally loaded dental implants with those loaded without delay.

Subjects and Methods

This current study was conducted in the department of dentistry at Gouri Devi Institute of Medical College and Hospital, Durgapur during the period from January, 2017 to September, 2019. A total of forty six (46) patients reporting for the replacement of single missing tooth. Patients between age

of 19-53 years have been enrolled within the study. Patients with inadequate mouth opening, interarch distance, poor oral hygiene, retained roots or pathological conditions have been excluded from the study. Patients with contraindication to implant surgery were also not included in the study. The study was divided into two groups- Group-1: Consisted of subjects in whom on the spot loading of dental implant become completed and Group 2: Consisted of subjects who were controlled by using conventional loading of dental implants. The diameter and length of implants were based on the clinical and radiographic evaluation of the available bone. All the subjects were informed about the study and a written consent was obtained from them in their vernacular language. Stent was prepared for appropriate placement of the implants. Subjects were kept on an antibiotic regimen prior to implant placement and under complete aseptic conditions and using standard surgical procedures implants were placed. After implant placement soft tissue flap was closed using resorbable sutures and the radiographs were taken to assess the bone levels at time zero. Subjects were prescribed antibiotics and told to maintain good oral hygiene. Loading was performed after 48 hours in group a subjects with provisional crowns. Occlusion was adjusted to maintain lateral excursive and intercusp distance. Light contact with opposing tooth was made after 2 months. After 6 months final restoration was fabricated and kept at maximum inter cuspal position. In group 2, 6 months were given for osseointegration and after impression, casts were fabricated and mounted for crown fabrication. After 6 months, IOPA radiographs were taken to estimate the bone level and regarded as Time one and same was repeated after 12 months, regarded as Time two. Peri implant soft tissue evaluation was done at 6 months and 12 months. All the data was arranged in a tabulated form and analysed using SPSS software.

Results

This present study was conducted in the department of dentistry at Gouri Devi Institute of Medical College and Hospital, Durgapur. [Figure 1] shows the distribution of the subjects. There were 63.0% males and 37.0% females in the study. [Figure 2] There was 1 case of implant failure amongst both males and females. There were 17.1% (n=16) subjects between 15-25 years of age. There were 21.7% subjects between 25-35 years of age. There were 45.7% subjects between 35-45 years of age. There were 15.2% subjects between 45-55 years of age in [Figure 2]. There was one case of failure between 45-55 years of age group. There were 32.6% smokers and 67.4% non-smokers in [Figure 3]. There were two cases of implant failures amongst the smokers. Majority of the implants were placed in the mandible in [Figure 4]. The mean values of peri implant bone loss amongst the subjects. The mean bone levels on mesial and distal side amongst Group

1 subjects at 6 months were 0.74 ± 0.24 and 0.66 ± 0.23 respectively. The mean bone levels on mesial and distal side amongst Group 1 subjects at 12 months were 1.12 ± 0.33 and 1.03 ± 0.34 respectively. The mean bone levels on mesial and distal side amongst Group 2 subjects at 6 months were 0.77 ± 0.19 and 0.71 ± 0.52 respectively. The mean bone levels on mesial and distal side amongst Group 2 subjects at 12 months were 1.15 ± 0.14 and 1.13 ± 0.32 respectively [Table 1].

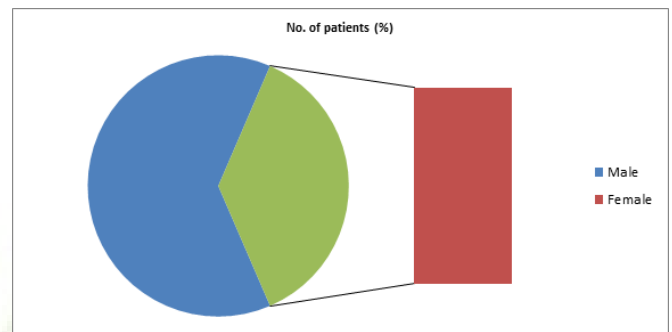


Figure 1: Shows the distribution subjects a/c to gender.

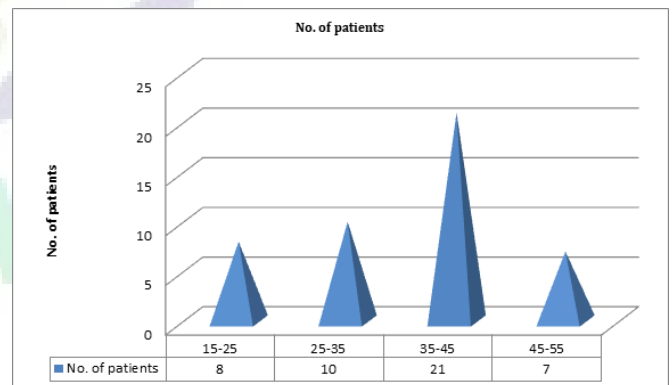


Figure 2: Shows the distribution subjects a/c to age wise.

The soft tissue condition amongst both the groups. The mean gingival index amongst Group 1 subjects at 6 months and 12 months were 0.57 ± 0.24 and 0.87 ± 0.33 respectively. The mean periodontal index amongst Group 1 subjects at 6 months and 12 months was 0.44 ± 0.31 and 0.68 ± 0.47 respectively. The mean gingival index amongst Group 2 subjects at 6 months and 12 months were 0.62 ± 0.53 and 0.91 ± 0.32 respectively. The mean periodontal index amongst Group 2 subjects at 6 months and 12 months was 0.51 ± 0.64 and 0.72 ± 0.44 respectively [Table 2].

Table 1: Mean values of peri implant bone loss

Follow up duration	Group 1		Group 2	
	Mesial	Distal	Mesial	Distal
6 months	0.74 ± 0.24	0.66 ± 0.23	0.77 ± 0.19	0.71 ± 0.52
12 months	1.12 ± 0.33	1.03 ± 0.34	1.15 ± 0.14	1.13 ± 0.32

Table 2: Soft tissue condition

Follow up duration	Group 1		Group 2	
	Gingival index	Periodontal Index	Gingival index	Periodontal Index
6 months	0.57 ± 0.24	0.44 ± 0.31	0.62 ± 0.53	0.51 ± 0.64
12 months	0.87 ± 0.33	0.68 ± 0.47	0.91 ± 0.32	0.72 ± 0.44

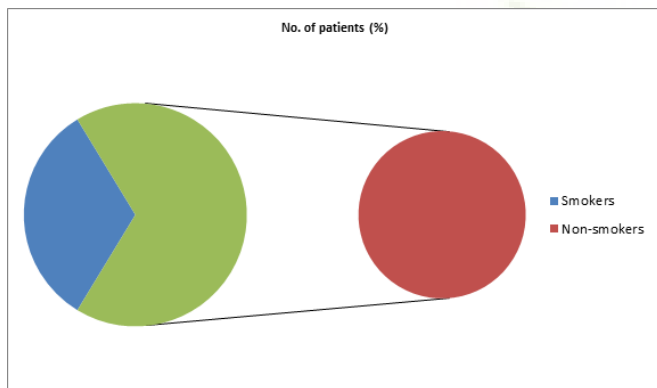


Figure 3: Shows the distribution subjects a/c to smoking habit.

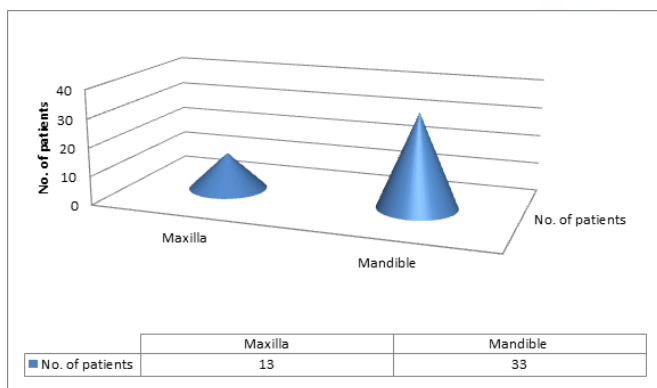


Figure 4: Shows the distribution of patients a/c to site.

Discussion

Based on the present study, the immediate loading protocol demonstrated good outcomes at the medium-term follow-up (12 months). The clinical auxiliary of lost enamel with the aid of Osseo incorporated dental implants has been regarded as one of the foremost advances inside the prosthetic dentistry. Implant dentistry has been the far most revolutionary and innovative developments in superior years specially within the improvement of latest implant management protocols, the improvement of latest and superior diagnostic techniques and the production of useful surgical strategies. Establishment of bone to Implant interface is the fundamental factor for the success of implant dentistry. Placement of implant is generally a two degree protocol.^[8] After placement implants are left to heal for a duration of three to four months within the mandible and for six-eight months in the maxilla for osseointegration. Due to this topics need to look forward to a significant time for the placement of prosthesis and must wear provisional prosthesis during that length and that is not esthetic. It turned into in the yr 1990 that the first look at became posted on the early or on the spot loading of the implant within the mandible of selected sufferers.^[9] Immediate loading is a usually completed surgery particularly inside the mandible with properly best of bone.^[10] In the prevailing take a look at, group 1 consisted of subjects in whom instantaneous loading of dental implant became achieved and group 2 consisted of topics who have been controlled by using traditional loading of dental implants and the results confirmed a comparative mean values both companies. Crespi R et al,^[11] carried a study to clinically investigate crestal bone degree change around single implants in fresh extraction sockets inside the esthetic sector of the maxilla both right now loaded or loaded after a postpone and the achievement rate and radiographic effects of immediately restorations of dental implants positioned in fresh extraction sockets had been similar to those obtained in behind schedule loading group. Similarly, Ebenezer V et al,^[12] pronounced that most of the immediate implants confirmed

amazing osseointegration.

The failure of immediate loading implants is due to continual micromovement of the implant caused by functional forces at the bone implant interface, which causes fibrous tissue to develop instead of the essential bone to implant contact, resulting in failure.^[13] The duration of the lag period between implant placement and loading has been studied for many years, and different authors have varying perspectives on it.^[14,15] The authors have yet to reach a consensus on the appropriate healing time between implant implantation and healing. It is also influenced by a number of factors. Therefore, it must be considered that overall differences between the two groups could affect the interpretation of the results.

Conclusion

These findings suggest that the comparison instant and not on time loading of the implants. Immediate loading established a surprisingly successful scientific outcome at the end of one year. But the survival rate of the implant that have been loaded immediately turned into inferior to those loaded by using conventional approach. Therefore, immediate loading need to be opted for subjects with excellent bone pleasant.

References

1. Menini M, Signori A, Tealdo T. Tilted implants in the immediate loading rehabilitation of the maxilla: A systematic review. *J Dent Res*. 2012;91:821–827. Available from: <https://doi.org/10.1177/0022034512455802>.
2. Mozzati M, Arata V, Gallezio G, Mussano F, Carossa S. Immediate post-extraction implant placement with immediate loading for maxillary full-arch rehabilitation: A two-year retrospective analysis. *J Am Dent Assoc*. 2012;143:124–133. Available from: <https://doi.org/10.14219/jada.archive.2012.0122>.
3. Kwon T, Bain PA, Levin L. Systematic review of short- (5-10 years) and long-term (10 years or more) survival and success of full-arch fixed dental hybrid prostheses and supporting implants. *J Dent*. 2014;42:1228–1241. Available from: <https://doi.org/10.1016/j.jdent.2014.05.016>.
4. Mangano FG, Shibli JA, Sammons RL, Iaculli F, Piattelli A, Mangano C, et al. Short (8-mm) locking-taper implants supporting single crowns in posterior region: a prospective clinical study with 1-to 10-years of follow-up. *Clin Oral Implants Res*. 2014;25(8):933–940. Available from: <https://doi.org/10.1111/clr.12181>.
5. Jung RE, Zembic A, Pjetursson BE, Zwahlen M, Thoma DS. Systematic review of the survival rate and the incidence of biological, technical, and aesthetic complications of single crowns on implants reported in longitudinal studies with a mean follow-up of 5 years. *Clin Oral Implants Res*. 2012;23(6):2–21. Available from: <https://doi.org/10.1111/j.1600-0501.2012.02547.x>.
6. Ghoul WE, Chidiac JJ. Prosthetic requirements for immediate implant loading: A review. *J Prosthodont*. 2012;21:141–154. Available from: <https://doi.org/10.1111/j.1532-849x.2011.00819.x>.
7. Boedeker D, Dyer J, Kraut R. Clinical outcome of immediately loaded maxillary implants: A 2-year retrospective study. *J Oral Maxillofac Surg*. 2011;69:1335–1343. Available from: <https://doi.org/10.1016/j.joms.2010.11.016>.
8. Esposito M, Grusovin MG, Willings M, Coulthard P, Worthington HV. Interventions for replacing missing teeth: different times for loading dental implants. *Cochrane Database Syst Rev*. 2007;18(2):3878. Available from: <https://doi.org/10.1002/14651858.cd003878.pub5>.
9. Schnitman PA, Wohrle PS, Rubenstein JE. Immediate fixed interim prosthesis supported by two-stage threaded implants: methodology and results. *J Oral Implantol*. 1990;16:96–105.
10. Branemark PI, Engstrand P, Ohnell LO. Branemark Novum: a new treatment concept for rehabilitation of the edentulous mandible. Preliminary results from a prospective clinical follow up study. *Clin Implant Dent Relat Res*. 1999;1:2–16. Available from: <https://doi.org/10.1111/j.1708-8208.1999.tb00086.x>.
11. Crespi R, Capparé P, Gherlone E, Romanos GE. Immediate versus delayed loading of dental implants placed in fresh extraction sockets in the maxillary esthetic zone: a clinical comparative study. *Int J Oral Maxillofac Implants*. 2008;23(4):753–761.
12. Ebenezer V, Balakrishnan R. Immediate Vs Delayed Implants: comparative study of 100 cases. *Biomed Pharmacol J*. 2015;8:375–383.
13. Adell R, Lekholm U, Rockler B, Branemark PI. A 15 year study of osseointegrated implants in treatment of edentulous jaw. *Int J of Oral Surg*. 1981;10(6):387–416. Available from: [https://doi.org/10.1016/s0300-9785\(81\)80077-4](https://doi.org/10.1016/s0300-9785(81)80077-4).
14. Wagenburg BD, Ginsburg TR. Immediate implant placement on removal of the natural tooth: retrospective analysis of 1081 implants. *Compend Contin Educ Dent*. 2001;22(5):408.
15. Hahn J. Single-stage, immediate loading, and flapless surgery. *J Oral Implantology*. 2000;26(3):193–198. Available from: [https://doi.org/10.1563/1548-1336\(2000\)026%3C0193:silafs%3E2.3.co;2](https://doi.org/10.1563/1548-1336(2000)026%3C0193:silafs%3E2.3.co;2).

Copyright: © the author(s), 2020. It is an open-access article distributed under the terms of the Creative Commons Attribution License (CC BY 4.0), which permits authors to retain ownership of the copyright for their content, and allow anyone to download, reuse, reprint, modify, distribute and/or copy the content as long as the original authors and source are cited.

How to cite this article: Chakraborty S. Status of Immediate Versus Delayed Loading of Dental Implants in a Tertiary Care Teaching Hospital. *Asian J. Med. Res*. 2020;9(2):1-4.

DOI: [dx.doi.org/10.47009/ajmr.2020.9.2.DE1](https://doi.org/10.47009/ajmr.2020.9.2.DE1)

Source of Support: Nil, **Conflict of Interest:** None declared.