

Fifth toe Fillet Flap for Wound Coverage of Non-Healing Ulcer of the Foot: Surgical Technique and a Case Report

Sunny Chaudhary^{1D}, Shivakumar A Bali^{2D}, Arvind Singh^{3D}, R K Siddharth^{4D}

All India Institute of Medical Sciences, Department of Orthopaedics, Rishikesh, Uttarakhand, India.

Abstract

Fillet flap is one of the options in the treatment of diabetic non-healing ulcers. The advantages of the fillet flap include the absence of donor site morbidity, excellent durability and preventing the need for more proximal amputation. A 56-year-old farmer presented to the out-patient department with complaints of a non-healing ulcer on the sole of the right foot for the past 7 months which was managed conservatively. A fifth ray partial amputation and a rotational flap of the redundant fifth finger for wound coverage were done. The wound healing was uneventful and the sutures were removed after two weeks. At the latest follow-up of 2 years, the patient was able to walk independently without pain and without any functional limitations. This case report describes the surgical technique of the lateral lesser toe fillet flap for wound closure on the plantar aspect of foot as an alternative to secondary healing or more proximal amputations.

Keywords: Fillet Flap, Nonhealing ulcer, soft tissue coverage

Corresponding Author: Shivakumar A Bali, All India Institute of Medical Sciences, Department of Orthopaedics, Rishikesh, Uttarakhand, India. E-mail: ishivab@gmail.com

Received: 17 April 2020

Revised: 24 May 2020

Accepted: 1 June 2020

Published: 6 July 2020

Introduction

Fillet flaps are defined as axial flaps raised from amputated, discarded, or otherwise non-functioning or non-salvageable areas of the body. They are based on the 'spare part' concept, which is using concept is using parts of the amputated or otherwise non-salvageable parts of the traumatized limbs.^[1,2] Fillet flaps are of many types such as a pedicle, island, or microvascular free flaps for reconstruction and are commonly used in the mutilating injuries.^[3] Alpert and Buncke (1978) described the concept of fillet flaps, for treating mutilating hand injuries using a microvascular free flap from a non-replantable part for reconstruction.^[3] The conventional fillet flap described mainly for trauma has been extended to non-traumatic situations, such as defects caused by large pressure sores or for an extensive tumour resection, where they are raised from anatomically intact limbs.^[4-7] Fillet flap is one of the options in the treatment of diabetic non-healing ulcer and can be performed as single-stage operation or a multi-staged procedure. The clinical outcomes of fillet flap coverage for pressure wounds or selected amputations (forefoot and trans-metatarsal) in diabetic patients have been proven to be reliable.^[8-10] The purpose of this article was to describe wound coverage using skin flaps which would have otherwise been removed. The advantages of the fillet flap include the absence

of donor site morbidity, good durability and preventing the need for more proximal amputation for adequate soft tissue coverage.

Case Report

A 56-year-old farmer presented to the out-patient department with complaints of the non-healing ulcer on the sole of the right foot for the past 7 months. There was no history of diabetes, trauma, fever or constitutional symptoms. The patient was earlier managed by antiseptic dressing, without any significant improvement. On examination, the wound was located over the head of the fifth metatarsal and measured 1.5x1.5 cm in size. There was mild erythema with seropurulent discharge, present at the floor of the wound. Dorsalis pedis and posterior tibial pulses were palpable. Active toe movements were present. Ankle-brachial index (ABI) was within normal limits. Doppler ultrasonography revealed normal findings, without any signs of stenosis. Plain radiographs of the right foot were suggestive of chronic osteomyelitis of the 5th metatarsal head.

Initial debridement was done, and unhealthy tissue was removed. The wound was found to be communicating with the fifth metatarsal bone, and the metatarsophalangeal joint was also exposed. Pus samples were collected and sent for culture

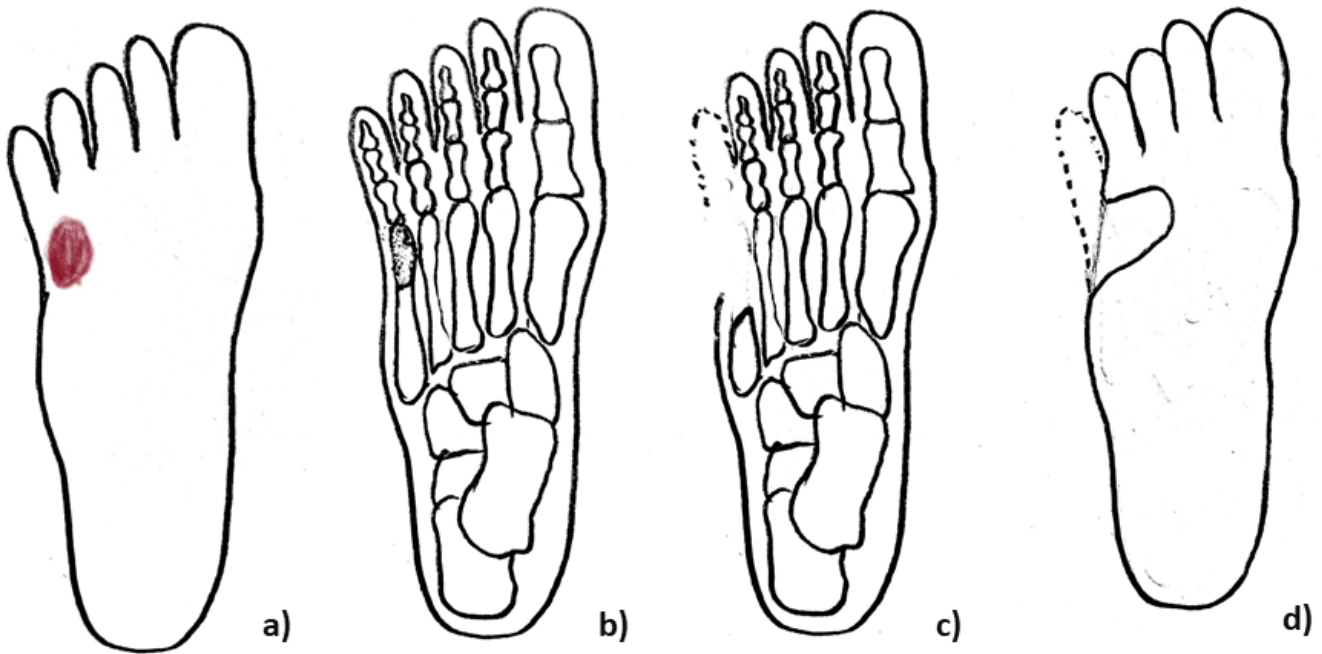


Figure 1: Fillet flap.

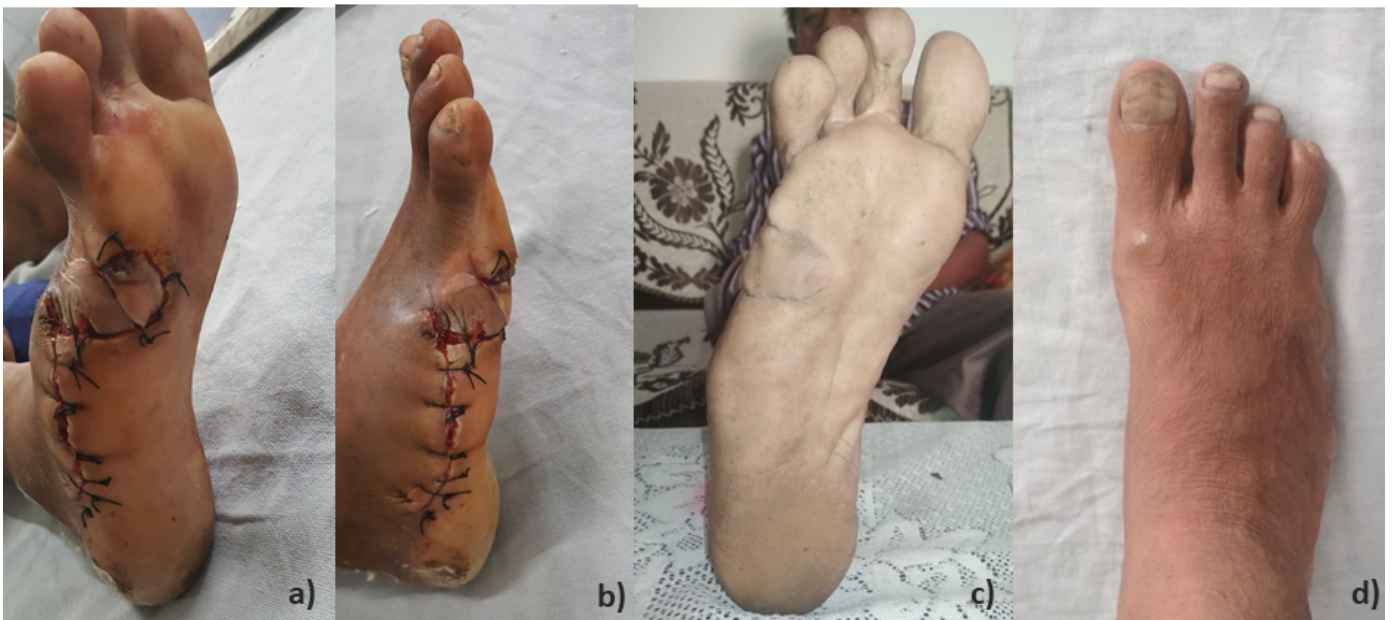

Figure 2: Fillet flap.

and sensitivity testing along with ziehl-neelsen staining and gram staining. The culture was positive for Methicillin sensitive Staphylococcus aureus (MSSA), sensitive to linezolid, clindamycin and doxycycline. Antibiotic therapy was started according to the culture reports. After 3 weeks of antibiotic therapy, mild improvement in local erythema was seen with a decreased amount of the discharge. A definitive surgical procedure to treat the chronic osteomyelitis of fifth metatarsal and the non-healing ulcer was planned. A fifth ray partial amputation and a rotational flap of the redundant fifth finger for wound coverage was desired.

Operative technique

Surgery was performed under spinal anesthesia and a tourniquet was used for hemostasis. A direct lateral incision was used to approach the fifth metatarsal, and it was extended distally up to the tip of the little finger. Full exposure of the fifth metatarsal, metatarsophalangeal joint and phalanges were done. Partial amputation of the fifth metatarsal was done, preserving the proximal part, which had the insertion of peroneus brevis tendon. The metatarsophalangeal joint, phalanges and tendons were filleted out while, preserving the neurovascular bundle. The nail was removed, and the flap of the little toe was spread in a manner as if, a cylinder was converted to a flat sheath. The margins of the wound on the plantar aspect were freshened, and it was made continuous with the incision. The filleted skin flap was rotated proximally and in plantar direction. The skin was closed using non-absorbable sutures. Surgery was followed by non-weight bearing for 2 weeks.

Postoperative antibiotics were continued for another week, and oral analgesics were prescribed for pain. The wound was examined on the third postoperative day, to rule out any signs of necrosis, dehiscence or infection. The wound healing was uneventful and the sutures were removed after two weeks. At the latest follow-up of 2 years, the patient was able to walk independently without pain and without any functional limitations.

Discussion

The 'spare part' concept, using tissues from amputated or otherwise discarded body parts to provide soft-tissue coverage for complex defects and avoid more proximal amputations, has gained popularity in recent years.^[1,2] Many microsurgical flaps are also available to cover any size and type of defect in this area, but they come at the cost of donor site morbidity and poor aesthetic appearance of both reconstructed area and the donor site.^[11] On the other hand, fillet flaps have an added advantage of decreased operative time, avoid donor site morbidity, provide sensate coverage. Even patients appreciate the absence of additional donor site morbidity and emphasis on the aesthetic considerations in their reconstruction. Fillets flaps are increasingly used to savage amputation stumps in lower leg amputations because they

help in length preservation which translates to the decreased energy expenditure of patients after rehabilitation.^[2] Pedicled plantar flaps provide excellent mechanical stability and almost normal sensibility to stump. They facilitate early weight-bearing, better proprioceptive feedback during gait training and reduction of prosthesis related complications such as ulcer, neuroma, and pain. This concept can also be extrapolated to other fields such as tumour reconstruction, where distal parts of an amputated limb, which are tumour free, can be used to reconstruct complex defects in the proximal part of the limb after tumour resection.^[12]

Conclusion

This case report describes the surgical technique of the lateral lesser toe fillet flap for wound closure on the plantar aspect of the foot. The advantages of this technique include good soft tissue durability and preventing the need for more proximal amputation for adequate soft tissue coverage. As this is a case report, more patients will be needed to further solidify the concept of lateral lesser toe fillet flaps, in terms of patient selection and clinical outcomes for soft tissue closure of the diabetic foot. Randomized controlled trials comparing patient selection criteria and different methods of flap coverage for partial ray amputations in diabetic patients are needed.

References

1. Qattan A, M M. Lengthening of finger fillet flap to cover dorsal wrist defects. *J Hand Surg (Am)*. 1997;22(3):550-1. Available from: [https://dx.doi.org/10.1016/S0363-5023\(97\)80028-7](https://dx.doi.org/10.1016/S0363-5023(97)80028-7).
2. Foster RJ, BARRY RJ, HOLLOWAY A, BURNEY DW. A 50-cm fillet flap for preservation of maximal lower extremity residual limb length. *Clin Orthop Relat Res*. 1983;178:216-219. Available from: <https://dx.doi.org/10.1097/00003086-198309000-00028>.
3. Alpert BS, Buncke HJ. Multilating multidigital injuries: use of a free microvascular flap from a nonreplantable part. *J Hand Surg Am*. 1978;3(2):196-198. Available from: [https://dx.doi.org/10.1016/s0363-5023\(78\)80074-4](https://dx.doi.org/10.1016/s0363-5023(78)80074-4).
4. Kuntscher MV, Erdmann D, Homann HH, Steinau HU, Levin SL, Germann G. The Concept of Fillet Flaps: Classification, Indications, and Analysis of Their Clinical Value. *Plast Reconstr Surg*. 2001;108(4):885-896. Available from: <https://dx.doi.org/10.1097/00006534-200109150-00011>.
5. Talbot SG, Mehrara BJ, Disa JJ, Wong AK, Pusic A, Cordeiro PG, et al. Soft-Tissue Coverage of the Hand following Sarcoma Resection. *Plast Reconstr Surg*. 2008;121(2):534-543. Available from: <https://dx.doi.org/10.1097/01.prs.0000297637.22846.a0>.
6. Ghali S, Harris PA, Khan U, Pearse M, Nanchahal J. Leg Length Preservation with Pedicled Fillet of Foot Flaps after Traumatic Amputations. *Plast Reconstr Surg*. 2005;115(2):498-505. Available from: <https://dx.doi.org/10.1097/01.prs.0000149482.96729.11>.

7. Shaw WW, Ko CY. Salvage of a Below-the-Knee Amputation with a Fillet of Foot Free Flap. *Ann Plast Surg.* 1996;37(4):433–438. Available from: <https://dx.doi.org/10.1097/00000637-199610000-00016>.
8. Aerden D, Vanmierlo B, Denecker N, Brasseur L, Keymeulen B. Primary closure with a filleted hallux flap after transmetatarsal amputation of the big toe for osteomyelitis in the diabetic foot: a short series of four cases. *Int J Low Extrem Wounds.* 2012;11:80–84. Available from: <https://dx.doi.org/10.1177/1534734612446640>.
9. Kalbermatten D, Kalbermatten N, Haug M, Schäfer D, Pierer G. Use of a combined pedicled toe fillet flap. *Scand Jf Plast Recons Surg Hand Surg.* 2004;38(5):301–305. Available from: <https://dx.doi.org/10.1080/02844310410027211>.
10. Lin CH, Wei FC, Chen HC. Filleted toe flap for chronic forefoot ulcer reconstruction. *Ann Plast Surg.* 2000;44:412–428. Available from: <https://dx.doi.org/10.1097/00000637-200044040-00010>.
11. Germann G, Bickert. Versatility and reliability of combined flaps of subscapular system. *Plast Reconstr Surg.* 1999;103:1386–1399. Available from: <https://dx.doi.org/10.1097/00006534-199904050-00007>.
12. van der Wey LP, Polder TW. Salvage of a through-knee amputation level using a free fillet of sole flap. *Microsurgery.* 1993;14(9):605–607. Available from: <https://dx.doi.org/10.1002/micr.1920140913>.

Copyright: © the author(s), 2020. It is an open-access article distributed under the terms of the Creative Commons Attribution License (CC BY 4.0), which permits authors to retain ownership of the copyright for their content, and allow anyone to download, reuse, reprint, modify, distribute and/or copy the content as long as the original authors and source are cited.

How to cite this article: Chaudhary S, Bali SA, Singh A, Siddharth RK. Fifth toe Fillet Flap for Wound Coverage of Non-Healing Ulcer of the Foot: Surgical Technique and a Case Report. *Asian J. Med. Res.* 2020;9(2):7-10.

DOI: dx.doi.org/10.47009/ajmr.2020.9.2.OR2

Source of Support: Nil, **Conflict of Interest:** None declared.

