

## Assessment of Blindness in Patients with Uveitis

Sanjeev Rohatgi<sup>1</sup>, Malini Vohra<sup>2</sup>, Preeti Chaubey<sup>3</sup>, Rajesh Ranjan<sup>4</sup>

<sup>1</sup>Professor, Department of Ophthalmology, Rama Medical College Hospital and Research Centre, Kanpur, <sup>2</sup>Assistant Professor, Rama Medical College, Kanpur, <sup>3</sup>Senior Resident, Rama Medical College, Kanpur, <sup>4</sup>Associate Professor, Dept. of Community Medicine, Saraswathi Institute of Medical Sciences, Pilkhuwa, Hapur, UP.

### Abstract

**Background:** Uveitis is an intraocular inflammation involving primarily the uveal tract. The present study was conducted to assess blindness in patients with uveitis. **Subjects and Methods:** The present study was conducted on 94 patients of uveitis of both genders. Detailed ocular examination was done by slit lamp biomicroscopy and direct/indirect ophthalmoscopy. In all patients, ocular symptoms, duration and recurrence were noted. Visual acuity was examined with the help of Snellen's test type and field of vision was recorded with Bjerrum screen. **Results:** Out of 94 patients, males were 52 and females were 42. Anterior uveitis was seen in 30, intermediate in 15, posterior in 22 and panuveitis in 27 cases. The difference was significant ( $P < 0.05$ ). There were 8 unilateral and 9 bilateral cases of visual loss in anterior type of uveitis followed by 10 unilateral and 7 bilateral in posterior uveitis. The difference was non-significant ( $P > 0.05$ ). **Conclusion:** Authors found that there were higher numbers of visual loss patients in anterior and posterior type of uveitis.

**Keywords:** Blindness, panuveitis, uveitis.

**Corresponding Author:** Dr. Rajesh Ranjan, Associate Professor, Dept. of Community Medicine, Saraswathi Institute of Medical Sciences, Pilkhuwa, Hapur, UP.

**Received:** November 2019

**Accepted:** November 2019

### Introduction

Uveitis is an intraocular inflammation involving primarily the uveal tract. Vision is one of our most cherished senses. There are nearly 45 million people worldwide who are blind and a further 135 million people are visually disabled. Uveitis causes 0.6% - 11% of blindness in various studies.<sup>[1]</sup> In contrast to common age-related eye disorders, uveitis may have a strong socioeconomic impact because it often affects younger working-age patients. Anterior uveitis is the most common intraocular inflammatory disease with a varying incidence across the globe. The potential and severe consequences of untreated or recurrent anterior uveitis are probably underestimated and under-reported. Anterior uveitis which can be categorized as iritis, anterior cyclitis and iridocyclitis, the last one is the most common type of all uveitic entities. Anterior uveitis often causes a painful red eye with mild to moderate vision loss, but its long-term sequelae contribute significantly to the total burden. The precise cause of anterior uveitis is often obscure, and the correct diagnosis is often challenging. The treatment for uveitis itself can result in both ocular and systemic complications. The morbidity associated with the disease is moderately high.<sup>[2]</sup>

It has been estimated that uveitis accounts for 10% to 15% of all cases of total blindness in the United States. Although uveitis is a well-known cause of blindness, there is only scant knowledge concerning the prevalence and incidence of uveitis among the blind. The complications like cataract and glaucoma, macular abnormalities are included in many epidemiological studies about blindness, how many of these

attributable to uveitis is not specified.<sup>[3]</sup> The present study was conducted to assess blindness in patients with uveitis.

### Subjects and Methods

The present study was conducted in the department of Ophthalmology. It comprised of 94 patients of uveitis of both genders. The study protocol was approved from institutional ethical committee. All subjects were informed regarding the study and written consent was obtained. Data such as name, age, gender etc. was recorded. Detailed ocular examination was done by slit lamp biomicroscopy and direct/indirect ophthalmoscopy. In all patients, ocular symptoms, duration and recurrence were noted. Visual acuity was examined with the help of Snellen's test type and field of vision was recorded with Bjerrum screen. Intraocular pressure was recorded in each eye separately by means of Schiottz indentation tonometer after anaesthetizing cornea with 4% lignocaine. P value less than 0.05 was considered significant.

### Results

**Table 1: Distribution of patients**

Total- 94		
Gender	Males	Females
Number	52	42

[Table 1 & Figure 1] shows that out of 94 patients, males were 52 and females were 42.

[Table 2 & Figure 2] shows that anterior uveitis was seen in 30, intermediate in 15, posterior in 22 and panuveitis in 27 cases. The difference was significant ( $P < 0.05$ ).

[Table 3, Figure 3] shows that there were 8 unilateral and 9 bilateral cases of visual loss in anterior type of uveitis followed by 10 unilateral and 7 bilateral in posterior uveitis. The difference was non-significant ( $P > 0.05$ ).

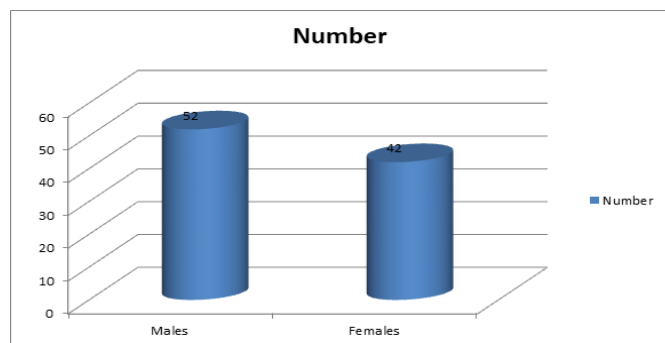


Figure 1: Distribution of patients

Table 2: Types of uveitis in patients

Types	Number	P value
Anterior	30	0.05
Intermediate	15	
Posterior	22	
Panuveitis	27	

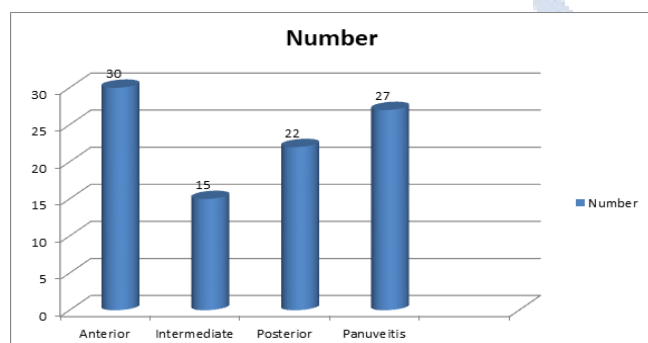


Figure 2: Types of uveitis in patients

Table 3: Visual loss in uveitis

Types	Unilateral	Bilateral	P value
Anterior	8	9	0.5
Intermediate	5	6	
Posterior	10	7	
Panuveitis	8	5	

## Discussion

Uveitis is a general term for inflammation of the uveal tract due to any cause and usually includes a large group of diverse diseases affecting not only the uvea but also the retina and vitreous. The exact cause of uveitis frequently remains unknown in most of the cases.<sup>[4]</sup> It is a potentially blinding disorder but there is only scant knowledge concerning the prevalence and incidence of uveitis among the blind. The conditions like cataract, glaucoma and macular abnormalities are included in many

epidemiological studies about blindness. How many of these are attributable to uveitis is not specified.<sup>[5]</sup> The present study was conducted to assess blindness in patients with uveitis.

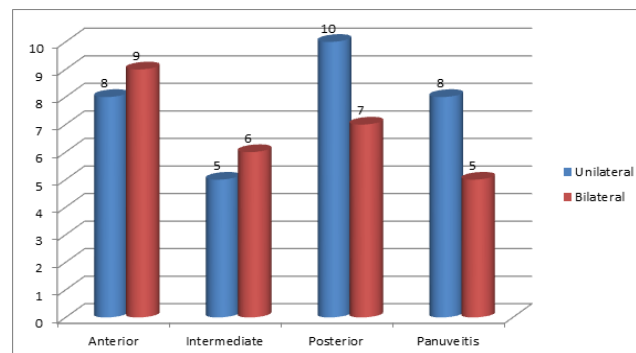


Figure 3: Anterior, Posterior, Intermediate and Panuveitis.

In this study, we found that out of 94 patients, males were 52 and females were 42. Ronday et al,<sup>[6]</sup> found that 50 cases of uveitis attending ophthalmic out patients were studied to find out clinical incidence of blindness. All the patients were subjected to detailed ocular examination including visual acuity, slit lamp biomicroscopy, direct/indirect ophthalmoscopy and intraocular pressure was recorded. Out of 50 patients examined, 20 cases (40%) developed blindness or visual impairment. Bilateral loss of vision developed in 5 cases (10%) and unilateral loss of vision occurred in 11 cases (22%).

We found that anterior uveitis was seen in 30, intermediate in 15, posterior in 22 and panuveitis in 27 cases. There were 8 unilateral and 9 bilateral cases of visual loss in anterior type of uveitis followed by 10 unilateral and 7 bilateral in posterior uveitis. De Boer J et al,<sup>[7]</sup> carried out a retrospective study of data of 123 consecutive patients with active uveitis and onset of ocular disease before the age of 16 years. Systemic disease was observed in 36 patients (29%) with juvenile idiopathic arthritis being the most frequent. Toxoplasma retinochoroiditis was diagnosed in 12 patients with posterior uveitis. Ocular complications were observed in 93 patients (76%) of which the most common was cataract (35%).

We observed that there were 8 unilateral and 9 bilateral cases of visual loss in anterior type of uveitis followed by 10 unilateral and 7 bilateral in posterior uveitis. James DG et al,<sup>[8]</sup> examined a series of 368 patients with endogenous uveitis. Of the 368 patients, 215 (58%) had anterior uveitis, posterior in 65 (18%) and generalized in 88 (24%). Ayanru Jo,<sup>[9]</sup> reviewed 1987 patients with uveitis. 56% of cases had posterior/mid peripheral uveitis, 15% panuveitis, 21.5% anterior uveitis.

Sudha et al,<sup>[10]</sup> in their study all patients between 20 and 80 years of age clinically presenting with anterior uveitis were studied. A thorough clinical evaluation followed by investigations was done to determine aetiology. Patients were put on specific and nonspecific treatment and were followed up for a period of 6 months. Complications were noted. The etiology of uveitis remained unknown in most

cases (42%). Most common cause was observed to be blunt trauma (20%) followed by phacolytic (12%). Most cases responded well to treatment. Commonest complication was posterior persistent synechiae (23.64%), and cataract was the second common (14.54%). Aetiological diagnosis remains undetermined in majority of cases. A thorough examination and investigation are required in each case to facilitate a final diagnosis.

## Conclusion

Authors found that there were higher numbers of visual loss patients in anterior and posterior type of uveitis.

## References

1. Khandekar R, Mohammed AJ, Negrel AD and Rigumi AA. The prevalence and causes of blindness in the Sultanate of Oman: The Oman Eye Study (OES). *British Journal of Ophthalmology*. 2003;86:957-962.
2. De Boer J, Nulffraat N and Rothova A. Visual loss in uveitis of childhood. *British Journal of Ophthalmology*. 2003;87:879-884.
3. Hajari A and Sangwan VS. Cataract surgery in uveitis. *Indian Journal of Ophthalmology*. 2002;50:103-107.
4. Herse P and Gothwal VK. Surgery of visual impairment in an Indian tertiary eye hospital. *Indian Journal of Ophthalmology*. 1997;45:189-193.
5. Tabe Tambi F. Causes of blindness in the western province of Cameroon. *Rev Int Trach Ocul Trop Subtrop Sante publique*. 1993;70:185-197.
6. Ronday MJH, Stilma JS, Baerbe RF, Mc Elroy WJ, Luyendijk J, Arend, Kolk HJ, Bakker M, Kijlstra A and Rothova A. Aetiology of uveitis in Sierra Leone, West Africa. *British Journal of Ophthalmology*. 1996;80:956-61.
7. De Boer J, Nulffraat N and Rothova A. Visual loss in uveitis of childhood. *British Journal of Ophthalmology*. 2003;87:879-884.
8. James DG, Friedmann, Aland Graham E. Uveitis. A series of 368 patients. *Trans Ophthalmol SOC UK*. 1976;96:108-112.
9. Ayanru Jo. The problem of uveitis in bendel state of Nigeria, experience in Benin city. *British Journal of Ophthalmology*. 1997;10:655-659.
10. Sudha Madhavi K M, Kumaraswamy R C. Study of clinical and aetiological pattern of anterior uveitis in middle Karnataka. *CHRISMED J Health Res* 2015;2:124-8.

**Copyright:** © the author(s), 2019. It is an open-access article distributed under the terms of the Creative Commons Attribution License (CC BY 4.0), which permits authors to retain ownership of the copyright for their content, and allow anyone to download, reuse, reprint, modify, distribute and/or copy the content as long as the original authors and source are cited.

**How to cite this article:** Rohatgi S, Vohra M, Chaubey P, Ranjan R. Assessment of Blindness in Patients with Uveitis. *Asian J. Med. Res.* 2019;8(4):OT04-OT06.

DOI: [dx.doi.org/10.21276/ajmr.2019.8.4.OT2](https://doi.org/10.21276/ajmr.2019.8.4.OT2)

**Source of Support:** Nil, **Conflict of Interest:** None declared.

