

# Study of Relative Position of the Mental Foramen in Different Age Groups: An Institutional Based Study

Deepak Sharma<sup>1</sup>, Chandrakala Agarwal<sup>2</sup>

<sup>1</sup>Ph.D Research Scholar, Department of Anatomy, SMS Medical College, Jaipur, Rajasthan, India, <sup>2</sup>Senior Professor & Head, Department of Anatomy, SMS Medical College, Jaipur, Rajasthan, India.

## Abstract

**Background:** Mental foramen is located on the anterolateral surface of the body of the mandible. Mental foramen is an important anatomical landmark. It is used for the anesthetists and dental surgeons during various oral and maxillofacial procedures/ surgeries. **Aim:** To study relative position of the Mandibular foramen in different age groups of adults. **Subjects and Methods:** In this study we have selected 800 patients. The present study was carried out on CBCT scans procured from the Dental Hospitals in Jaipur, Rajasthan. A detailed study of morphometric features of mental foramen along with other parameters of the mandible was carried out on the coronal, axial and sagittal views of CBCT scans using "CS 3D Imaging v3.5.7". Patients were divided in groups based on age. **Results:** The most common position of mental foramen in current study was found to be position 4 followed by position 3. No statistical difference was observed in or study in respect of position of MF association with different age group. **Conclusion:** A variation in mental foramen is very common and a good knowledge of anatomical landmark can help to prevent surgical injuries.

**Keywords:** Maxillofacial, Position, Landmark, Mental Foramen.

**Corresponding Author:** Dr. Chandrakala Agarwal, Senior Professor & Head, Department of Anatomy, SMS Medical College, Jaipur, Rajasthan, India.

**Received:** October 2019

**Accepted:** October 2019

## Introduction

The mental foramen (MF) is a very important landmark during dental and surgical procedures. It serves as an important landmark for administration of anesthesia. One should have a thorough knowledge in order to prevent injury during local anesthesia, root canal treatment and other oral and dental operative treatment procedures in this region.<sup>[1,2]</sup> Rowe AHR suggested that to anesthetize the anterior teeth, including the premolars and canines, it is possible to avoid giving inferior alveolar block, by injecting anesthetic solution adjacent to the mental foramen.<sup>[2]</sup>

Knowledge regarding position of MF is important both from diagnostic and clinical point of view. Authors have suggested that clinically, inaccurate information regarding the position of nerve and presence/absence of AL can lead to injury of mental bundle leading to post-surgical neurovascular complications.<sup>[3]</sup> according to the data available the most commonly, MF is located either below the apex of second premolar or between the apices of first and second premolar.<sup>[4,5]</sup> Dimensional imaging modalities like Cone Beam Computed Tomography and Denta Scan helps in locating mental foramen.

## AIM

To study relative position of the Mental foramen in different age groups.

## Subjects and Methods

In this study we have selected 800 patients. Ethical committee approval was obtained from the Institutional Ethics Committee. A written informed consent was obtained from the parents/guardian. The CBCT scans of subjects in the age groups of 18 years or more were included in the study, so that the minimum age of subjects was 18 years and the maximum age was 70 years. Of the 800 patients selected 422 were males and 378 were female subjects.

The CBCT scans of subjects with healthy permanent dentition and complete root formation were collected on a Compact Disc. Identity of the patients was concealed and only the age and gender were recorded. Each CD was given a unique identity number. The scans were viewed on the computer having the following configuration: 4 GB RAM with Pentium (R) Dual Core and Hp 19 inch LCD monitor with a screen resolution of 1600 X 900 and true colour of 32 bit. With multi-planar reformatting (MPR), the image is seen in various sections i.e. axial, sagittal and coronal planes.

A detailed study of morphometric features of mental foramen along with other parameters of the mandible was carried out on the coronal, axial and sagittal views of CBCT scans using "CS 3D Imaging v3.5.7". The values obtained for various measurements were arranged into three groups

according to the age of the subjects as follows;

**Group I:** 18 -30 years (132 males and 126 females)

**Group II:** 31 - 50 years (126 males and 126 females)

**Group III:** 51 - 70 years (164 males and 126 females)

**Exclusion Criteria**

CBCT images of subjects under 18 years of age were not included.

CBCT images of subjects showing presence of radiolucent/radiopaque lesion in the lower jaw were excluded from the study.

CBCT showing presence of periodontal lesions in lower jaw, presence of crowded/spacing of teeth in lower jaw and Observation of Missing teeth/ supernumerary teeth in the lower jaw other than the third molars were not included in the study.

Incomplete eruption of permanent teeth other than the third molar in the lower jaw was another exclusion criterion.

Non visualization of mental foramen bilaterally.

**Statistical Analysis**

The values obtained during each session will be assessed, tabulated and subjected to appropriate statistical analysis. The levels of significance tested were  $P < .05$  and  $P < .01$ .

**Results**

Present study aimed to Evaluate morphological and morphometric features of mental foramen using CBCT radiographs in different age group. A total of 800 patients were included in our study. Samples were divided in three different groups based on age. Group 1 consisted of 258 patients aged between 18 to 30 years of whom 132 were males and 126 females. Group 2 consisted of 252 patients aged between 31 to 50 years of which 126 were males and 126 were females. Group 3 consisted of 290 patients aged between 51 to 70 years of which 164 were males and 126 were females [Figure 1]. In our study of the 800 patients selected 422 were males i.e. % and 378 were females i.e. %.

In present study majority of the patients were males [Figure 2]. [Table 1] shows the position of MF in various age Groups. The most common position of MF was observed to be in line with 2nd premolar (Position 4) and was noted in 82.94

%, 77.5 % and 69.5 % of cases in Group I, II and III respectively. The next common position of MF was noted to be between first & second premolar (Position 3) with a frequency of 17.05 % in Group I; 17.8 % in Group II and 26.20 % in Group III. The least common position of MF in all the age Groups was either Position 2 or Position 5 [Table 2]. In the oldest population of the patients above 51 to 70 years old, a mental foramen was detected on both right and left side the most frequently in the line of second premolar, similar result as seen in the youngest individuals 18 to 30 years old a mental foramen was found on the right and left side mostly in line with the second premolar. No statistical difference was observed in or study in respect of position of MF association with different age group ( $p=0.426$ ).

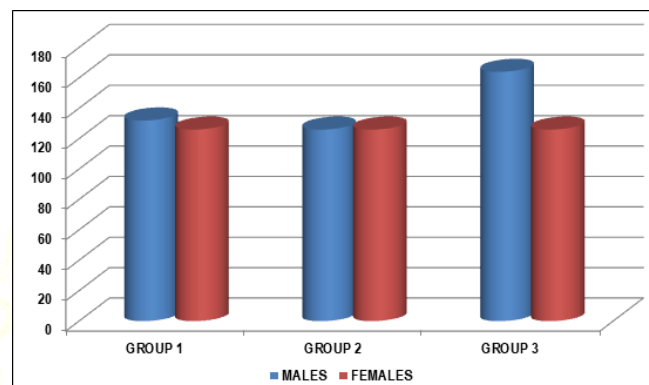


Figure 1: Distribution of Group

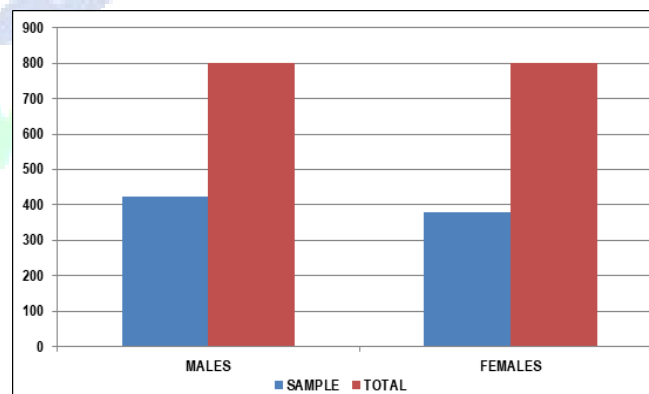


Figure 2: Sample Distribution Based On Gender

Table 1: Position of mental foramen observed in different age groups

Age Groups	Position of Mental foramen									
	1	2		3		4		5		6
		R (%)	L (%)	R (%)	L (%)	R (%)	L (%)	R (%)	L (%)	
Group-I (18-30 yrs) n=258	-	0 (0)	0 (0)	44(17.05)	44 (17.05)	214 (82.94)	214 (82.94)	-	-	-
Group-II (31-50 yrs) n=252	-	12 (5.1)	12 (5.1)	44 (17.8)	44 (17.8)	196 (77.5)	196 (77.5)	-	-	-
Group-III (51-70 yrs) n= 290	-	6 (2.4)	6 (2.4)	76 (26.20)	76 (26.20)	202 (69.6)	202 (69.5)	6 (2.4)	6 (2.4)	-

**Discussion**

The mental foramen (MF) is a bilateral small opening located on the anterolateral aspect of the mandible through which the mental nerve exits the mandible and is usually located either between the roots of the first and second

mandibular premolars or apical to the second premolar. Hu KS et al in 2007 suggested that the MF is an important anatomical landmark in the mandible for mental nerve identification, administration of local anesthesia, and various surgical procedures on the mandible in the field of dentistry.<sup>[6]</sup> According to researcher’s anatomical variations

in the position of MF are very rare however variations in the number of mental foramina have been reported with more than one MF present on one or both sides of mandible.<sup>[7]</sup>

In present study total of 800 patients were selected. Samples were divided in three different groups based on age. Group 1 consisted of 258 patients aged between 18 to 30 years of whom 132 were males and 126 females. Group 2 consisted of 252 patients aged between 31 to 50 years of which 126 were males and 126 were females. Group 3 consisted of 290 patients aged between 51 to 70 years of which 164 were males and 126 were females. Majority of the patients were aged between 51 to 70 years i.e. 36.25%. In our study 422 were males i.e. % and 378 were females i.e. %. In present study majority of the patients were males i.e. majority of the patients were males.

Based on the result of our study we found that the most common position of MF was observed to be in line with 2nd premolar (Position 4) and was noted in 82.94 %, 77.5 % and 69.5 % of cases in Group I, II and III respectively. The next common position of MF was noted to be between first & second premolar (Position 3) with a frequency of 17.05 % in Group I; 17.8 % in Group II and 26.20 % in Group III. The least common position of MF in all the age Groups was either Position 2 or Position 5 Wei Cheong et al. in their study reported that that the most common position in symmetric cases was position 4 (80.7%), followed by position 3 (n = 15, 13.9%) while in asymmetric cases, the highest frequency was at position 4 (51.1%), followed by position 3 (27.7%).<sup>3</sup> Whereas Jasser et al., found the position between the first and second premolars (46.2%) was more common than below the second premolar (35.4%) in the asymmetrical case.<sup>[4]</sup>

In current study the oldest population of the patients above 51 to 70 years old, a mental foramen was detected on both right and left side the most frequently in the line of second premolar, similar result as seen in the youngest individuals 18 to 30 years old a mental foramen was found on the right and left side mostly in line with the second premolar. No statistical difference was observed in or study in respect of

position of MF association with different age group (p=0.426). Medha Babset et al in their study reported that in all the age groups the mental foramen was located more towards the second premolar (Position 3C) in both right (66.27%) and left side (64.04%).<sup>[8]</sup>

## Conclusion

The most common position of mental foramen in current study was found to be position 4 and was noted in 82.94 %, 77.5 % and 69.5 % of cases in Group I, II and III respectively followed by position 3. The least common position of MF in all the age Groups was either Position 2 or Position 5. No statistical difference was observed in or study in respect of position of MF.

## References

1. Ahlgren FK, Johannessen AC, Hellem S. Displaced calcium hydroxide paste causing inferior alveolar nerve paraesthesia: report of a case. *Oral Surg Oral Med Oral Pathol Oral Radiol Endod*, 96: 734–37, 2003.
2. Rowe AH. Damage to the inferior dental nerve during or following endodontic treatment. *Br Dent J*, 153: 306–7, 1983.
3. Ngeow W.C., Yuzawati Y. The location of the mental foramen in a selected Malay population. *J. Oral Sci.* 2003;45(3):171–5.
4. Al Jasser N.M., Nwoku A.L. Radiographic study of the mental foramen in a selected Saudi population. *Dentomaxillo. Radiol.* 1998;27(6):341–3.
5. Fabian F.M. Position, shape and direction of opening of the mental foramen in dry mandibles of Tanzanian adult black males. *Ital. J. Anat. Embryol.* 2007;112(3):169–77.
6. Hu KS, Yun HS, Hur MS, Kwon HJ, Abe S, Kim HJ. Branching patterns and intraosseous course of the mental nerve. *J Oral Maxillofac Surg.* 2007;65:2288–94.
7. Sawyer DR, Kiely ML, Pyle MA. The frequency of accessory mental foramina in four ethnic groups. *Arch Oral Biol* 1998;43:417-20.
8. Medha Babshet, Sandeep R, Krishna Burde, and Kirty Nandimath, "Evaluation of the Position of Mental Foramen and Its Correlation with Age in Selected Indian Population, Using Digital Panoramic Radiograph." *International Journal of Dental Sciences and Research*, vol. 3, no. 4 (2015): 87-91. doi: 10.12691/ijdsr-3-4-2.

**Copyright:** © the author(s), 2019. It is an open-access article distributed under the terms of the Creative Commons Attribution License (CC BY 4.0), which permits authors to retain ownership of the copyright for their content, and allow anyone to download, reuse, reprint, modify, distribute and/or copy the content as long as the original authors and source are cited.

**How to cite this article:** Sharma D, Agarwal C. Study of Relative Position of the Mental Foramen in Different Age Groups: An Institutional Based Study. *Asian J. Med. Res.* 2019;8(4):AT06-AT08.  
DOI: dx.doi.org/10.21276/ajmr.2019.8.4.AT2

**Source of Support:** Nil, **Conflict of Interest:** None declared.