

# Paediatric Pelvic Tumours; Presentation, Diagnosis and Challenges of Treatment in a Low Resource Setting

Okoro Philemon E<sup>1</sup>, Eke Gracia<sup>2</sup>

<sup>1</sup>Paediatric surgery unit, Department of Surgery, University of Port Harcourt Teaching Hospital, Port Harcourt, Nigeria, <sup>2</sup>Paediatric Oncology Unit, Department of Paediatrics, University of Port Harcourt Teaching Hospital, Port Harcourt, Nigeria

## Abstract

**Background:** Paediatric pelvic solid tumours present peculiar challenge in clinical diagnosis due to their inherently obscure anatomic location, and the varied, often vague symptoms. Difficult surgical access and presence of important surrounding pelvic structures make their surgical treatment particularly challenging. **Aim:** To report our experience with paediatric pelvic solid tumours and to highlight the presentation pattern and challenges of diagnosis and treatment in our setting. **Subjects and Methods:** This is a five year retrospective study of pelvic solid tumours in children seen in our centre between December 2013 and November 2018. Data retrieved were demographics, presenting symptoms and duration, previous treatments, findings on examination, laboratory investigations, treatment given in our centre, histology of tumours and duration of follow up, outcome. Analysis was done on Microsoft Excel spread sheet Windows 2007. **Results:** Twenty three cases comprising 7 males and 16 females were included in this study. The age range was 1 to 14 years with a median at 6.5 years. Ten(43.5%) of these cases were benign, and 13(56.5%) were malignant. The teratomas comprised 9 benign cystic mature teratomas and 6 malignant teratomas. There were 4 mortalities and one recurrence. **Conclusion:** The anatomic location and vague early symptoms of pelvic tumours make early diagnosis difficult in our setting. High morbidity and mortality is the direct consequence. In a resource poor setting as ours, scrupulous physical examination including digital rectal examination is key to early diagnosis.

**Keywords:** Pelvic; Paediatric; Tumours; Presentation; Management; Outcome

**Corresponding Author:** Dr Philemon E Okoro. Paediatric Surgery Unit, Department of Surgery, University of Port Harcourt Teaching Hospital, Port Harcourt, Nigeria

**Received:** September 2019

**Accepted:** September 2019

## Introduction

Childhood neoplasia are a common cause of morbidity in children worldwide. Their contribution to the burden of childhood diseases has been well recognized in advanced countries. They are however, only receiving increasing attention in the past two decades in the developing countries as strides in the control of infectious diseases and increased awareness have made their prevalence more apparent.<sup>[1]</sup> There have been reports in our region of childhood solid tumours and malignancies generally highlighting the pattern of presentation and challenges posed by poverty and lack of sophisticated imaging and non-imaging equipment to diagnose and treat these tumours.<sup>[2,3]</sup> In our environment where many children do not have the benefit of detailed routine post natal and or preschool evaluation, solid tumours are only picked up if they are on the surface or have become sufficiently big to cause significant symptoms. Paediatric pelvic solid tumours present peculiar challenges in clinical diagnosis due to their inherently occult anatomic location, and the varied, often vague symptoms.<sup>[4,5]</sup> Difficult surgical access and presence of important surrounding pelvic structures are additional factors which make the surgical

treatment of this heterogenous clinical group of childhood tumours particularly challenging. Even with the most careful dissections in the surgical treatment of the pre-sacral tumours, various degrees of injury to the pelvic splanchnic plexus and other neurological tissues are common.<sup>[6]</sup> Consequently many manifest some difficulty with micturition, defaecation and or sexual function post operatively. It is in attempt to address the challenges of surgical access in pelvic tumours that Martucciello et al described a novel surgical approach- the posterior sagittal anorectal mobilization (PSAM) for some types of pelvic tumours.<sup>[7]</sup> This approach is however, not yet universally accepted by surgeons. Multidisciplinary approach of treatment has also been recommended by some authors for many of these pelvic tumours in order to achieve satisfactory results.<sup>[8]</sup> Despite many previous reports on childhood solid tumours in our region, reports on paediatric pelvic tumours as a group are still scanty.

### Aim

To report our experience with paediatric pelvic solid tumours and to highlight the presentation pattern and challenges of diagnosis and treatment in our setting.

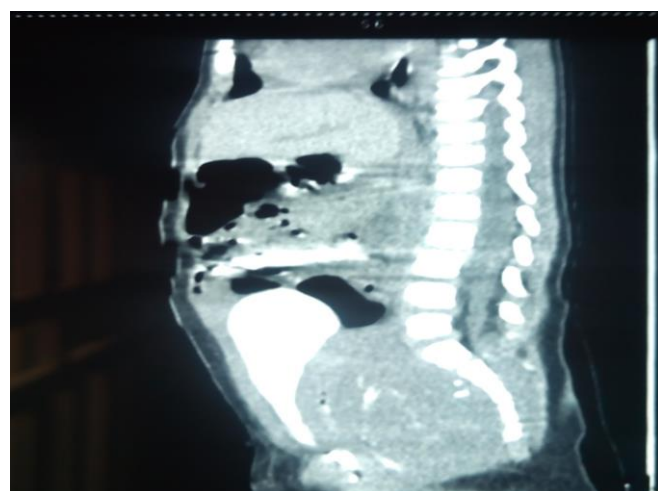
## Subjects and Methods

This study was conducted in our centre which is a tertiary health institution, and major referral centre serving Rivers State and the neighbouring states in the southern part of Nigeria. It is a five year retrospective review and descriptive analysis of cases of pelvic solid tumours in children seen in the paediatrics and surgery departments of our centre between December 2013 and November 2018. We defined paediatric pelvic tumours as solid neoplasms arising from structures or organs within the pelvis of patients 16 years and below. Patients were identified from nurses records in both departments, and data on each patient collected from the hospital notes. Data retrieved were demographics, presenting symptoms and duration, previous treatments, findings on examination, laboratory investigations, treatment given in our centre, histology of tumours and duration of follow up, outcome. Cases with incomplete records were excluded from the study. Data was subjected to simple statistical analysis using SPSS 21.

## Results

**Table 1: Presenting symptoms of patients with pelvic tumour**

Symptom	Patients (n=23)	Percentages
Lower abdominal pain	16	69.6
Pain on urination	12	52.2
Straining at defaecation	8	34.8
Straining at urination	7	30.4
Poor weight gain/ weight loss	7	30.4
Abdominal swelling	6	26.1
Perineal swelling	5	21.7
Intermittent constipation	4	17.4
Retching and vomiting	4	17.4
Urinary retention	3	13.0
Blood in urine	2	8.7



**Figure 1: Contrast enhanced CT scan showing a presacral tumour displacing the urinary bladder anteriorly and compressing it.**

**Table 2: Clinical examination findings at presentation**

Sign	Patients	Percentage
Palpable mass on bimanual or digital rectal examination	21	91.3
Palpable abdominal mass	9	56.5
Perineal swelling	6	26.0
Anterior displacement and stretching of anal verge	4	17.4
Oedematous labia majora	2	8.7
Protrusion from the urethra	1	4.3

**Table 3: Histologic types of pelvic tumours encountered**

Histologic types	Patients (n=23)	Percentage
Benign cystic mature teratoma(Ovarian + Sacrococcygeal)	9	39.1
Ovarian malignant teratoma	4	17.4
Presacral Dysgerminoma	3	13.0
Sacrococcygeal malignant teratoma	2	8.7
Bladder rhabdomyosarcoma	2	8.7
Ovarian yolk sac tumour	1	4.3
Presacral neuroblastoma	1	4.3
Ischiorectal fossa lipoma	1	4.3

A total of 26 cases of pelvic tumours were seen during the period under review. Three of these were excluded due to incomplete data. Twenty three cases comprising 7 males and 16 females had enough data to be included in this study. The age range was 1 to 14 years with a median at 6.5 years. The symptoms and signs that patients presented with are shown in [Table 1]. The duration of symptoms varied from 1 day to 9 months. The milder symptoms like intermittent constipation, mild pain at micturition, poor weight gain tended to be of longer duration while acute urinary retention, and acute abdominal pain tended to be of shorter duration. Twenty one of the patients had been seen by other clinicians and were treated for malaria, urinary tract infection, or helminthiasis before presentation to us. Only three of them had had a digital rectal examination performed on them before presentation to us. Relevant findings on clinical examination are shown in [Table 2]. Mass palpated on bimanual or digital rectal examination was the commonest finding, followed by palpable abdominal mass. The diagnostic imaging used were abdominopelvic ultrasound, plain x-ray and CT scan of pelvic region. Upper urinary dilatation was present in 7(30.4%) cases with derangement of renal function in 4(17.4%) of them. Anterior displacement and compression of the urinary bladder was a common finding in the cases of presacral tumours. [Figure 1]. There was evidence of distant metastasis in 2(8.7%) cases at presentation; one to the liver only, and the other to both the liver and right lung. Serum CA125 and platelet

count was done as part of diagnosis as well as follow up of 9 of the malignant cases. The access for pelvic exploration and excision of tumour was abdominal in 10(43.5%) patients, perineal in 8(34.8%) patients, and abdomenoperineal in 3(13.0%) patients. Two patients had unresectable tumours. The histology of the tumours are as shown in Table 3. Ten(43.5%) of these cases were benign, and 13(56.5%) were malignant. The teratomas comprised 9 benign cystic mature teratomas and 6 malignant teratomas. Chemotherapy was administered as adjuvant treatment in 11 cases, and the primary treatment in 2 cases. Patients were followed up for variable periods with a mean of 18 months (SD±5). There were 4 mortalities related to the effects of the pelvic tumour, and of complications of surgery. There was one recurrence.

## Discussion

Solid tumours occurring within the pelvis of children are heterogenous and are fairly common in our region. The peculiar anatomic location of these tumours coupled with the vague symptoms make the correct diagnosis less likely in the absence of high index of suspicion. Whereas digital rectal examination (DRE) is a very sensitive and useful aspect of examination of the child with pelvic tumour, many of the clinicians who saw the patients before us did not perform DRE ostensibly considering it undue discomfort, and probably unnecessary in the child whose symptoms were vague. This is the reason these tumours can be missed for long periods as in the case reported by Jones et al.<sup>[9]</sup> Whereas symptoms like mild dysuria (particularly in a female child) will lean towards urinary tract infection, some cases of straining at micturition may be missed until there is outright urinary retention. Also poor weight gain, excessive retching and vomiting which may be related to obstructive nephropathy can be misdiagnosed as being malaria or nutritional impairment in our region. Some of the cases in this series presented initially with features of renal function impairment and were later identified as cases of obstructive nephropathy secondary to pelvic tumour. Such remote consequence of pelvic tumour aside the effects of metastasis, are among the reasons diagnosis may be missed. An earlier study in our centre by Eke et al, though identified cases of obstructive uropathy, did not report any cases due to pelvic tumours.<sup>[10]</sup> This brings up the question as to whether it was a case of non recognition in that study or later increase in incidence of pelvic tumours which are now being picked up. Most of the cases in this series had been seen in a primary, secondary or tertiary health facility before presenting to us. These patients were mostly misdiagnosed before the pelvic tumour became apparent. It is notable that of all the findings on clinical examination of these patients, digital rectal examination (DRE) was the most sensitive in identifying the pelvic mass and leading ultimately to the proper diagnosis. It is possible that a DRE performed earlier by the referring clinicians would have made for earlier

diagnosis and proper treatment of these children. Swellings in the perineum and lower abdominal mass are obvious signs of pelvic tumours, but oedema of the labia alone could be a sign of pelvic tumour which may be missed by the unwary clinician. We encountered this in some patients who had presacral tumours, and we relate it to disturbances of lymphatic drainage due to pressure by the intrapelvic mass. The teratomas are by far the commonest pelvic tumours encountered in our series. Whereas the presacral sacrococcygeal teratomas tended to have longer duration of vague symptoms before diagnosis, the ovarian teratomas came with short history of intermittent acute lower abdominal pain mostly due to torsion of the ovarian tumour. Despite the short history of symptoms, the ovarian teratomas may have been on for longer periods than the sacrococcygeal teratomas (as distant metastasis was seen more with the malignant ones compared to the sacrococcygeal teratomas) but only being recognized when they underwent torsion. The combination of serum CA125 and platelet count did not seem to enhance diagnosis or follow up of our cases contrary to what has been suggested by another study.<sup>[11]</sup> The chemotherapy combination we used for the malignant teratomas was the Bleomycin, Actinomycin D and Cisplatin (BAP) regimen which had been shown to be effective but with less adverse drug reactions.<sup>[12]</sup> However the longterm effects in terms of gonadal function requires longer periods of follow up. The finding of benign cystic mature teratomas as the commonest type of pelvic teratoma in this study is in line with the findings by Vazquez et al.<sup>[13]</sup> In the two cases of bladder rhabdomyosarcoma, the entire urinary bladder was involved, and it protruded through the urethra in the female patient. Attempt at total cystectomy and urinary diversion in one case was met with complications which led to the patient's death. The second was planned for radiotherapy but died before treatment could be commenced. Rhabdomyosarcoma of the pelvic region is known to most commonly affect the urogenital tract as was the case in this study.<sup>[14]</sup> The outcome of surgical treatment is attended with both short and long term adverse outcomes. Studies in which male survivors of the surgical treatment of pelvic tumours were followed up showed that erectile function was remarkably affected in many cases.<sup>[15,16]</sup> CT scan is a most valuable tool in the evaluation of children with these tumours for diagnosis and follow up of treatment.<sup>[17]</sup> However, only a few of the patients in our series could afford the investigation either for diagnosis or for follow up. We therefore relied on findings on physical examination in those cases.

## Conclusion

Pelvic tumours are among the paediatric solid tumours encountered in our region. The peculiar anatomic location and often vague early symptoms and signs contribute to delay in diagnosis. Hence despite presentation to healthcare

facilities, delays in appropriate treatment or referral can occur due to a lack of attention to fine details. Presently, we see many of these cases late and surgical treatment is quite challenging in many cases. Whereas the outcome of treatment is good for the benign tumours, the malignant ones are still associated with poor outcome related to late diagnosis and the technical difficulties of late pelvic surgeries. Gentle digital rectal examination in children even when symptoms seem unrelated will facilitate the early pick up of these pelvic tumours even in the low resource setting where the more sophisticated diagnostic tools are not readily available.

## References

1. Tanko NM, Echejoh GO, Manasseh NA, Mandong MB, Uba AF. Paediatric solid tumours in Nigerian children: A changing pattern? *Afr J Paediatr Surg.* 2009;6(1):7-10.
2. Larry GH, Bankole RS, Yasser SE. Challenge of pediatric oncology in Africa. *Sem Pediatr Surg.* 2012;21(2):136-141.
3. Seleye-Fubara D, Akani NA. Solid Malignancies in Children and Adolescents: Experience at the University of Port Harcourt Teaching Hospital. *Nigerian Journal of Paediatrics.* 2004; 31(2): 43-47.
4. Shelmerdine SC, Lorenzo AJ, Gupta AA, Chavhan GB. Pearls and pitfalls in diagnosing pediatric urinary bladder masses. *Radiographics.* 2017 Oct;37(6):1872-1891. doi:10.1148/rg.2017170031.
5. Li Hsun c, Kui-Chen Y, Hsing-Ju W, Su-Boon Y. Yolk sac tumour in an eight year old girl: a case report and review of literature. *Front. Pediatr.* 30 Apr 2019. <https://doi.org/10.3389/fped.2019.00169>.
6. Mosiello G, Gatti C, De Gennaro M, Capitanucci ML, Silveri M, Inserra A et al. Neurovesical dysfunction in children after treating pelvic neoplasms. *Brit J Urol Int.* 2003; 92(3):185-335.
7. Martucciello G, Pio L, Avanzini S, Garaventa A. Complete posterior sagittal anorectal mobilization (PSAM): A new surgical approach for pediatric pelvic-perineal tumor resections. *J Surg Oncol.* 2018 Jun;117(8):1818-1822.
8. De Paula ME, Lopes RI, Padovani GP, Moscardi PR, Nishimura FG, de Mendonça BB, et al. Malignant paraganglioma in children treated with embolization prior to surgical excision. *World J Surg Oncol.* 2016;14(1):26.
9. Jones M, Khosa J. Presacral tumours: a rare case of a dermoid cyst in a paediatric patient. *BMJ Case Rep.* 2013 May 15;2013. pii: bcr2013008783. doi: 10.1136/bcr-2013-008783.
10. Eke FU, Eke NN. Renal disorders in children: a Nigerian study. *Pediatric Nephrology.* 1994; 8,(3): 383-386.
11. Watrowski R, Heinze G, Jäger C, Forster J, Zeillinger R. Usefulness of the preoperative platelet count in the diagnosis of adnexal tumors. *Tumour Biol.* 2016 Sep;37(9):12079-12087.
12. Sumi T, Ishiko O, Yoshida H, Ogita S. Bleomycin, actinomycin-D, and cisplatin treatment of ovarian germ-cell malignancies contributes to reducing adverse drug reactions. *Oncol Rep.* 2000;7(6):1235-8.
13. Vázquez RF, Murcia FJ, Siu U A, Ortega RM, Escassi GÁ, Garrido Pérez JI et al. Analysis of solid ovarian tumours in a Spanish paediatric population. *An Pediatr (Barc).* 2019 Apr 8. pii: S1695-4033(19)30079-7. doi:10.1016/j.anpedi.2019.02.002.
14. Kieran K, Shnorhavorian M. Current standards of care in bladder and prostate rhabdomyosarcoma. *Urol Oncol.* 2016;34(2):93-102.
15. Frees S, Rubenwolf P, Ziesel C, Faber J, Gutjahr P, Grossmann A et al. Erectile function after treatment for rhabdomyosarcoma of prostate and bladder. *J Pediatr Urol.* 2016;12(6):404.
16. Ritenour CW, Seidel KD, Leisenring W, Mertens AC, Wasilewski-Masker K, Shnorhavorian M, et al. Erectile dysfunction in male Survivors of childhood cancer-a report from the childhood cancer survivor study. *J Sex Med.* 2016;13(6):945-54.
17. Cremin BJ, Mervis B. Paediatric abdominal computed tomography: the technique and use in neuroblastomas and pelvic masses. *International Journal of Radiology and Radiation Oncology.* 2014 ; 56(665) <https://doi.org/10.1259/0007-1285-56-665-291>.

**Copyright:** © the author(s), 2019. It is an open-access article distributed under the terms of the Creative Commons Attribution License (CC BY 4.0), which permits authors to retain ownership of the copyright for their content, and allow anyone to download, reuse, reprint, modify, distribute and/or copy the content as long as the original authors and source are cited.

**How to cite this article:** Philemon EO, Gracia E. Paediatric Pelvic Tumours; Presentation, Diagnosis and Challenges of Treatment in a Low Resource Setting. *Asian J. Clin. Pediatr. Neonatol.* 2019;7(3):16-19. DOI: [dx.doi.org/10.21276/ajcpn.2019.7.3.5](https://doi.org/10.21276/ajcpn.2019.7.3.5)

**Source of Support:** Nil, **Conflict of Interest:** None declared.