

# Effects of Aqueous extract of Garlic (*Allium Sativa* L) on Alcohol-Duodenal ulcers of Adult Wistar Rats: a Histological Study

Daniel E. Odiase<sup>1</sup>, Michael O. Erhunmwunse<sup>2</sup>, Iboi E. Enaholo<sup>3</sup>

<sup>1</sup>Department of Anatomy, School of Basic Medical Sciences, University of Benin, Benin City, Edo State, Nigeria.

<sup>2</sup>Department of Human Anatomy, Faculty of Basic Medical Sciences, University of Port Harcourt, Port Harcourt, Nigeria.

<sup>3</sup>Department of Anatomy, School of Basic Medical Sciences, University of Benin, Benin City, Edo State, Nigeria.

**Date of Submission:** 06-01-2016

**Date of Acceptance:** 19-06-2016

**Date of Publishing:** 23-06-2016

## ABSTRACT

**Background:** Garlic (*Allium sativa* L) is a species in the onion family Alliaceae. The aim of the present study is to investigate the histological effects of aqueous extract of garlic on alcohol-induced duodenal ulcers of adult wistar rats. **Methods:** Adult wistar rats of both sexes (n=30) with weight between 150–250g were randomly selected into three treatment groups (B, C, D); a positive control (A), and a negative control (E) groups of five rats each. The treatment groups were fasted overnight before being induced with alcohol to cause duodenal toxicity, after which each group (B, C, D) respectively received daily administration of 200, 400 and 600 mg/kg of body weight of garlic extracts (GE) for 21 days through orogastric tube, with the confirmation of duodenal injury. The rats were subjected to light anesthesia (Chloroform) in a urethane-saturated chamber and sacrificed at the 22<sup>nd</sup> day of the experiment, and duodenums were carefully dissected and quickly fixed in 10% formal saline for histological study. **Results:** At the end of a 3 weeks treatment period, wide range of mucosal injury and ulcer was observed. However, when alcohol treated rats were given aqueous extract of garlic, the mucosal injury and ulcer was significantly reduced in all organs to nearly those of control rats. **Conclusion:** Garlic (*Allium sativa*) extract is able to inhibit the alcohol-induced duodenal toxicity.

**Keywords:** *Allium sativa* L, Alcohol, Duodenal toxicity, Garlic.

## INTRODUCTION

Peptic ulcer is an open crater or sore that develop in the inner lining (mucosa) of the stomach or the duodenum.<sup>[1]</sup> A coating of mucus and other chemicals normally shields the stomach and duodenum from digesting themselves.

### **Name & Address of Corresponding Author**

Dr. Daniel E. Odiase  
Department of Anatomy,  
School of Basic Medical Sciences, University of Benin, Benin  
City, Edo State, Nigeria.  
E mail: [odiase2002@yahoo.com](mailto:odiase2002@yahoo.com)

When these protective mechanisms are disrupted, powerful digestive acids can erode into the lining of

these organs and cause peptic ulcer.<sup>[2,3]</sup> A peptic ulcer may arise at various locations like Stomach (called gastric ulcer); Duodenum (called duodenal ulcer); and Esophagus (called esophageal ulcer).<sup>[1]</sup>

Over the centuries, alcohol has become the most socially-accepted addictive drug worldwid.<sup>[4]</sup> Excessive alcohol use is the third leading cause of preventable death in the United States.<sup>[5]</sup> Long-term (i.e., chronic) alcohol use affects almost every organ system of the body, potentially resulting in serious illnesses, including liver disease, impaired heart function (i.e., cardiomyopathy)<sup>[6]</sup>, inflammation of the pancreas (i.e., pancreatitis)<sup>[7]</sup> as well as inflammation on the duodenal mucosa (duodenal ulcer).

Accumulating evidence suggest that intermediates of oxygen reduction may be associated with the development of alcoholic disease.<sup>[8]</sup> Ethanol or its

metabolites can prompt a sharp increase of free radicals in the human body (e.g. hepatic cells or mucous cells)<sup>[9]</sup> by acting as a prooxidant or by reducing antioxidant levels and contributing to the progression of a variety of chronic diseases.<sup>[10]</sup>

Garlic (*Allium sativa* L) is a species in the onion family Alliaceae and has long been used around the world in cooking as well as in medicine. While garlic is a common flavoring in food, some scientists have suggested that it might have a role as a food additive to prevent food poisoning. There is some evidence that fresh garlic, but not aged garlic, can kill certain bacteria such as *Escherichia coli*, antibiotic-resistant *Staphylococcus aureus*, and *Salmonella enteritidis* in the laboratory.

Garlic has been used to treat an enlarged prostate (benign prostatic hyperplasia), diabetes, osteoarthritis, hay fever (allergic rhinitis) traveler's diarrhea, high blood pressure late in pregnancy (pre-eclampsia), cold and flu. It is also used for building the immune system, preventing tick bites, and treating bacterial infections. The complex chemistry of garlic makes it plausible that variations in processing can yield quite different preparations. Highly unstable thiosulfonates, such as allicin (2-propene-1-sulfinothioic acid S-2-propenyl ester), disappear during processing and are quickly transformed into a variety of organosulfur components.<sup>[7]</sup>

However, the effect of different extracts of fresh garlic on duodenal ulcers is not known. Thus, the current study was undertaken to investigate the effect of aqueous extracts of garlic on alcohol-induced duodenal ulcer of adult wistar rats.

## MATERIALS AND METHODS

**Collection and Harvest of Garlic:** The bulbs of garlic were bought from Uselu market, Edo State, Benin City, in July 2013, and were immediately taken to the department of Plant Biology and Biotechnology for identification. After identification, the extract was prepared at the department of Pharmacognosy, Faculty of Pharmacy, University of Benin.

**Test Animals:** Thirty (30) adult wistar rats of both sexes with weight ranging from 150g – 250g were used. The rats were obtained from the animal house section of the department of anatomy, faculty of basic medical sciences, University of Benin, Edo State – Nigeria; and were approved by the appropriate

authority of the University of Benin.

**Preparation of Plant Extract:** The fresh garlic was air dried and the fruity surface covering the bulb was removed. It was blended with an electric blender to a thick crude sample which was soaked with distilled water for 48 hours and filtered with cotton wool and funnel to separate the residues from the filtrate. The filtrate was concentrated with water bath, crushed to paste, and then preserve in a sample bottle for further use.

**Treatment of Animals:** The rats were randomly selected and distributed evenly into five groups A, B, C, D, and E of five rats each. Each group was kept in a separate cage. The rats were left to acclimatize to laboratory conditions for two weeks and subsequently employed to testing for three weeks; during which they were fed with commercially formulated rat feed (Growers' mash) and water was given ad libitum. The animals were exposed to natural room temperature and lighting conditions and handled according to standard protocols for the use of laboratory animals (National Institute of Health Guide for the Care and Use of Laboratory Animals).

**Experimental Design:** Adult wistar rats were fasted for 24 h prior to the experiment;

Group A: Positive control (Feed marsh and tap water) for 21 days

Group B: Treatment I lower dose (80% alcohol + 200 mg/Kg aqueous extract of garlic) for 21 days

Group C: Treatment II intermediate dose (80% alcohol + 400 mg/Kg aqueous extract of garlic) for 21 days

Group D: Treatment III high dose (80% alcohol + 600 mg/kg aqueous extract of garlic) for 21 days

Group E: Negative control (80% alcohol) for 21 days

### Histopathological Technique

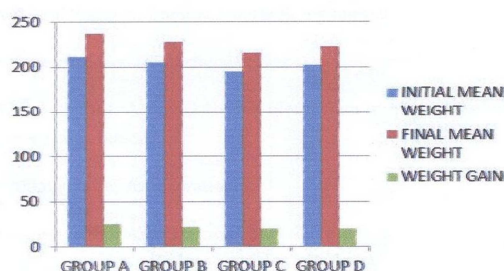
On 22<sup>nd</sup> day after administration of ulcerogen animals were sacrificed by light anesthesia (with the use of chloroform) in a urethane saturated chamber and duodenum were removed and opened; and duodenal lesions were observed using dissecting microscope. The duodenum was then fixed in 10% buffered formalin solution for histopathological studies, following standard procedures.<sup>[11]</sup>

## RESULTS

### Weight between groups of experimental animal

Weight losses were noticed in groups (those induced with alcohol). The experimental animal became restless and aggressive, and later gained weight during the course of the experiment.

BAR CHART ILLUSTRATING THE INITIAL AND FINAL MEAN WEIGHT VALUES BETWEEN THE GROUPS OF EXPERIMENTAL ANIMALS



### Gross evaluation of duodenal lesions

The gross appearance of rat duodenum treated with 80% alcohol to induce duodenal mucosal damage showed severe damage to the duodenal mucosa with elongated bands of haemorrhage in the negative control. The antiulcer activity of garlic extract in alcohol-induced duodenum showed that severe mucosal inflammation was observed from negative control rats, whereas, treated with 80% alcohol before administration of garlic extracts had significantly reduced areas of duodenal inflammation compared with negative control group.

### Antiulcer Studies

Administration of alcohol resulted in severe erosions in all the animals treated. However, daily administration of feed marsh and tap water for 21 days did not show any duodenal mucosa erosion when compared to negative control rats that received alcohol for 21 days. Administration of alcohol results in the formation of haemorrhagic erosions and leukocyte infiltration. While treatment of 80% alcohol and rats treated with garlic extract significantly reduced the formation of haemorrhagic erosions in comparison with positive control rats treated with alcohol. The results from the study showed that treated rat with aqueous extract of garlic for 21 days significantly reduced the formation of duodenal ulcer induced by alcohol compared to negative control.

### Histological evaluation of gastric erosion

Histological evaluation of alcohol-induced duodenal ulcer in the negative control group [Figure 2] showed extensive gastric inflammation and the presence of

leucocytes infiltration in the submucosal layer.




Figure 1: Positive Control (Group A): Rat duodenum showing normal mucosa lining A and lamina propria B: (H & E × 10)

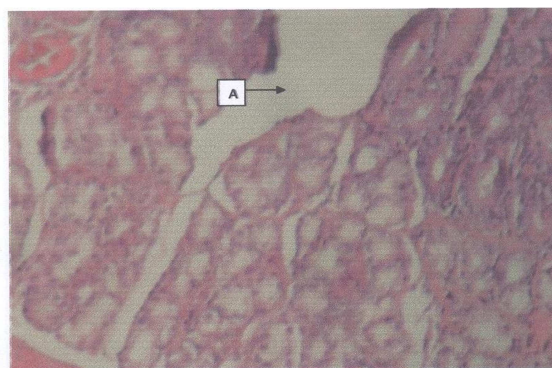


Figure 2: Negative control (Group E) rat duodenum treated with alcohol and sacrificed after 3 weeks showing a funnel shaped duodenal mucosa ulcer A, with haemorrhagic erosions (H & E × 10)

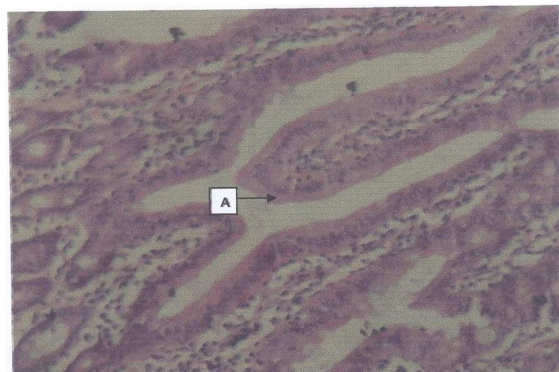
However, the ulcerated area revealed that there was a significant increase in regenerated glandular epithelium [Figure 3, 4 & 5] after treatment with aqueous extract of garlic when compared with the negative control. The mucosa growth in the ulcerated tissue was significantly increased by all three doses of garlic extract showing the maximum effect with increase dose [Figure 5].

This experimental finding was similar to previous reports, which showed that alcohol intoxication caused extensive and acute haemorrhagic lesions on the mucosal surface of the gastric tissue and damaged gastric layers.<sup>[12,13]</sup>

## DISCUSSION

The present study was evaluated to see if the aqueous extract of garlic could show antiulcer effect on

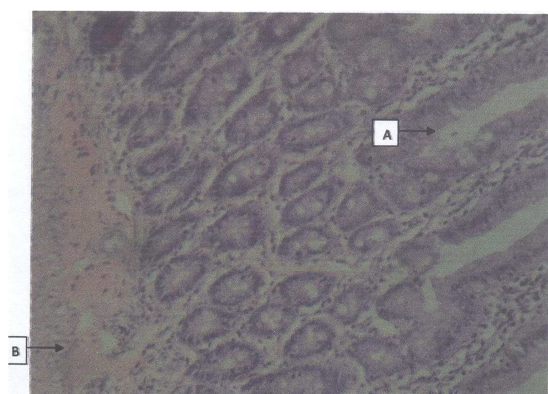duodenal ulcer. The extract showed antiulcer effects to alcohol-induced duodenal ulcer with increasing dose of extract. This, therefore, suggests that aqueous extract of garlic may have cytoprotective effects on duodenal mucosa



**Figure 3:** Group B (treatment I) rat duodenum treated with alcohol and 200 mg/kg body weight of garlic extract showing unremarkable mucosa growth A (H & E  $\times$  10)



**Figure 4:** Group C rat duodenum treated with alcohol and 400 mg/kg garlic extract showing unremarkably mucosa growth A (H & E  $\times$  10)



**Figure 5:** Group C rat duodenum treated with alcohol and 400 mg/kg garlic extract showing unremarkably mucosa growth A (H & E  $\times$  10)

The cytoprotective effect of aqueous extract of garlic was confirmed by histological evaluation showing prevention of duodenal mucosal damage, haemorrhagic erosion and submucosal edema. This corroborates the work done by Imuro et al<sup>[14]</sup>, that the numbers of hemorrhagic spots in the glandular stomach and the microscopic score for gastritis were significantly reduced by garlic extract treatment.

An increase in the acid secretion, a decrease in the gastric mucosal protection and an induction of oxidative stress in gastric mucosa are the important factors that are implicated in the pathogenesis of peptic ulcers. The present study therefore demonstrated that treatment of rats with garlic extract significantly ameliorates the rat duodenal mucosa against hemorrhagic lesion induced by 80% alcohol, increases the duodenal mucosal protection and reduces oxidative stress in the duodenal mucosa as compared to negative control rats. Garlic extracts showed replenishing effects against alcohol-induced ulcer genesis in rats, which may be observed to be a cytoprotective activity.

Based on our results and scientific literature, the potential of garlic extracts could also be considered for the treatment of chronic subacute injury at the duodenum.<sup>[15]</sup> In that sense, contemporary medications used in the treatment of gastric ulcers and other gastric-related pathologies involve the use of novel mucosal protective drugs. Several of these drugs based their action on antioxidative effects.<sup>[15]</sup>

The results here demonstrated that garlic extracts show an important antiulcer activity against alcohol-induced duodenal damage, probably related to their variety of pharmacologic activities, such as lowering of cholesterol, inhibition of platelet aggregation, immune enhancement and antioxidant activity and their oxidant properties as seen in fresh garlic; which leads to a decrease in the level of oxidation product, malondialdehyde (MDA) in the blood samples, thus demonstrates reduced oxidation reactions in the body.<sup>[16]</sup> All these garlic extract properties help protect duodenal mucosa from oxidative damage and to replenish any duodenal mucosa that has been damaged or eroded. These results further suggest that aqueous extract of garlic could be an effective component of preventing ulcer formation induced by alcohol.

## CONCLUSION

The antiulcer effects of aqueous extract of garlic seem to have several important properties that make it useful in amelioration for antiulcer, especially duodenal ulcer. However, further investigations are required to discover their exact mechanism of action in terms of antiulcer activity.

## REFERENCES

- Pavan KP, Jagatheesh K, Kowsalya R, Babu CM, Namasivayam E. Protective effects of *Chenopodium album* ethanolic extract against aspirin induced peptic ulcer in rat model. *Int Jour Phytopharmacol.* 2013; 4(2):99-105.
- Anonymous I. [www.pepticulcermerckmanual.html](http://www.pepticulcermerckmanual.html)
- Tripathi KD. *Essentials of Medical Pharmacology.* 5th ed. Jaypee Brothers Medical Publishers Pvt. Ltd; 2003.
- Guo R., Ren, J. Alcohol and acetaldehyde in public health: From marvel to menace. *Int. J. Environ. Res. Public Health,* 2010;7: 1285-1301.
- Mokdad AH, Marks JS, Stroup DF, Gerberding JL. Actual causes of death in the United States. *JAMA* 2000; 291: 1238-1245.
- Barnes DE, Walker DW. Prenatal ethanol exposure permanently reduces the number of pyramidal neurons in rat hippocampus. *Brain Res.* 1981;1:333-340.
- Manzo-Avalos S, Saavedra-Molina A. Cellular and Mitochondrial Effects of Alcohol Consumption. *Int. J. Environ. Res. Public Health.* 2010; 7: 4281-4304.
- Calabrese V, Scapagnini G, Latteri S, Colombrita C, Ravagna A, Catalano C, et al. Long term ethanol administration enhances age-dependent modulation of redox state in different brain regions in the rat: Protection by acetyl carnitine. *Int J Tissue React.* 2002; 24(3):97-103.
- Seif HSA. Ameliorative effect of pumpkin oil (*Cucurbita pepo*L.) against alcohol-induced hepatotoxicity and oxidative stress in albino rats *beni-suef.* *Univ Jour Bas App Sci.* 2014; 3: 178-185.
- Clemens DL, Jerrells TR. Ethanol consumption potentiates viral pancreatitis and may inhibit pancreas regeneration: preliminary findings. *Alcohol.* 2004; 33:183-9.
- Kulkarni SK. *Hand book of Experimental Pharmacology,* 3rd revised and enlarged ed. 2010: 149.
- Al Rashdi AS, Salama SM, Alkiyumi SS, Abdulla MA, Hadi AHA, Abdelwahab SI et al. Mechanisms of gastroprotective effects of ethanolic leaf extract of *Jasminum. sambac* against HCl/Ethanol-Induced gastric mucosal injury in rats. *Evid. Based Complement. Alternat. Med.* 2012; 78426.
- Huang CC, Chen YM, Wang DC, Chiu CC, Lin WT, Huang CY et al. Cytoprotective Effect of American Ginseng in a Rat Ethanol Gastric Ulcer Model. *Molecules.* 2014;19: 316-326.
- Iimuro M, Shibata H, Kawamori T, Matsumoto T, Arakawa T, Sugimura T, Wakabayashi K. Suppressive effects of garlic extract on *Helicobacter pylori*-induced gastritis in Mongolian gerbils. *Cancer Lett.* 2002;187(1-2): 61 – 8.
- José M. Alvarez-Suarez, Dragana Dekanski, Slavica Ristić, Nevena V. Radonjić, Nataša D. Petronijević, Francesca Giampieri, Paola Astolfi, Ana M. González-Paramás, Celestino Santos-Buelga, Sara Tulipan. Strawberry Polyphenols Attenuate Ethanol-Induced Gastric Lesions in Rats by Activation of Antioxidant Enzymes and Attenuation of MDA Increase. 2011.
- Durak I, Kavutcu M, Aytac B, Avci A, Devrim E, Ozbek H, Oztürk HS. Effects of garlic extract consumption on blood lipid and oxidant/antioxidant parameters in humans with high blood cholesterol; *J Nutr Biochem.* 2004; 15(6):373-7.

**Copyright:** Academia Anatomica International is an Official Publication of “Society for Health Care & Research Development”. This is an open-access article distributed under the terms of the Creative Commons Attribution Non-Commercial License, which permits unrestricted non-commercial use, distribution, and reproduction in any medium, provided the original work is properly cited.

**How to cite this article:** Odiase DE, Erhunmwunse MO, Enaholo IE. Effects of Aqueous extract of Garlic (*Allium Sativa* L) on Alcohol-Duodenal ulcers of Adult Wistar Rats: a Histological Study. *Acad. Anat. Int.* 2016;2(1):3-7.

**Source of Support:** Nil, **Conflict of Interest:** None declared.