

Study on the Incidence of the Occurrence of the Sutural Bones at Asterion in the Dry Adult Human Skulls of the South Indian Population

Indupuru Gowri¹, B H Shiny Vinila²

¹Associate Professor, Department of Anatomy, Dr. Patnam Mahender Reddy Institute of Medical Sciences, Chevella, Rangareddy, Telangana, India, ²Senior Lecturer, Department of Anatomy, Panineeya Mahavidyalaya Institute of Dental Sciences, Hyderabad, Telangana, India.

Abstract

Background: Asterion is the point of sutural confluence present on the norma lateralis of the skull. Occasionally sutural bones are present at asterion. Asterion is commonly used as a surgical landmark for the lateral approach of the cranial fossa. So, the knowledge on the incidence of the presence of sutural bones at the asterion is important for surgeons. Thus the present study was undertaken to find out the incidence of the occurrence of the sutural bones present at the asterion. **Subjects and Methods:** 70 skulls were collected from the department osteology section. The damaged bones were excluded from the study. A total of 140 asterions were studied. All the skulls were observed and the incidence of type 1 and type 2 asterion was recorded on both sides. The incidence of the multiple sutural bones was also recorded on both the right and left sides. **Results:** The incidence of type 2 asterion was observed to be higher than the type 1 asterion. The incidence of type 1 and type 2 sutural bones was observed as 27.86% and 72.14% respectively. The incidence of the multiple sutural bones at the asterion was observed as 14.29%. **Conclusion:** The data on the incidence of occurrence of sutural bones which was presented in the present study may be of great use to the radiologists and neurosurgeons for a better diagnosis and to minimize the complications while performing lateral approaches of the cranial fossa.

Keywords: Asterion, Sutural bone, Skull.

Corresponding Author: Indupuru Gowri, Associate Professor, Department of Anatomy, Dr. Patnam Mahender Reddy Institute of Medical Sciences, Chevella, Rangareddy, Telangana, India.

E-mail: gowri.indupuru@gmail.com

Received: 08 May 2021

Revised: 09 July 2021

Accepted: 20 July 2021

Published: 05 December 2021

Introduction

Asterion is the meeting point of parietal, temporal, and occipital bones where the confluence of the lambdoid, the parietomastoid and the occipitomastoid sutures occur. The presence of sutural bones at this point was reported and the incidence of occurrence of the sutural bones varies among the different ethnic populations. The main cause of the formation of sutural bones in the asterion is unclear. Literature suggests that it may be due to the additional ossification centres occur near the sutures, or maybe due to the pathological causes related to hydrocephalus. Some authors believe that the formation of sutural bones in asterion develops as the normal process with the influence of genes.^[1] The asterion is used as a surgical landmark for the lateral approach to the posterior cranial fossa for various surgical procedures such as transmastoid approach, retrosigmoid approach for the treatment of trigeminal neuralgia to decompress the trigeminal nerve root or to remove the neuromas.^[2,3]

Sutural bones are the accessory bones that are present within the cranial sutures. Numerous sutural bones are commonly found in the lambdoid suture and fontanelles but are rarely observed in other sutures.^[4,5] As the sutural bones are commonly observed at the fontanelles, the asterion is a site of closure of the posterolateral or mastoid fontanelles. Based on the presence or absence of the sutural bones the asterion was morphologically classified into two types. The presence of the sutural bones at asterion is type 1 and the absence of the sutural bones at asterion is type 2.^[6]

The presence of the sutural bones at asterion may cause difficulties in the surgical approaches and lead to complications. The presence of the sutural bones may also mislead the radiologists and neurosurgeons in the diagnosis of fractures in case of head injuries. The knowledge of the variations in the asterion is important for radiologists and neurosurgeons which may be of great importance while dealing with the lateral approach of the posterior cranial fossa or head injuries.^[1] Thus the present study was aimed to find out the incidence of occurrence of the sutural bones at the asterion.

Subjects and Methods

The study was conducted on 70 adult dry human skulls of unknown sex in which 140 asterions were studied (70 right and 70 left). The skulls damaged at the asterion region were excluded from the study, only intact bones were included. All the skulls were examined and the types of the asterion were noted based on the sutural bones. The skulls with the presence of sutural bones at the asterion were considered as type 1 asterion and the skulls without any sutural bones at the asterion were considered as the type 2 asterion. The incidence of type 1 and type 2 asterions and the occurrence on the right and the left sides were recorded. The incidence of the presence of multiple sutural bones was also recorded on both the right and left sides.

Results

The presence of the sutural bones (type 1) was observed in 39 sides out of 140 sides and the incidence was observed as 27.86% (39 out of 140 asterions). The incidence of sutural bones on the right side was observed as 24.28% (17 out of 70 asterions) and 31.43% (22 out of 70 asterions) on the right and left sides respectively. The incidence was a little higher on the left side when compared to the right side. Type 1 asterion was observed bilaterally in 10% (7 out of 70 asterions) of skulls. Multiple sutural bones were observed in 7.14% (10 out of 140 asterions) of the skulls and the side-wise incidence was observed as 5.71% (4 out of 70 asterions) on its right side and 8.57% (6 out of 70 asterions) on the left side. The incidence of the multiple sutural bones was also higher on the left side when compared with the right side. The type 2 asterion was observed as the predominant type and the incidence was observed as 72.14% (101 out of 140 asterions) and the sidewise incidence was 75.71% (53 out of 70 asterions) and 68.57% (48 out of 70 asterions) on the right and left sides respectively.

Discussion

The asterion, mastoid process, suprameatal crest, and the external occipital protuberance are the common points that serve as bony landmarks to analyze the posterolateral surface of the skull and are also important for neurosurgeons and radiologists in the diagnosis and treatment. The posterior cranial fossa has a dense collection of neurovascular structures which are closely packed in a small area and cause difficulties in various surgical approaches which may also lead to medical errors in surgery.^[7-9] Thus the present study was undertaken to find out the incidence of the presence of the sutural bones was observed as 27.86%. The incidence of type 1 and type 2 asterions. The incidence of the presence of the sutural bones was observed as 27.86%. The incidence of type 1 and type 2 asterions as it is used as a surgical landmark for various surgical approaches in neurosurgery.

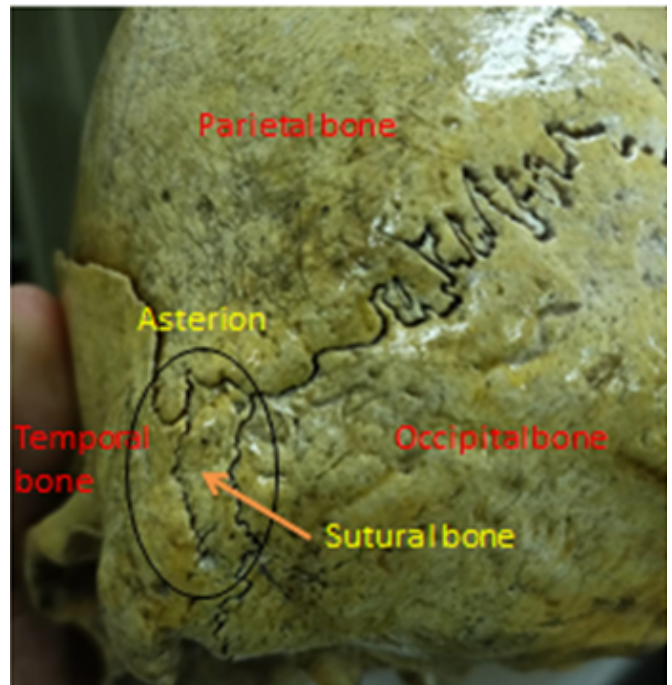


Figure 1: Showing the type 1 Asterion

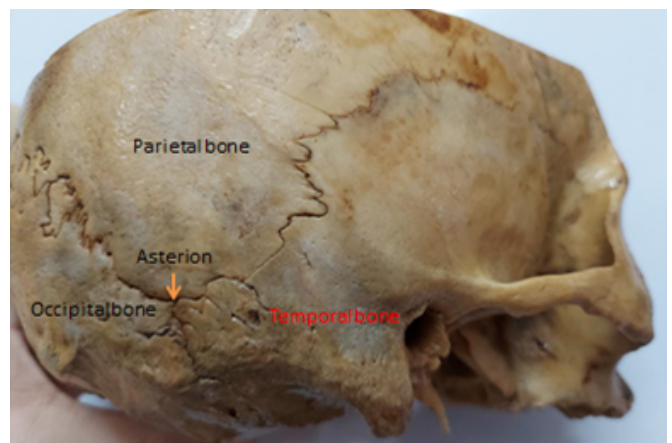


Figure 2: Showing the type 2 Asterion

There are different theories to explain the formation of sutural bones, according to Gray's anatomy it was due to the appearance of additional ossification centres near the sutures. Hess and Finkel explained it as the result of pathological factors such as hydrocephalus. Another study by Opperman et al., explained an association between the dura mater and skull bones and found dura mater plays a role in the formation of sutural bones.^[10-13] Literature suggests that there is a genetic factor responsible for the formation of the sutural bones. The




Figure 3: Showing the Asterion with multiple sutural bones.

MSX gene expression plays a task in the development of bones of the cranial cavity by influencing the differentiation and therefore the proliferation of the osteogenic cells. MSX genes are also needed to suppress osteogenic programs. Thus, the inhibition of the repressive activity of MSX gene may lead to the formation of sutural bones.^[14]

In the present study, the incidence of type 2 (absence of sutural bones at asterion) is a predominant type with an incidence of 72.14%. The incidence of the presence of the sutural bones was observed as 27.8%. The incidence of type 1 and type 2 asterions of the present study was compared with the other studies. In the Brazilian population, the incidence of type 1 was observed as 31.67% and type 2 was 68.3%. According to their observations, type 1 was more common in males and on the left side whereas type 2 was common in females and on the right side.^[15] These results coincide with the results of the present study where type 1 was more common on the left side and type 2 in the right side, but the overall incidence is higher than the present study.

Mwachaka et al., observed the presence of sutural bones at asterion (Type 1) in 20% and absence of sutural bone in 80% of the Kenyan population. Leon et al., observed the sutural bones at asterion in 25.6% and the absence of sutural bones in 74.4% in the Mexican population.^[16] Hussain et al., observed the presence of the sutural bones in 23.15% of the Indian population.^[17] In these studies type 2 was the most common and the incidence of occurrence of the sutural bones was nearer to the present study where the incidence of type 1 was observed as 27.8%. The incidence of the multiple sutural bones was not

mentioned in these studies and the present study reported the incidence of the multiple sutural bones at asterion 7.14%. The presence of multiple sutural bones may, even more, increase the risk to the surgeons while performing the lateral skull approaches.

Conclusion

The presence of sutural bones may confuse radiologists as the sutural bones can be misinterpreted as fractures. The results of the present study may help the surgeons while performing the burr hole surgeries of lateral cranial base as the asterion is used as a surgical landmark. The knowledge on the incidence of single or multiple sutural bones may help the surgeons while planning the surgeries to avoid complications.

References

1. Singh R. Incidence of sutural bones at asterion in adults Indians skulls. *Int J Morphol*. 2012;30(3):1182–1186.
2. Landeiro JA, Castro ID, Flores MS, Orlando OT, Junior M. Posterior fossa craniotomy technical report. *Arq Neuropsiquiatr*. 2000;58(1):169–173. Available from: <https://doi.org/10.1590/s0004-282x2000000100026>.
3. Figen GH. Asterion as a surgical landmark for lateral cranial base approaches. *J Craniomaxillofac Surg*. 2006;34(7):415–420. Available from: <https://doi.org/10.1016/j.jcms.2006.05.003>.
4. Rao TR, Rao S. Anatomical Variation of Asterion in Human Dry Skull - A Case Report. *Case Stud J*. 2016;5(5):41–44.
5. Khan AA, Asari MA, Hassan A. Unusual presence of Wormian (sutural) bones in human skulls. *Folia Morphol (Warsz)*. 2011;70(4):291–294.
6. Mwachaka PM, Hassanali J, Odula P. Sutural morphology of the pterion and asterion among adult Kenyans. *Braz. J Morphol Sci*. 2009;26(1):4–7.
7. Bozbuga M, Boran BO, Sahinoglu K. Surface anatomy of the posterolateral cranium regarding the localization of the initial burrhole for a retrosigmoid approach. *Neurosurg Rev*. 2006;29(1):61–63. Available from: <https://doi.org/10.1007/s10143-005-0417-2>.
8. Mwachaka PM, Hassanali J, Odula PO. Anatomic position of the asterion in Kenyans for posterolateral surgical approaches to cranial cavity. *Clin Anat*. 2010;23(1):30–33. Available from: <https://doi.org/10.1002/ca.20888>.
9. Tubbs RS, Elton S, Grabb P, Dockery SE, Bartolucci A, Oakes WJ. Analysis of the posterior fossa in children with the Chiari 0 malformation. *Neurosurgery*. 2001;48(5):1050–1055. Available from: <https://doi.org/10.1097/00006123-200105000-00016>.
10. Jin SW, Sim KB, Kim SD. Development and Growth of the Normal Cranial Vault : An Embryologic Review. *J Korean Neurosurg Soc*. 2016;59(3):192–196. Available from: <https://dx.doi.org/10.3340/jkns.2016.59.3.192>.
11. Oliveira LM, Nitrini R, Román GC. Normal-pressure hydrocephalus: A critical review. *Dement Neuropsychol*.

- 2019;13(2):133–143. Available from: <https://dx.doi.org/10.1590/1980-57642018dn13-020001>.
12. Bellary SS, Steinberg A, Mirzayan N, Shirak M, Tubbs RS, Cohen-Gadol AA, et al. Wormian bones: a review. *Clin Anat*. 2013;26(8):922–927. Available from: <https://doi.org/10.1002/ca.22262>.
 13. Opperman LA, Sweeney TM, Redmon J, Persing JA, Ogle RC. Tissue interactions with underlying dura mater inhibit osseous obliteration of developing cranial sutures. *Dev Dyn*. 1993;198(4):312–334. Available from: <https://doi.org/10.1002/aja.1001980408>.
 14. Roybal PG, Wu NL, Sun J, Ting MC, Schaefer C, Maxson RE. Inactivation of *Msx1* and *Msx2* in neural crest reveals an unexpected role in suppressing heterotopic bone formation in the head. *Dev Biol*. 2010;343(1-2):28–39. Available from: <https://doi.org/10.1016/j.ydbio.2010.04.007>.
 15. Barreto JEF, Lucena JDD, Limeira IS, Souza GGD, Araújo D, Sales TH, et al. Incidence of Sutural Bones at Asterion in Dry Human Skulls in Northeast Brazil. *FASEB J*. 2019;33:616–648. Available from: https://doi.org/10.1096/fasebj.2019.33.1_supplement.616.32.
 16. de León SG, Hernández-Rodríguez AN, Morales-Ávalos R, Theriot-Girón MDC, Elizondo-Omaña RE, Guzmán-López S. Morphometric characteristics of the asterion and the posterolateral surface of the skull: relationship with dural venous sinuses and neurosurgical importance. *Cir Cir*. 2013;81(4):269–273.
 17. Hussain Saheb S, Gf M, St T, Prasanna LC. A study of sutural morphology of the pterion and asterion among human adult Indian skulls. *Biomed Res*. 2011;22(1):73–75.

Copyright: © the author(s), 2021. It is an open-access article distributed under the terms of the Creative Commons Attribution License (CC BY 4.0), which permits authors to retain ownership of the copyright for their content, and allow anyone to download, reuse, reprint, modify, distribute and/or copy the content as long as the original authors and source are cited.

How to cite this article: Gowri I, Vinila BHS. Study on the Incidence of the Occurrence of the Sutural Bones at Asterion in the Dry Adult Human Skulls of the South Indian Population. *Acad. Anat. Int.* 2021;7(2):1-4.

DOI: [dx.doi.org/10.21276/aaanat.2021.7.2.1](https://doi.org/10.21276/aaanat.2021.7.2.1)

Source of Support: Nil, **Conflict of Interest:** None declared.