

Axillary Origin of Radial Artery In Common With Sub-Scapular Artery: A Case Report

Masooma Syed¹, Waqar Akram¹, Nafis Ahmad Faruqi²

¹Senior Resident, Department of Anatomy, J.N.M.C, Aligarh Muslim University, Aligarh, ²Ex Professor, Department of Anatomy, J.N.M.C, Aligarh Muslim University, Aligarh.

Abstract

Knowledge about the vascular structure of upper extremity, both normal and abnormal, is important for diagnostic interventions and surgical procedures. During routine dissection of undergraduate teaching in the Department of Anatomy of JNMC, AMU, Aligarh, a unilateral variation in the origin of radial artery was noted on the right side. Third part of axillary artery gives rise to three branches, anterior circumflex humeral, posterior circumflex humeral and an anomalous common trunk for radial and subscapular artery. The aforementioned anomaly is first of its kind. High origin and superficial course of radial artery may be hazardous and vulnerable to injury during venepuncture and surgical approaches.

Keywords: Radial Artery, Sub-Scapular Artery.

Corresponding Author: Dr. Waqar Akram, Senior Resident, Department of Anatomy, J.N.M.C, Aligarh Muslim University, Aligarh.

Received: August 2019

Accepted: September 2019

Introduction

Variation in the arterial pattern of the upper limb is a common finding during routine cadaveric dissection. It is observed in 18.53-20% in general and radial artery specifically is most commonly involved.^[1,2,3]

Knowledge about the vascular structure of the upper extremity is important for diagnostic interventions and surgical approaches. The variations in origin and course of radial artery are clinically significant due to its superficial course which predispose it to iatrogenic trauma, graft in surgeries and angiographic procedures.^[4]

Radial artery is one of the terminal branches of brachial artery other being ulnar artery. It arises in the cubital fossa at the level of neck of radius about 1cm below the elbow joint, just medial to the tendon of biceps brachii muscle. It then runs under the cover of brachioradialis and reaches the wrist where it is palpable against the lower end of radius. Finally it passes between the two heads of first dorsal interosseous to complete the deep palmar arch with the deep branch of ulnar artery.

Numerous variations have been noted in the radial artery of which high origin is the most common having an incidence of 4.17-15.60%.^[5] Origin of radial artery from the third part of axillary artery proximal to the origin of subscapular artery has been reported by Yagain V.K et.al and Das et al.^[6,7] but the common trunk of origin of radial artery and the subscapular artery has not been reported so far. These

variations have to be kept in mind by the surgeons and the radiologists during interventional procedures. Arteriography should not be performed when there is difficulty in advancement of the guide wire or the catheter in transradial procedures.^[8] A variant radial artery may complicate angiographic procedures and lead to misinterpretation of incomplete angiographic images.^[9,10]

Case Report

During routine dissection for undergraduate teaching in the Department of Anatomy at JNMC AMU Aligarh, a unilateral variation in the origin of radial artery was noted on the right side. The subclavian artery continued as the axillary artery at the outer border of first rib. The axillary artery passed behind the pectoralis minor muscle and then continued beyond the lower border of teres major as the brachial artery in arm. The first part of axillary artery gave origin to one superior thoracic artery. The second part gave 2 branches, the thoracoacromial artery and the lateral thoracic artery. The third part gave rise to 3 branches, anterior circumflex humeral and posterior circumflex humeral arteries and a common trunk from which two arteries arise. One of these arteries has the course similar to the subscapular artery and the other artery descended in the arm over the biceps muscle and then in the cubital fossa ran lateral to biceps tendon. In the forearm it was deep to the brachioradialis muscle which then entered the anatomical snuff box where it passed between the two heads of dorsal interosseous to form the deep palmar arch along with the deep

branch of ulnar artery. The brachial artery continued as the ulnar artery and in the cubital fossa, passed deep to pronator teres muscle. It then enters the palm to form the superficial palmar arch. Continuation of axillary artery as brachial artery was based on their diameters. Therefore ulnar artery was considered as continuation of brachial artery and radial artery, as branch of third part of axillary artery.

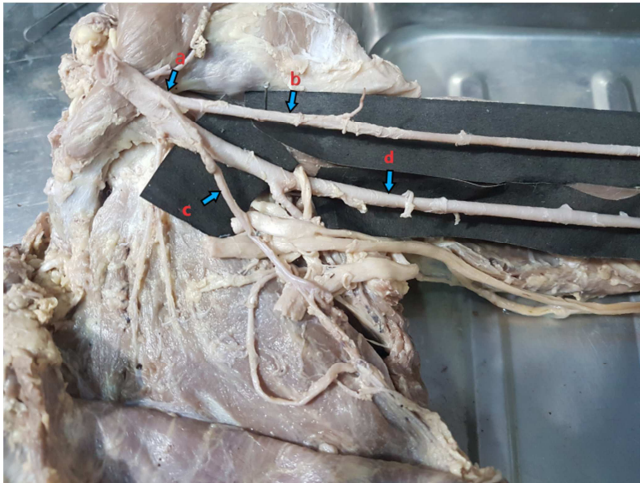


Figure 1: Dissected specimen showing common origin trunk for radial and sub scapular artery (a), radial artery (b), sub scapular artery (c) and brachial artery (d).

Discussion

The high origin of radial artery can be explained embryologically as a failure of disappearance or abnormal persistence of some insignificant embryonic vessels.^[11,12] Edward singer^[13] describes 5 stages of arterial development of upper limb. Williams et al. also agreed to this theory.^[14]

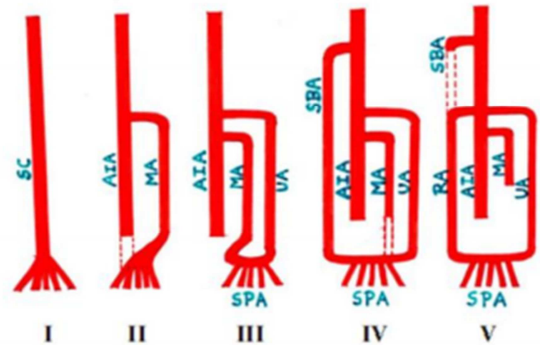
Stage I: At first, the lateral branch of seventh intersegmental artery, i.e., the subclavian artery extends up to the wrist as the axis artery of upper limb, where it terminates by dividing into terminal branches for the fingers forming a capillary plexus. The proximal portion of it forms axillary and brachial arteries respectively, whereas distal portion persists as the anterior interosseous artery of forearm.

Stage II: Subsequently a median artery arises from the anterior interosseous artery, grows along the median nerve to communicate with palmar capillary plexus to feed it. By this time the anterior interosseous artery undergoes regression.

Stage III: In embryos of 18 mm, the ulnar artery arises from brachial artery and unites distally with the median artery to form superficial palmar arch. Digital branches arise from this arch.

Stage IV: In embryo of 21 mm length, the superficial brachial artery develops in the axillary region and traverses the medial surface of the arm and runs diagonally from the ulnar to the radial side of the forearm to the posterior surface of the wrist. There it divides over the carpus into branches for the dorsum of the thumb and index finger.

Stage V: Finally three changes occur. When the embryo reaches the length of 23 mm, the median artery undergoes retrogression becoming a small slender structure, now known as arteria nervi mediana. The superficial brachial artery gives off a distal branch which anastomoses with the superficial palmar arch already present. At the elbow an anastomotic branch develops between the main trunk of brachial artery and existent superficial brachial artery, which shortly enlarges to form the radial artery with the distal portion of the superficial brachial artery, where as the proximal portion of the superficial brachial artery atrophies correspondingly.



If the SBA fails to involute the surviving SBA will have one of the three possible outcomes.

1. SBA may overtake the territory of the definitive brachial artery.
2. It may form a parallel artery to deep brachial artery.
3. It can disappear as it turns into small cutaneous blood vessels.

The present case report it would be considered that the axillary artery gives superficial brachial artery, which appears in the IV stage of development and continues as the radial artery, The anastomosis between the brachial and the superficial brachial artery is not formed at the cubital fossa. The superficial brachial artery gives a subscapular artery at its origin. Thus it can be considered as a common subscapular-radial trunk arising from the third part of axillary artery.

Variations in blood vessels' branching pattern, position or course can alter routine clinical procedures, like blood pressure monitoring or intravenous drug application. Unusual origin of the radial artery may cause difficulties in transradial approach for percutaneous coronary angiography and in the reconstructive surgery of the upper limb.

The presence of these high origin variants of radial artery poses problems with radial forearm free flaps due to their proximity to intravenous infusion sites.^[15] According to Diami et al, the high origin and superficial course of the radial artery may be hazardous and vulnerable to injury during venepuncture and surgical procedures.^[16]

A variant radial artery may complicate angiographic procedures and lead to misinterpretation of incomplete angiographic images.^[9] Compression of the median nerve by the variant radial artery could be misdiagnosed as radiculopathy and neuropathy.^[17]

Conclusion

Knowledge about the variations of the arterial pattern of upper limb may help to prevent diagnostic errors during angiographic procedures and prevent the complications during surgical procedures.

References

1. McCormac LJ, Cauldwell EW, Anson BJ. Brachial and ante brachial arterial patterns- A study of 750 extremities. Surg Gynecol Obst .1953;96: 43-54
2. Natsis K, Papadopoulou AL, Papathanasiou E et al. Study of two cases of high-origin radial artery in humans. Eur J Anat .2009;2: 97-103
3. Drizenko A, May nou C, Mestdagh et.al. Variation of the radial artery in man. Surg Radiol Anat.2000;22: 299-303.
4. Natsis K, Papadopoulou AL, Papathanasiou E et al.Study of two cases of high-origin radial artery in humans. Eur J Anat .2009;2: 97-103.
5. Agarwal S, Lalwani R, Babu CSR. High origin of radial artery: a comparative, anatomical and embryological consideration. Int J Res Med Sci 2016;4:3295-8.
6. Das A,Rai P, Das S, Mehrotra N. High Origin of Radial Artery-A Cadaveric Case Report. Ann.Int.Med.Den,Res.2016;2(5):AT01-AT03.
7. Yagain VK, Dave MR, Anadkat S. Unilateral high origin of radial artery from axillary artery. Folia morphol. 2012;71(2):121-4.
8. Valsecchi O, Vassileva A, Musumeci G et al. Failure of transradial approach during coronary interventions: anatomic considerations. Catheter Cardiovasc Interv. 2006;67:870-8
9. Karlsson S, Niechajev IA. Arterial anatomy of the upper extremity. Acta Radiol. 1982;23:115-21.
10. Pelin C, Zagyapan R, Mas N, Kasabay G. An unusual course of the radial artery. Folia morphol. 2006;65(4):410-3.
11. Patnaik VVG, Kalsey G, Singla RK. Bifurcation of axillary artery in its 3rd part a case report J Anat Soc India. 2001; 50: 166-9
12. Waghmare JE, Tarnekar AM, Sonatkke BR et al. A high origin of radial artery with asymmetrical vasculature of upper limbs: a case report. Nepal Med Coll J. 2009; 4: 284-6.
13. Singer E. Embryological pattern persisting in the arteries of the arm. The Anatomical Record. 1933;55:403-9.
14. Williams PL, Bannister LH, Collins P et al Gray's Anatomy. The Anatomical basis of Medicine and Surgery. 38th Ed., Edinburgh, Churchill Livingstone. 1995; 319, 1269.
15. Wood SJ, Abrahams PH, Sanudo JR et al Bilateral superficial radial artery at the wrist associated with a radial origin of a unilateral median artery. J Anat. 1996;189:691-3.
16. Daimi SR, Siddiqui AU, Wabale RN. Variations in the branching pattern of axillary artery with high origin of radial artery-Case Report. Int J Anat Var. 2010;3:76-7.
17. Pelin C, Zagyapan R, Mas N, Kasabay G. An unusual course of the radial artery. Folia morphol. 2006;65(4):410-3.

Copyright: © the author(s), publisher. Academia Anatomica International is an Official Publication of "Society for Health Care & Research Development". It is an open-access article distributed under the terms of the Creative Commons Attribution Non-Commercial License, which permits unrestricted non-commercial use, distribution, and reproduction in any medium, provided the original work is properly cited.

How to cite this article: Syed M, Akram W, Faruqi NA. Axillary Origin of Radial Artery In Common With Subscapular Artery: A Case Report. Acad. Anat. Int. 2019;5(2):66-68.
DOI: [dx.doi.org/10.21276/aaanat.2019.5.2.18](https://doi.org/10.21276/aaanat.2019.5.2.18)

Source of Support: Nil, **Conflict of Interest:** None declared.