

## Horseshoe Kidney with Bilateral Duplex Ureters

Ashok K R<sup>1</sup>, Rohini K R<sup>1</sup>, Kiran T V<sup>2</sup>

<sup>1</sup>Assistant Professor, BGS Global Institute of Medical Sciences, Kengeri, Bengaluru, Karnataka, <sup>2</sup>Associate Professor, BGS Global Institute of Medical Sciences, Kengeri, Bengaluru, Karnataka.

### Abstract

Horseshoe kidney is the most common fusion anomaly of the kidney. Its association with duplex collecting system is a rare entity. Incidence of infections, calculi and nephroblastoma increases in horseshoe kidney. Knowledge of these rare anomalies is imperative for proper diagnosis and treatment. We observed horseshoe kidney with bilateral duplex ureters in a 65-year-old male cadaver. Details of the anomaly, its embryological basis and significance are discussed in the article.

**Keywords:** Horseshoe kidney, renal fusion anomaly, bilateral duplex ureters, cadaveric study.

**Corresponding Author:** Dr. Ashok K R, Assistant Professor, BGS Global Institute of Medical Sciences, Kengeri, Bengaluru, Karnataka.

**Received:** November 2019

**Accepted:** November 2019

### Introduction

Renal fusion anomaly presents as horseshoe kidney or crossed fused ectopia. Horseshoe kidney is the most common type of renal fusion anomaly.<sup>[1]</sup> Horseshoe kidney occurs in 1 per 400 people. It is more common in males.<sup>[2]</sup> In about one third of cases horseshoe kidney is associated with other congenital anomalies. Duplication of ureters occurs in 0.5 – 2% of individuals.<sup>[3]</sup> Duplicated ureter in horseshoe kidney is a rare entity.<sup>[4]</sup>

### Case Report

During routine dissection for undergraduate students in the Department of Anatomy, BGS Global Institute of Medical Sciences horseshoe kidney with bilateral duplex ureters was appreciated in a 65-year-old male cadaver.

The coverings of kidney were removed. Blood vessels of horseshoe kidney were noted. Ureters were cleaned and dissected throughout its course. Horseshoe kidney, ureters and urinary bladder were removed enmasse and photographed.

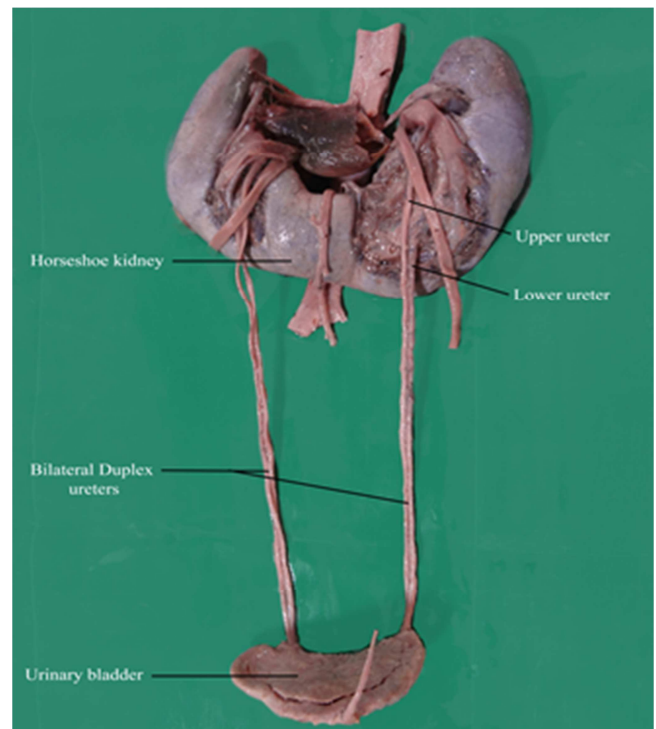
Kidneys were fused at their lower poles. The ascent of horseshoe kidney was arrested by the root of inferior mesenteric artery.

Right renal artery divided into three branches - superior, middle and inferior. Inferior suprarenal artery originated from superior branch. Left renal artery divided into two branches - superior and inferior. The left inferior suprarenal artery originated from the main trunk of left renal artery.


On the right side there were two renal veins, both of them drains into inferior vena cava. Over the left side a single renal vein drains the kidney and terminated in inferior vena

cava.

Two ureters with two pelvicalyceal systems were noted on both sides. The upper right and left ureter originated from the medial border of corresponding kidney. The lower ureters originated from the anterior surface of the lower part of the kidneys. The upper and lower ureters fused within the bladder wall and opened at the superolateral angle of trigone.



**Figure 1: Horseshoe kidney with bilateral duplex ureters.**



**Figure 2: Fusion of duplex ureters within the bladder wall.**



**Figure 3: Opening of ureter at the superolateral angle of trigone.**

## Discussion

Renal anomalies and anomalies of urinary tract occur in 3 – 6% of live births.<sup>[5]</sup> Of all renal anomalies renal agenesis, horseshoe kidney, hypoplasia of kidneys and lobulated kidneys are more common.

Horseshoe kidney is a type of fusion anomaly which occurs in 0.2 % of population. In horseshoe kidney either upper or lower pole can be fused. Lower pole fusion occurs in 90% of cases.<sup>[1]</sup> The fused lower part which connects the both kidneys is known as isthmus of kidney which lies in front of abdominal aorta and inferior vena cava. The ascent of horseshoe kidney is arrested by root of inferior mesenteric artery.<sup>[6]</sup> Horseshoe kidney may be a result of teratogenic factors.<sup>[4]</sup> About 7% of Turner's syndrome patients have horseshoe kidney.<sup>[6]</sup>

Duplication of ureter is the common upper tract anomaly.<sup>[4]</sup> If two separate ureteric buds originate from mesonephric duct to interact with metanephric blastema it results in complete duplicated ureters.<sup>[7]</sup> Occasionally the single ureteric bud bifurcates prematurely and enters the substance of metanephric mesenchyme resulting in duplication of

ureter.<sup>[8]</sup> The extent of duplication depends on how complete the division of diverticulum was.<sup>[6]</sup>

A horseshoe kidney with bilateral ureteral duplication is a very rare entity. Only few cases of horseshoe kidney with duplex pelvicalyceal system and ureters has been reported to the best of our knowledge. Sharma PK et al,<sup>[1]</sup> Christoffersen J et al,<sup>[9]</sup> Afzal U et al,<sup>[10]</sup> have observed bilateral duplex collecting system in horseshoe kidney. Ongeti K W et al [2], Keskin S et al,<sup>[3]</sup> and Singh SK et al,<sup>[11]</sup> observed bilateral partial ureteral duplication in horse shoe kidney whereas Tyagi V et al,<sup>[4]</sup> Mirzazadeh M et al,<sup>[7]</sup> Segura J W et al,<sup>[12]</sup> and Sumner T E et al,<sup>[13]</sup> reported complete unilateral duplication in horseshoe kidney. Pode D et al,<sup>[14]</sup> reported a rare case of unilateral triplication of collecting system in a horseshoe kidney.

Afzal U et al,<sup>[10]</sup> and Ongeti KW et al,<sup>[2]</sup> have observed duplication of renal vessels in horseshoe kidney.

Horseshoe kidney with bilateral duplex ureters itself is not a fatal condition, but the individuals with this kind of anomaly are susceptible to certain conditions like hydronephrosis in 80% of cases, about 20% develop renal calculi.<sup>[4]</sup> Ureteropelvic junction obstruction occurs in 35% of patients. Vesicoureteral reflux predisposes the horseshoe kidney to recurrent infection.<sup>[1]</sup> Certain renal tumors are also frequent in horseshoe kidney.<sup>[15]</sup>

Intravenous pyelography is the first line of investigation to diagnose horseshoe kidney and duplex ureters. In doubtful cases CT scan can be performed.<sup>[1]</sup> Clinical problems of horseshoe kidney can be managed by standard urologic procedures.<sup>[16]</sup>

Knowledge of anatomy of horseshoe kidney, its association with bilateral partial or complete duplex ureters assures good postoperative outcomes during transplant or other surgical procedures of kidney in patients with horseshoe kidney. Surgeons and radiologists should be conscious of this anomaly which may throw a challenge during diagnosis and surgical interventions.

## Conclusion

Horseshoe kidney with bilateral duplex ureters was observed in a male cadaver. The isthmus of horseshoe kidney was below the root of inferior mesenteric artery. The upper ureters originated from the medial border, the lower ones from anterior surface of corresponding kidneys. Teratogenic and genetic factors are said to be the causative factors for these anomalies. Though the anomaly remains asymptomatic in most individuals they are prone to reflux, infection, calculi and malignancy. Clinicians should have knowledge of these anomalies for proper diagnosis and treatment.

## References

1. Sharma PK, Sharma R, Vijay MK, Goel A, Kundu AK. Bilateral Duplex collecting system in Horseshoe kidney: An unusual association. International Brazilian journal of urology. 2013 January – February; 39(1): 139-40.
2. Ongeti KW, Ogengao J, Hassan SA horseshoe kidney with partial duplex systems. IJAV. 2011; 4: 55-6.
3. Keskin S, Erdogan N, Kurt A, Tan S, Ipek A. Bilateral partial ureteral duplication with double collecting system in horseshoe

- kidney. *Adv Med Sci.* 2009; 54(2): 302-4.
4. Tyagi V, Dar TI, Khawaja AR, Chadha S. Horseshoe kidney with complete unilateral duplication of ureter and pelvicalyceal system – A case report. *Urology journal.* 2013; 10(4):1162-4.
  5. Collins P, Jawaheer G, Sharpe RM. Development of the Urogenital system. In: Susan Standing. *Gray's Anatomy: The Anatomical basis of clinical practice.* UK: Elsevier; 2016. p. 1206.
  6. Moore KL, Persuad TVN. The Urogenital system. In: *The Developing Human – clinically oriented embryology.* India: Elsevier; 2008. p. 255
  7. Mirzazadeh M, Richards KA. Complete duplication of collecting system in a horseshoe kidney presenting with recurrent urinary tract infection. Report of an exceedingly rare congenital anomaly and review of literature. *The Scientific World Journal.* 2011; 11: 1591-1596.
  8. Schoenwolf GC, Bleyl SB, Brauer PR, Francis PH. *Larsen's Human Embryology.* China: Elsevier; 2009. P. 388.
  9. Christoffersen J, Iversen HG. Partial hydronephrosis in a patient with horseshoe kidney and bilateral duplication of pelvis and ureter. *Scand J Urol Nephrol.* 1976; 10: 91-3.
  10. Afzal U, Al-Shammari RM, Siraj QH, Hebbbar S. A case of dupable duple duplicity and duplexity. *Asea Oceania J Nucl Med Biol.* 2013; 1(2): 53-55.
  11. Singh SK, Kumar A. Bilateral partial duplex collecting system in Horseshoe kidney with stone in the left upper and lower moiety: An unusual association. *Saudi J Kidney Dis Transpl.* 2015; 26(3): 608-610.
  12. Segura JW, Kelalis PP, Burke EC. Horseshoe kidney in children. *J Urol.* 1972; 108: 333-336.
  13. Sumner TE, Volberg FM, Munitz A, Harrison LH, Mashburn AM. Unilateral duplex horseshoe kidney with ectopic ureterocele. *South Med J.* 1985; 78: 199-201.
  14. Pode D, Shapiro A, Lebensart P. Unilateral triplication of the collecting system in a horseshoe kidney. *J Urol.* 1983; 130: 533-4.
  15. Fazio L, Razvi H, Chin JL. Malignancy in horseshoe kidneys: review and discussion of surgical implications. *Cand J Urol.* 2003 June; 10(3): 1899-1904.
  16. Pitts WR Jr, Muecke EC. Horseshoe kidneys: A 40 year experience. *J Urol.* 1975 June; 113(6): 743-6.

**Copyright:** © the author(s), publisher. Academia Anatomica International is an Official Publication of “Society for Health Care & Research Development”. It is an open-access article distributed under the terms of the Creative Commons Attribution Non-Commercial License, which permits unrestricted non-commercial use, distribution, and reproduction in any medium, provided the original work is properly cited.

**How to cite this article:** Ashok KR, Rohini KR, Kiran TV. Horseshoe Kidney with Bilateral Duplex Ureters. *Acad. Anat. Int.* 2019;5(2):52-4. DOI: [dx.doi.org/10.21276/aaanat.2019.5.2.14](https://doi.org/10.21276/aaanat.2019.5.2.14)

**Source of Support:** Nil, **Conflict of Interest:** None declared.