

Gross Anatomical Study on the Skull and Mandible of the Wild Boar (*Sus Scrofa*) In the Caribbean

Reda Mohamed^{1,2}

¹Department of Basic Veterinary Sciences, School of Veterinary Medicine, Faculty of Medical Sciences, The University of the West Indies, St. Augustine, Trinidad and Tobago, ²Anatomy and Embryology Department, Faculty of Veterinary Medicine, Beni-Suef University, Beni-Suef 62511, Egypt.

Abstract

Introduction: Wild pigs (*Sus scrofa*), which are found throughout the Caribbean island of Trinidad and Tobago, are sometimes used experimentally, in the field of biomedical science, to model the human anatomy. In particular, the skull, which is very important as it houses vital organs and foramina, has clinical importance in applying regional anesthesia. **Subjects and Methods:** The present work was conducted on two skulls and mandibles of wild pigs to grossly describe their osteology and foramina. The information garnered can be used for comparative studies of the skulls and mandibles with other similar species. The skulls and mandibles were prepared and cleaned using standard method. All of the characteristic features of various standards views of the skulls bones, including dorsal, lateral, caudal, and the lateral, rostral and caudal views of the mandibles as well as the foramina of the skulls and mandibles were described and discussed. **Results:** Each skull was divided into long facial and short cranial regions. The tympanic bulla was small. The supraorbital foramina and grooves were present. The zygomatic process of the zygomatic bone and the zygomatic process of the temporal bone formed the large zygomatic arch. The mandible was a paired bone with ossified mandibular symphysis. The dental formula was confirmed and it was 44 teeth. **Conclusion:** The bones and foramina of the skull and mandible were homologue to that of other mammals.

Keywords: Anatomy, Skull, Mandible, Wild Pig, Caribbean.

Corresponding Author: Dr. Reda Mohamed, Department of Basic Veterinary Sciences, School of Veterinary Medicine, Faculty of Medical Sciences, The University of the West Indies, St. Augustine, Trinidad and Tobago.

Received: August 2019

Accepted: September 2019

Introduction

The wild boar (*Sus scrofa*) is one of the most widespread mammals in the world and, therefore, is found in the Caribbean island of Trinidad. There are almost 500 different breeds of pigs worldwide and they supply a large percentage of important livestock species. ^[1]Pigs are also used experimentally in many biomedical fields due to their similarities with the human anatomy. ^[2]Anatomically, the skull supports many vital organs such as the brain, eyes, lips, teeth, tongue and nose, so, it is vitally important in the coordination of the body and in deglutition and olfaction.^[3]Furthermore, the passages of the cranial nerves through their different foramina in the skull and mandible are of clinical importance in the application of anesthesia in and around the head. ^[4-5] Also, the morphology of the bones are used for specie identification, age and forensic investigation as well as the dental arcades in the adult pig is similar to that of humans and can be used as an experimental animal in human odontology. The objective of this study was to describe the anatomical appearance of the skull and mandible of the wild pig to identify the species as well as to describe its dental formula which will be useful for undergraduate students in dentistry.

Subjects and Methods

The heads of two wild pigs that died in the zoo in the island of Trinidad were brought to the department of basic veterinary sciences, School of Veterinary Medicine in the University of the West Indies, Trinidad and Tobago. No skeletal deformities were detected upon inspection of the heads which were then boiled and treated to remove the skin and muscles, then bleached in 3% hydrogen peroxide and then left to dry. ^[6] The different standard views of the skull and mandible were then photographed, for documentation using a digital camera. The Nomina Anatomica Veterinaria was referred to in naming the foramina and bones of the skull. ^[7]

Results

In the wild pig, the skull was flat and wide. The bony part of the dorsal, lateral and medial aspect of the face was made up of the nasal, premaxilla, lacrimal, zygomatic, maxilla, palatine, pterygoid, vomer and turbinate bones. Ventrally, the hard palate was observed and it consisted of the palatine processes of the premaxilla and the palatine bones. The

choanae were seen at the end of the hard palate and the cribriform plate served to separate the nasal cavity from each of the cranium. The nasal region consisted of nasal, frontal and parietal bones that are bounded on either side by the premaxilla, maxilla, lacrimal and temporal bone (Figures 1, 2,3and 4).

The incisive bone was a paired bone and formed the greatest rostral extension of the bony skull. It articulates with the nasal and maxillary bones. The fused incisive bone aided in the formation of the bony hard palate and the bony nasal aperture. It consisted of a body as well as the alveolar, nasal and palatine processes. The fusion of paired bones along the midline was incomplete leaving the incisive fissure. The alveolar process contained the first upper incisor teeth in its alveolar sockets. It also contained a groove for the major palatine artery. The nasal process extended dorsocaudally forming part of the lateral nasal wall and it articulated with the nasal bone dorsomedially forming the nasomaxillary notch. The palatine process was a vertical thin plate which fused with the same process medially and with that of the maxillary bone medially. There were the palatine fissures between the palatine process of the body and palatine process of the incisive bone. The paired nasal bone formed a considerable part of the roof of the nasal cavity and the dorsal aspect of the bone appeared flattened with the exception of the supraorbital sulcus. It tapered rostrally forming the nasal process (Figures 1, 2,3and 4).

The maxilla was an extensive bone, which formed a considerable part of the lateral wall of the nasal cavity. It consisted of nasal and facial parts. It contained all of the upper check teeth. The facial part had the infraorbital foramen for the transmission of the infraorbital vessels and nerve, the small maxilloincisive foramen and the facial crest which extended caudally onto the zygomatic process and it surrounded the fossa canina in which the muscles of the snout originate. The zygomatic processes of the zygomatic and temporal bones formed the massive zygomatic arch. The arch, which was prominent and projected laterally, gave rise to the frontal process of the zygomatic bone at the dorsal border. The alveolar process of the maxilla bone housed the upper check teeth. There was a projection for the canine tooth, eminentia canina, at the rostral extent of the alveolar process of the maxilla bone. The orbits were small and the caudal aspect of the orbit was open, as the zygomatic process of the frontal bone did not connect with that of the frontal process of the zygomatic bone (Figures 1, 2,3and 4).

The basicranium was situated between palate, containing the teeth, the maxilla and premaxilla and the main body of the cranium containing the bulla tympanica, the posterior nares of the nasal aperture, the palatine bone, the basal part of the occipital and the root of the paramstoid. The bones of the basicranium were the frontal, parietal, sphenoid, temporal and occipital bones. The palatine bone formed articulated with the ethmoid bone distolaterally and with the vomer bone medially. It presented a horizontal and a perpendicular part. The horizontal lamina, along with the lamina of the opposite side formed the caudal one fourth of the hard palate when fused on the midline. The perpendicular lamina

formed the lateral wall of the nasopharynx. It had the pterygoid process. The ethmoid bone continues onto the lateral face of the palatine bone forming the pterygopalatine fossa (Figures 1, 2,3and 4).

The nuchal crest was broad and prominent. It was the highest part of the skull and formed a part of the occipital bone, which thins laterally and turns downwards to form part of the temporal crest. The temporal crest formed a concave depression caudal to the centre of the nuchal crest in which the foramen magnum with two diverge ridges were located at its base. The paramstoid processes of the wild pig were straight and very long with the hypoglossal foramen caudaomedially to the root of the paramstoid. The ethmoid bone lied deep within the skull and situated between the cranial and facial parts of the skull (Figures 1, 2, 4 and 5).

The dental formula of the upper arcade was 3-1-4-3, with long straight lower incisors and curved upper incisors which allowed a grasping action. The canine root does not close and continues to grow throughout the life. The lower canine rubs against the upper canine, a constant sharpening action that allows the canine to be used in self-defense.

The mandible was the largest paired bone with fully ossified mandibular symphysis forming an immovable joint. The mandible was lack of mandibular tuberosity. Each part of the mandible had a ramus and a body. The dorsal border of the mandible housed the dental alveoli for six incisors, two canines, eight premolars and six molars. The ramus had the condylar and coronoid processes along with strongly excavated masseteric fossa. There were two mandibular foramina on the pair of rami of the mandible on the pterygoid fossae, while, laterally, there was a mental foramen on both sides of the body of the mandible (Figures 6, 7and 8). The dental formula of the wild pig was 44 teeth; Incisor (I) 3/3, Canines (C) 1/1, Premolars (Pm) 4/4, Molar (M) 3/3x 2= 44.

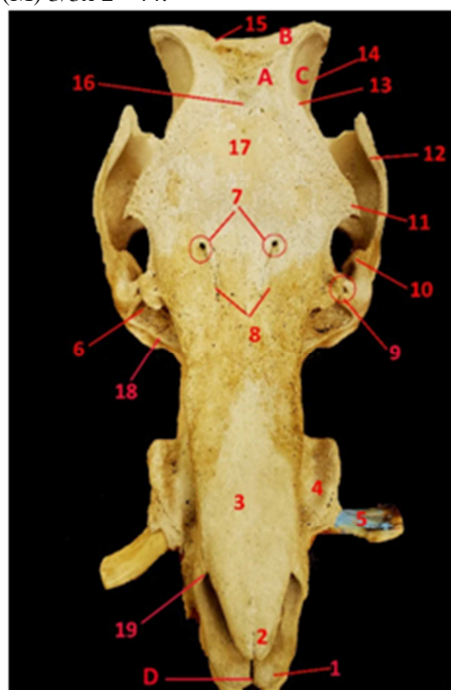


Figure 1: photograph showing the dorsal view of the skull of the wild pig.

1. Premaxilla; 2. Rostral process of the nasal bone; 3.Nasal bone; 4.Eminentia canina; 5.Upper canine tooth; 6.Preorbital fossa; 7.Supraorbital foramina; 8.Supraorbital grooves; 9.Lacrimal foramina; 10.Frontal process of zygomatic bone; 11.Zygomatic process of frontal bone (*Supraorbital process*); 12.Zygomatic process of temporal bone; 13.Temporal line; 14.Temporal crest; 15.Nuchal crest; 16.Frontal fossa; 17.Frontal bone; 18.Facial crest; 19. Nasoincisive notch; A. Parietal bone; B. Occipital bone; C. Temporal bone; D. Incisive fissure

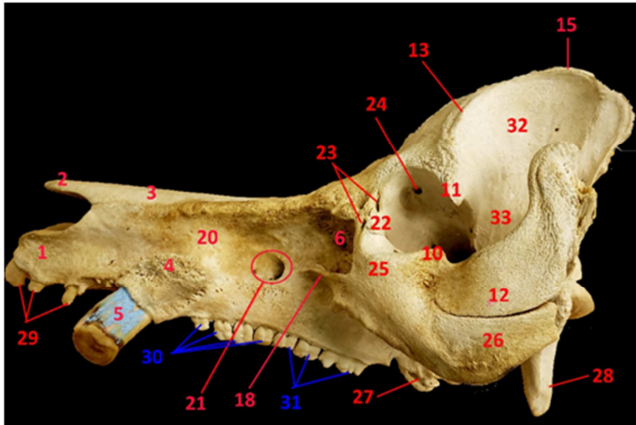


Figure 2: Photograph showing the lateral view of the skull of the wild pig.

1. Premaxilla, 2. Rostral process of the nasal bone, 3.Nasal bone, 4.Eminentia canina; 5.Upper canine tooth; 6.Preorbital fossa; 10.Frontal process of zygomatic bone; 11.Zygomatic process of frontal bone (*Supraorbital process*); 12.Zygomatic process of temporal bone; 13.Temporal line; 15.Nuchal crest; 18.Facial crest; 20.Maxilla; 21.Infraorbital foramen; 22.Lacrimal bone; 23.Lacrimal foramina; 24.Internal opening of supraorbital canal; 25.Zygomatic (Malar) bone; 26.Zygomatic process of zygomatic bone; 27.Pterygoid process of palatine bone; 28.Paracondylar process; 29.Upper incisor teeth; 30.Upper premolar teeth; 31.Upper molar teeth; 32. Temporal fossa;

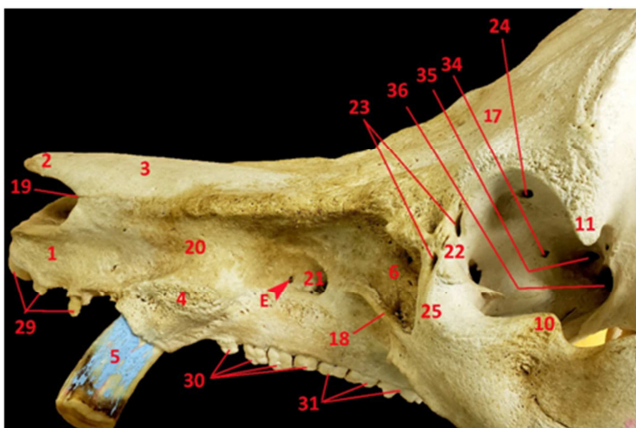


Figure 3: Photograph showing the lateral view of the skull of the wild pig.

1. Premaxilla; 2. Rostral process of the nasal bone; 3.Nasal

bone; 4.Eminentia canina; 5.Upper canine tooth; 6.Preorbital fossa; 10.Frontal process of zygomatic bone; 11.Zygomatic process of frontal bone (*Supraorbital process*); 17.Frontal bone; 19.Nasoincisive notch; 20.Maxilla; 21.Infraorbital foramen; 22.Lacrimal bone; 23.Lacrimal foramina; 24.Internal opening of supraorbital canal; 25.Zygomatic (Malar) bone; 29.Upper incisor teeth; 30.Upper premolar teeth; 31.Upper molar teeth; 34.Ethmoidal foramen; 35.Optic foramen; 36. Foramen orbitorotundum; E. Maxilloincisive foramen.

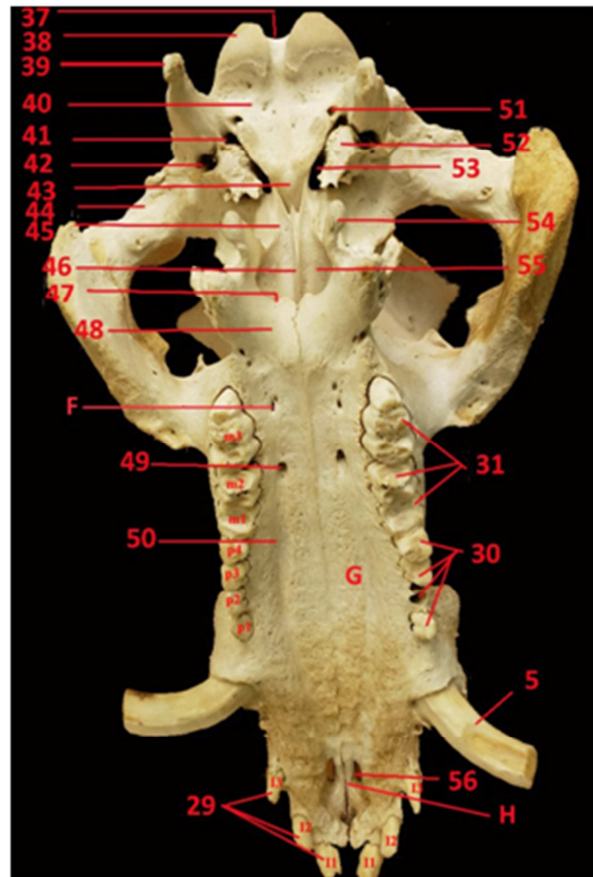


Figure 4: Photograph showing the lateral view of the skull of the wild pig.

5. Upper canine tooth; 29. Upper incisor teeth; 30.Upper premolar teeth; 31.Upper molar teeth; 37.Foramen magnum; 38.Occipital condyle; 39.Paracondyloid process; 40.Basilar part of occipital bone; 41.Posterior foramen lacerum; 42.Stylomastoid foramen; 43.Body of sphenoid bone; 44.Temporal condyle; 45.Pterygoid bone; 46.Vomer bone; 47.Choanae (posterior nares); 48.Horizontal process of palatine bone; 49.Major palatine foramen; 50.Palatine groove; 51.Hypoglossal foramen; 52.Bulla tympanica; 53.Anterior foramen lacerum; 54.Hamulus of pterygoid bone; 55.Perpendicular part of palatine bone; 56. Palatine fissure; F. Minor Palatine foramen; G. Alveolar process of maxillary bone; H. Palatine process of incisive bone.

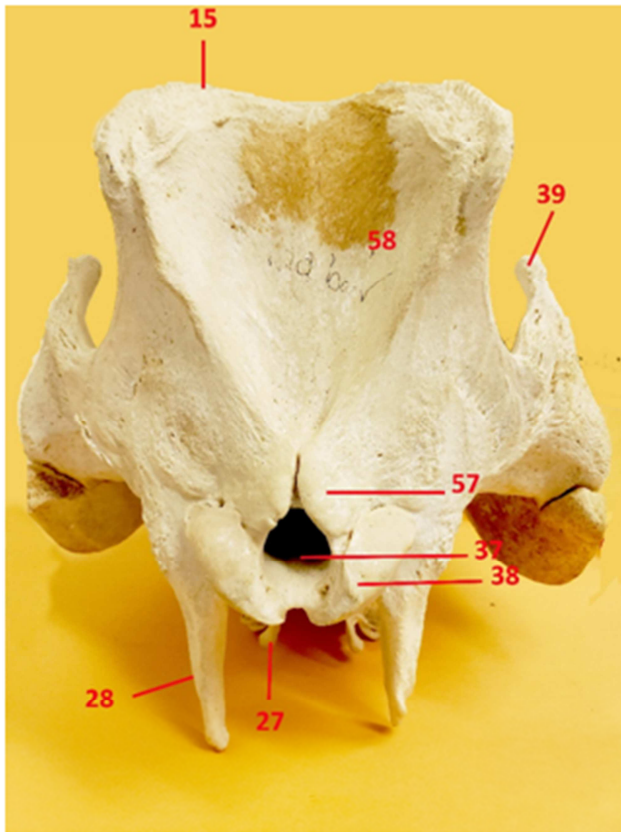


Figure 5: Photograph showing the caudal view of the skull of the wild pig.

15. Nuchal crest; 27. Pterygoid process of palatine bone; 28.Paracondylar process; 37.Foramen magnum; 38.Occipital condyle; 39.Paracondyloid process; 57.Nuchal tubercle; 58.Occipital fossa.

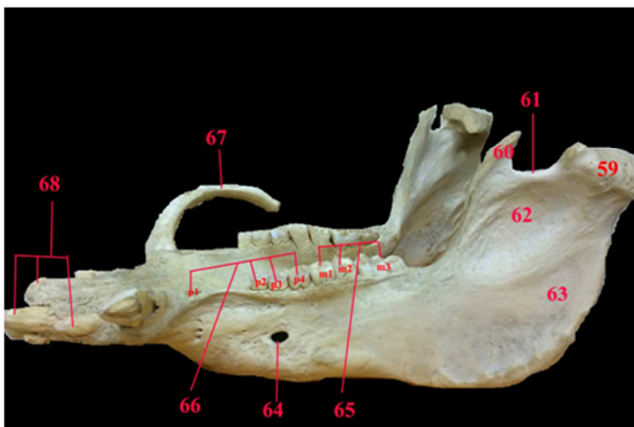


Figure 6: Photograph showing the lateral view of the mandible of the wild pig.

59. Condylar process; 60. Coronoid process; 61.Mandibular notch; 62 Masseteric fossa; 63.Ramus of the mandible; 64.Mental foramen; 65.Molar teeth; 66.Premolar teeth; 67. Upper canine tooth; 68. Upper incisor teeth.

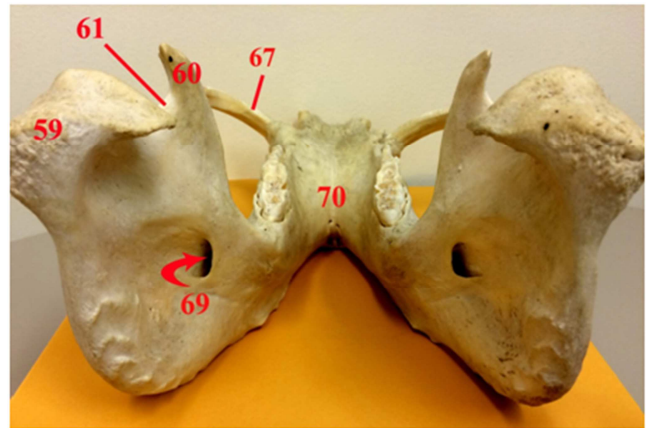


Figure 7: Photograph showing the caudal view of the mandible of the wild pig.

59. Condylar process; 60. Coronoid process; 61.Mandibular notch; 69.Mandibular foramen; 70.Body of the mandible.

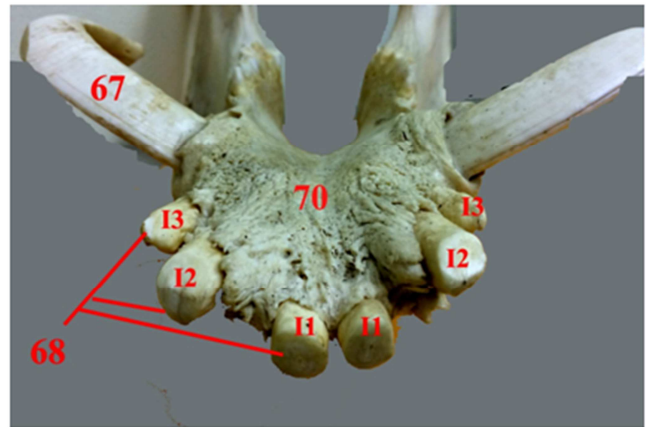


Figure 8: Photograph showing the rostral view of the mandible of the wild pig.

67. Lower canine tooth; 86. Lower incisor teeth (I1,I2, I3); 70. Body of the mandible.

Discussion

Literature on the gross description of the osteology of the skull and mandible of the wild boar in the Caribbean was limited. However, the description of the skull of the wild boar of Mizoram^[8] and the mandible of the local pig of Mizoram^[9] were available. In this study, the skull was wide at the level of the zygomatic arch and narrow at the level of the temporal fossa as mentioned in the dum pigs.^[10] The supraorbital foramina and supraorbital grooves were present in the skull of the wild boar; a similar result was noticed in the wild boar of Mizoram^[8] and in the pygmy pig.^[11] Similar to the observations in the wild boar of Mizoram^[8] and in the pygmy pig^[11], the zygomatic arch was flattened, short, massive and projected laterally. Moreover, the external sagittal crest was prominent and sufficiently wide to facilitate the attachment of one of the main chewing muscles, the temporalis muscle. The orbit of the wild boar was oval in outline and lacked a bony roof its rim was incomplete and there was a ligament from frontal process of

the zygomatic bone to the zygomatic process of the frontal bone. Moreover, the orbital rim showed two lacrimal foramina, optic foramen, foramen orbitorotundum, ethmoidal foramen and internal opening of the supraorbital canal. Similar findings were reported in the wild boar of Mizoram^[8] and in domestic animals.^[12]

The skull had the large maxillary foramen which leads to a short wide infraorbital canal, the large sphenopalatine foramen and the small caudal palatine foramen; similar findings are reported in the wild boar of Mizoram.^[8] Moreover, the facial crest was short, sharp and prominent showing the deep periorbital fossa; similar findings were reported in the wild boar of Mizoram.^[8] However, the facial crest was less distinct in pig.^[13] The upper canine teeth curves and on the maxilla there is an enlargement, caused by its root, known as eminentia canina; similar findings were reported in the wild boar of Mizoram^[8] and in domestic animals.^[12] The tympanic bulla was small in the wild pig; similar result was observed in the wild boar of Mizoram^[8] and in the dum pig of Assam.^[10] Moreover, due to the absence of the styloid process in the skull of the present as mentioned in the skull of the wild pig of Mizoram^[8] and in the skull of domestic animals^[13], the hyoid apparatus articulated with the nuchal process. This investigation recorded that the upper dental formula of the wild pig is similar to that of the wild boar of Mizoram^[8] and domestic animals.^[12] Similarly, also, the alveolar process of the incisive bone carried the three dental alveoli for the upper incisor teeth, while the alveolar process of the maxilla carried the dental alveoli for the upper canine, four premolars and three molars. On the dorsal aspect, the nuchal crest of the skull of the wild pig was prominent and showed central tubercle and thickened lateral extremities and the deep occipital fossa had a triangular shape, similar result was recorded in the skull of the wild boar of Mizoram^[8] and in the dum pig of Assam^[10]. Moreover, there was no external occipital protrusion in domestic pigs^[12], while it was a rough elongated ridge in the centre of the occipital fossa in the wild boar of Mizoram.^[8] In the skull of the wild pig, the mandible was the largest bone; similar result was noticed in the local pig of Mizoram^[9], in the ox^[14] and in the horse.^[15] Furthermore, the mandible consisted of two parts that were connected firmly at the mandibular symphysis, as mentioned in the local pig of Mizoram^[9], in the dog^[16] and in the chital.^[17] The mandible of the wild pig carried the dental alveoli for upper six incisors, two canines, eight premolars and six molars; similar result is noticed in the local pig of Mizoram.^[9] The present investigation records that each part of the part contained one mental foramen correspond to that of the yak^[19] and chital.^[17] However, it has two mental foramina in the local pig of Mizoram.^[9]

Conclusion

The description of the foramina and bones of the skull and mandible of the wild pig was recorded. There were many similarities between the osteology and foramina of the skull and mandible of the wild pig from the Caribbean island of Trinidad and Tobago and that of other mammals. Moreover, this study can be of great importance in taxonomic affiliation of the skull and mandible of the wild pig and can make way for future studies in functional and comparative anatomy.

References

1. Rothschild MF. Porcine genomics delivers new tools and results: This little piggy did more than just go to market. *Genetics Research*. 2004; 83: 1-6.
2. Stembírek J, Kyllar M, Putnová I, Stehlík L and Buchtová M. The pig as an experimental model for clinical craniofacial research. *Laboratory Animals*. 2012; 46: 269-279.
3. Dyce KM, Sack WO, Wensing CJG. *Textbook of veterinary anatomy*, 3rd edn. WB Saunders, Philadelphia; 2002.
4. Hall, L., Clarke, K.W., Trim, C.M. *Wright's Veterinary Anaesthesia and Analgesia*. 10th edn. ELBS and Bailliere Tindall, London; 2001.
5. Olopade JO. The morphometry of the craniofacial and maxillofacial regions of the West African Dwarf Goats (*Capra hircus*). M. Sc. thesis, Department of Veterinary Anatomy, University of Ibadan, Ibadan, Nigeria; 2003.
6. Hildebrand M. *Anatomical preparations*. University of California Press. Berkeley and Los Angeles, California; 1968.
7. International Committee on Veterinary Gross Anatomical Nomenclature. *Nomina Anatomica Veterinaria*, 5th ed.; World Association on Veterinary Anatomist: Knoxville, TN, USA; 2012.
8. Doley PJ, Kalita PC, Kalita A, Choudhary OP and Das H. Morphological Study on the Skull of Wild Boar of Mizoram (*Sus scrofa*). *International Journal of Livestock Research*. 2018; 8 (6): 185-193.
9. Choudhary OP, Kalita PC, Doley PJ and Kalita A. Morphological Studies on the Mandible of Local Pig (Zovawk) of Mizoram (Short communication). *Journal of Animal Research*. 2018; 8 (4): 919-922.
10. Sarma K and Sarma M. Anatomy of the skull of dum pig of Assam. *Indian Veterinary Journal*. 2002; 79: 708-711.
11. Kalita PC, Deka A, Kalita A, Doley PJ and Das BJ. Morphology of the skull of Pygmy Hog (*Porcula salvania*)- A Forensic Approach. *IOSR Journal of Agriculture and Veterinary Science*. 2015; 8 (1): 23-26.
12. Nickel R, Schummer A and Seiferle E. *Viscera of the Domestic Animals*. Vol. 2, Verlag Paul Parey, Hamburg; 1981.
13. König H E and Liebich H G. *Veterinary Anatomy of Domestic Mammals Textbook and Colour Atlas*. Schattauer GmbH, Stuttgart, Germany; 2009.
14. Raghavan D. *Anatomy of ox*. Indian Council of Agricultural Research, New Delhi; 1964.
15. Getty R. *The Anatomy of the Domestic Animals*. Vol. I, 5th edn. W.B. Saunders's Company, Philadelphia; 1975.
16. Miller ME, Christensen GC and Evans HE. *Anatomy of the Dog*. W.B. Saunders's Company, Philadelphia; 1964.
17. Kumawat R, Mathur R, Joshi S and Choudhary OP. Gross morphological studies on mandible of Indian blackbuck (*Axis axis*). *Ind. Vet. J.* 2014; 91(9): 105-107.
18. Archana, Sudhakar LS and Sharma DN. Anatomy of the mandible of yak (*Bos grunniens*). *Indian J. Vet. Anat.* 1998; 10(1/2):16-20.

Copyright: © the author(s), publisher. Academia Anatomica International is an Official Publication of “Society for Health Care & Research Development”. It is an open-access article distributed under the terms of the Creative Commons Attribution Non-Commercial License, which permits unrestricted non-commercial use, distribution, and reproduction in any medium, provided the original work is properly cited.

How to cite this article: Mohamed R. Gross Anatomical Study on the Skull and Mandible of the Wild Boar (Sus Scrofa) In the Caribbean. Acad. Anat. Int. 2019;5(2):46-51.
DOI: [dx.doi.org/10.21276/aanat.2019.5.2.13](https://doi.org/10.21276/aanat.2019.5.2.13)

Source of Support: Nil, **Conflict of Interest:** None declared.