

# Comparison of Ultrasound-Guided Transversus Abdominis Plane Block with Bupivacaine and Ropivacaine as Adjuncts for Postoperative Analgesia in Laparoscopic Cholecystectomies

Vivek Vaibhav<sup>1</sup>

<sup>1</sup>Assistant Professor, Department of Anaesthesia, Rama Medical College, Hospital and Research Centre, Hapur, Uttar Pradesh, India.

## Abstract

**Background:** To compare ultrasound-guided transversus abdominis plane block with bupivacaine and ropivacaine as adjuncts for postoperative analgesia in laparoscopic cholecystectomies. **Subjects and Methods:** 76 patients scheduled for laparoscopic cholecystectomy, were split into 2 groups of 38 each. Both groups got ultrasound-guided TAP blocks with 0.25% bupivacaine (plain) in group I and 0.375% ropivacaine (plain) in group II. At time intervals of 10 minutes, 30 minutes, an hour, four hours, eight hours, twelve hours, and twenty-four hours, all patients were evaluated for post-operative pain and rescue analgesic usage. **Results:** Group I had 20 males and 18 females and group II had 17 males and 21 females. The mean weight in group I was 64.2 kgs and in group II was 63.8 Kgs. The mean height was 158.4 cms in group I and 158.3 cms in group II. The mean duration of surgery was 71.4 minutes in group I and 74.2 minutes in group II. The difference was non-significant ( $P > 0.05$ ). The mean pain score at 10 minutes was 0.0 in both groups. At 30 minutes, it was 1.6 in group I and 0.0 in group II. At 1 hour was 2.0 in group I and 0.0 in group II. At 4 hours was 2.4 in group I and 2.5 in group II. At 8 hours was 2.2 in group I and 2.3 in group II. At 12 hours was 1.6 in group I and 2.1 in group II. At 24 hours was 1.2 in group I and 1.1 in group II. The difference was significant ( $P < 0.05$ ). **Conclusion:** In patients undergoing laparoscopic cholecystectomy, ultrasound-guided deposition of ropivacaine 0.375% in the TAP offered greater analgesia in the early post-operative period compared to bupivacaine 0.25%.

**Keywords:** Laparoscopic cholecystectomy, Bupivacaine, Ropivacaine.

**Corresponding Author:** Dr. Vivek Vaibhav, Assistant Professor, Department of Anaesthesia, Rama Medical College, Hospital and Research Centre, Hapur, Uttar Pradesh, India.

Received: July 2019

Accepted: August 2019

## Introduction

Cholelithiasis, commonly known as gallstones, refers to the formation of solid deposits or stones in the gallbladder or bile ducts. The gallbladder is a small organ located beneath the liver, and its primary function is to store bile, a digestive fluid produced by the liver.<sup>[1]</sup> Gallstones can vary in size, from tiny grains to larger stones that can cause significant problems. Gallstones form when the bile contains excessive amounts of cholesterol, bilirubin (a pigment found in bile), or when the gallbladder fails to empty properly. There are different types of gallstones, including cholesterol stones (the most common type) and pigment stones.<sup>[2]</sup>

It can be managed with conventional cholecystectomy and laparoscopic cholecystectomy, the latter has a number of advantages over open surgery, including reduced discomfort, a shorter hospital stay, and a quicker recovery.<sup>[3]</sup> Additionally, it has a lower incidence of complications and infections. For the majority of patients who require gallbladder removal, laparoscopic cholecystectomy is regarded as a safe and efficient treatment. However, there are risks and potential consequences that should be explored with a licenced

healthcare expert as with any surgical operation.<sup>[4]</sup>

Non-steroidal anti-inflammatory medications, opioids (intravenous [IV] patient-controlled analgesia), local anaesthetic (LA) infiltration, thoracic epidural block, and multi-modal analgesia are just a few of the techniques that have been used to treat pain after laparoscopic cholecystectomy.<sup>[5,6]</sup> By placing LA in the neurofascial plane that is between the internal oblique and transversus abdominis muscles, transversus abdominis plane (TAP) block blocks abdominal neural afferents.<sup>[7]</sup> With the increasing use of ultrasound guidance for more precise TAP localization, the TAP block is now recognised as a crucial procedure for minimising post-operative pain after abdominal surgery.<sup>[8]</sup> In this study we compared ultrasound-guided transversus abdominis plane block with bupivacaine and ropivacaine as adjuncts for postoperative analgesia in laparoscopic cholecystectomies.

## Subjects and Methods

In this observational, comparative study seventy-six patients

scheduled to undergo 4-port laparoscopic cholecystectomy of either gender was enrolled. All patients belonged to American Society of Anesthesiologists Physical Status I/II patients aged 18–65 years. The selected patients gave their written consent to participate in the study.

Demographic data was recorded in case history sheet. Patients were randomly divided into 2 groups of 38 each based on convenience sampling. Patients in group I underwent ultrasound-guided TAP block with 0.25% bupivacaine (plain) and patients in group II underwent ultrasound-guided TAP block with 0.375% ropivacaine (plain). The consumption of rescue analgesics and post-operative pain were evaluated in all patients at 10 minutes, 30 minutes, an hour, four hours, eight hours, twelve hours, and twenty-four hours. Thusly collected data were analysed statistically. P value < 0.05 was considered significant.

## Results

**Table 1: Distribution of patients**

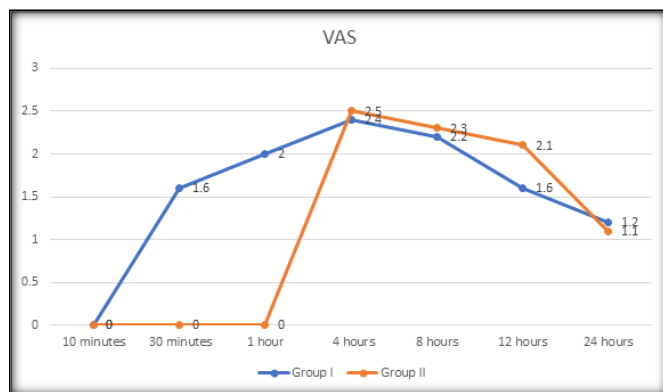
| Groups | Group I           | Group II           |
|--------|-------------------|--------------------|
| Method | 0.25% bupivacaine | 0.375% ropivacaine |
| Male   | 20                | 17                 |
| Female | 18                | 21                 |

Group I had 20 males and 18 females and group II had 17 males and 21 females [Table 1].

**Table 2: Comparison of parameters in both groups**

| Parameters                 | Group I | Group II | P value |
|----------------------------|---------|----------|---------|
| Weight (Kg)                | 64.2    | 63.8     | 0.82    |
| Height (cm)                | 158.4   | 158.3    | 0.90    |
| Duration of surgery (mins) | 71.4    | 74.2     | 0.92    |

The mean weight in group I was 64.2 kgs and in group II was 63.8 Kgs. The mean height was 158.4 cms in group I and 158.3 cms in group II. The mean duration of surgery was 71.4 minutes in group I and 74.2 minutes in group II. The difference was non-significant (P > 0.05) [Table 2].



**Graph 1: Assessment of post-operative pain scores**

The mean pain score at 10 minutes was 0.0 in both groups. At 30 minutes, it was 1.6 in group I and 0.0 in group II. At 1 hour was 2.0 in group I and 0.0 in group II. At 4 hours was 2.4 in group I and 2.5 in group II. At 8 hours was 2.2 in group I and 2.3 in group II. At 12 hours was 1.6 in group I and 2.1 in group II. At 24 hours was 1.2 in group I and 1.1 in group II. The

difference was significant (P < 0.05) [Graph 1].

## Discussion

A minimally invasive surgical operation called laparoscopic cholecystectomy is done to remove the gallbladder, which is situated in the upper right side of the belly. Typically, gallstones and other problems affecting the gallbladder are treated using this treatment. A laparoscopic cholecystectomy involves the surgeon making minute incisions in the abdomen and inserting a laparoscope, a tiny camera. The camera enables the surgeon to remove the gallbladder through the incisions while viewing the interior of the belly on a monitor.<sup>[9]</sup>

Both the local anaesthetic drugs bupivacaine and ropivacaine can be given as supplements for postoperative analgesia during laparoscopic cholecystectomies. Epidural, intrathecal, and wound infiltration are a few of the delivery methods for local anaesthetics.<sup>[10]</sup> Bupivacaine and ropivacaine, when used as wound infiltration, can effectively reduce pain following laparoscopic cholecystectomy by preventing the brain from receiving pain signals from the surgical site.<sup>[11,12]</sup> Bupivacaine and ropivacaine have been used as adjuncts for postoperative analgesia in laparoscopic cholecystectomies, and studies have indicated that doing so can lessen the demand for opioids and other painkillers, as well as postoperative pain scores and patient satisfaction with pain management.<sup>[13]</sup> Local anaesthetic toxicity, allergic responses, and nerve injury are only a few possible negative effects of using local anaesthetics for postoperative analgesia.<sup>[14]</sup> Therefore, a trained healthcare professional should carefully examine and oversee the use of bupivacaine and ropivacaine as adjuncts for postoperative analgesia during laparoscopic cholecystectomies.<sup>[15,16]</sup> In this study we compared ultrasound-guided transversus abdominis plane block with bupivacaine and ropivacaine as adjuncts for postoperative analgesia in laparoscopic cholecystectomies. Our study showed that group I had 20 males and 18 females and group II had 17 males and 21 females. McDermott et al.<sup>[17]</sup> in their study, 36 patients underwent a bilateral TAP block following a conventional anatomic landmark-based procedure were investigated. The position of the needle tip was checked using ultrasonography after the anesthesiologist had inserted the needle. Additionally, in 58% of the instances, the needle tip was found intramuscularly or subcutaneously. According to the authors, only 25% of the injections were in the proper intermuscular plane.

We found that the mean weight in group I was 64.2 kgs and in group II was 63.8 Kgs. The mean height was 158.4 cms in group I and 158.3 cms in group II. The mean duration of surgery was 71.4 minutes in group I and 74.2 minutes in group II. When 0.375% ropivacaine was used for TAP block in Carney et al.<sup>[18]</sup> clinical study of non-laparoscopic gynaecological surgeries, the reported pain scores were lower when compared for the patients who did not receive TAP block; higher VAS scores were observed when 0.75% of ropivacaine was used in TAP block, this was ascribed to a distinct pain profile in the extensive "open" surgical wound. The mean pain score at 10 minutes was 0.0 in both groups. At 30 minutes, it was 1.6 in group I and 0.0 in group II. At 1 hour was 2.0 in group I and 0.0 in group II. At 4 hours was 2.4 in group I and 2.5 in group II. At 8 hours was 2.2 in group I and

2.3 in group II. At 12 hours was 1.6 in group I and 2.1 in group II. At 24 hours was 1.2 in group I and 1.1 in group II. Sinha et al.<sup>[19]</sup> did comparison of the effectiveness of bupivacaine and ropivacaine for post-operative analgesia utilising ultrasound-guided TAP block in 60 subjects undergoing elective laparoscopic cholecystectomy who received either an ultrasound-guided TAP block with either 0.25% bupivacaine (Group I, n = 30) or 0.375% ropivacaine (Group II, n = 30). At 10 min, 30 min, 1 h, 4 h, 8 h, 12 h, and 24 h, all patients had their post-operative pain and use of rescue analgesics evaluated. When compared to patients who received the block with bupivacaine (Group I) at 10 min, 30 min, and 1 h, patients receiving the ultrasound-guided TAP block with ropivacaine (Group II) had noticeably reduced pain levels. However, both medications had the same effects.

## Conclusion

In patients undergoing laparoscopic cholecystectomy, ultrasound-guided deposition of ropivacaine 0.375% in the TAP offered greater analgesia in the early post-operative period compared to bupivacaine 0.25%.

## References

1. El-Dawlatly AA, Turkistani A, Kettner SC, Machata AM, Delvi MB, Thallaj A, et al. Ultrasound-guided transversus abdominis plane block: Description of a new technique and comparison with conventional systemic analgesia during laparoscopic cholecystectomy. *Br J Anaesth*. 2009;102:763–7.
2. Mraovic B, Jurisic T, Kogler-Majeric V, Sustic A. Intraperitoneal bupivacaine for analgesia after laparoscopic cholecystectomy. *Acta Anaesthesiol Scand*. 1997;41:193–6.
3. Fujii Y, Toyooka H, Tanaka H. Efficacy of thoracic epidural analgesia following laparoscopic cholecystectomy. *Eur J Anaesthesiol*. 1998;15:342–4.
4. Hebbard P, Fujiwara Y, Shibata Y, Royse C. Ultrasound-guided transversus abdominis plane (TAP) block. *Anaesth Intensive Care*. 2007;35:616–7.
5. Costello JF, Moore AR, Wieczorek PM, Macarthur AJ, Balki M, Carvalho JC. The transversus abdominis plane block, when used as part of a multimodal regimen inclusive of intrathecal morphine, does not improve analgesia after caesarean delivery. *Reg Anesth Pain Med*. 2009;34:586–9.
6. Baaj JM, Alsatli RA, Majaj HA, Babay ZA, Thallaj AK. Efficacy of ultrasound-guided transversus abdominis plane (TAP) block for post-caesarean section delivery analgesia - A double-blind, placebo-controlled, randomized study. *Middle East J Anaesthesiol*. 2010;20:821–6.
7. Shin HJ, Kim ST, Yim KH, Lee HS, Sim JH, Shin YD. Pre-emptive analgesic efficacy of ultrasound-guided transversus abdominis plane block in patients undergoing gynecologic surgery via a transverse lower abdominal skin incision. *Korean J Anesthesiol*. 2011;61:413–8.
8. Patil SS, Pawar SC, Divekar V, Bakhshi RG. Transversus abdominis plane block for an emergency laparotomy in a high-risk, elderly patient. *Indian J Anaesth*. 2010;54:249–54.
9. McGlade DP, Kalpokas MV, Mooney PH, Buckland MR, Vallipuram SK, Hendrata MV, et al. Comparison of 0.5% ropivacaine and 0.5% bupivacaine in lumbar epidural anaesthesia for lower limb orthopaedic surgery. *Anaesth Intensive Care*. 1997;25:262–6.
10. McGlade DP, Kalpokas MV, Mooney PH, Chamley D, Mark AH, Torda TA. A comparison of 0.5% ropivacaine and 0.5% bupivacaine for axillary brachial plexus anaesthesia. *Anaesth Intensive Care*. 1998;26:515–20.
11. Michaloliakou C, Chung F, Sharma S. Preoperative multimodal analgesia facilitates recovery after ambulatory laparoscopic cholecystectomy. *Anesth Analg*. 1996;82:44–51.
12. Niraj G, Searle A, Mathews M, Misra V, Baban M, Kiani S, et al. Analgesic efficacy of ultrasound-guided transversus abdominis plane block in patients undergoing open appendectomy. *Br J Anaesth*. 2009;103:601–5.
13. McDonnell JG, Curley G, Carney J, Benton A, Costello J, Maharaj CH, et al. The analgesic efficacy of transversus abdominis plane block after cesarean delivery: A randomized controlled trial. *Anesth Analg*. 2008;106:186–91.
14. Ra YS, Kim CH, Lee GY, Han JI. The analgesic effect of the ultrasound-guided transverse abdominis plane block after laparoscopic cholecystectomy. *Korean J Anesthesiol*. 2010;58:362–8.
15. Baeriswyl M, Kirkham KR, Kern C, Albrecht E. The analgesic efficacy of ultrasound-guided transversus abdominis plane block in adult patients: A meta-analysis. *Anesth Analg*. 2015;121:1640–54.
16. Niraj G, Searle A, Mathews M, Misra V, Baban M, Kiani S, Wong M. Analgesic efficacy of ultrasound-guided transversus abdominis plane block in patients undergoing open appendectomy. *Br J Anaesth*. 2009;103:601–5.
17. McDermott G, Korba E, Mata U, Jaigirdar M, Narayanan N, Boylan J, Conlon N. Should we stop doing blind transversus abdominis plane blocks? *Br J Anaesth*. 2012;108:499–502.
18. Carney J, McDonnell JG, Ochana A, Bhinder R, Laffey JG. The transversus abdominis plane block provides effective postoperative analgesia in patients undergoing total abdominal hysterectomy. *Anesth Analg*. 2008;107:2056–60.
19. Sinha S, Palta S, Saroa R, Prasad A. Comparison of ultrasound-guided transversus abdominis plane block with bupivacaine and ropivacaine as adjuncts for postoperative analgesia in laparoscopic cholecystectomies. *Indian journal of anaesthesia*. 2016 Apr;60(4):264.

**Copyright:** © the author(s), publisher. Academia Anesthesiologica Internationalis an Official Publication of “Society for Health Care & Research Development”. It is an open-access article distributed under the terms of the Creative Commons Attribution Non-Commercial License, which permits unrestricted non-commercial use, distribution, and reproduction in any medium, provided the original work is properly cited.

**How to cite this article:** Vaibhav V. Comparison of ultrasound-guided transversus abdominis plane block with bupivacaine and ropivacaine as adjuncts for postoperative analgesia in laparoscopic cholecystectomies. *Acad. Anesthesiol. Int*. 2019;4(2):369-371.

DOI: [dx.doi.org/10.21276/aaan.2019.4.2.84](https://doi.org/10.21276/aaan.2019.4.2.84)

**Source of Support:** Nil, **Conflict of Interest:** None declared.